

# MRI with MR Fistulogram for Perianal Fistula: A Successful Combination

Anil Kumar Bhaya, M.D.; Nanda Kumar, BSc (Radiography)

Department of Radiology and Imaging, Apollo Hospitals, Dhaka, Bangladesh

## Introduction

Perianal fistula commonly occurs in an otherwise healthy patient, typically, middle-aged men. Most experts believe that it occurs as result of anal gland obstruction, secondary abscess formation and subsequent external decompression through one of several fairly predictable routes. The internal origin of the fistula usually begins from the middle of the anal canal at the dentate line.

Fistulae may be classified [1] surgically as:

1. Intersphincteric (70%)
2. Transsphincteric (25%)
3. Suprasphincteric (5%)
4. Extrasphincteric or Supralelevator (< 1%)

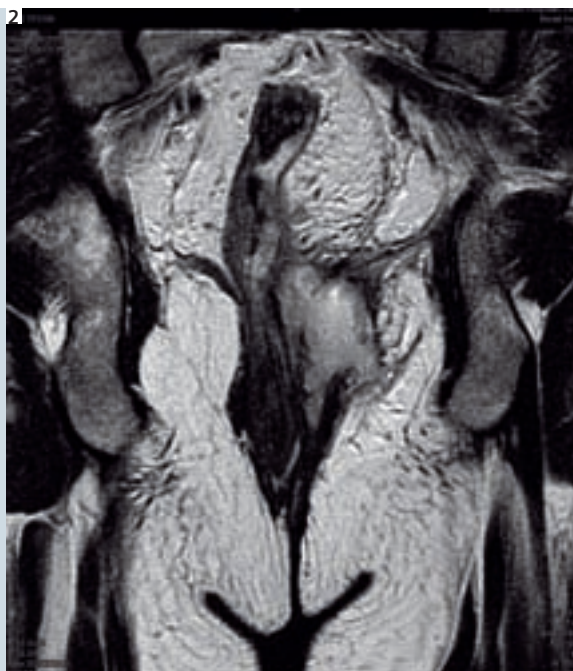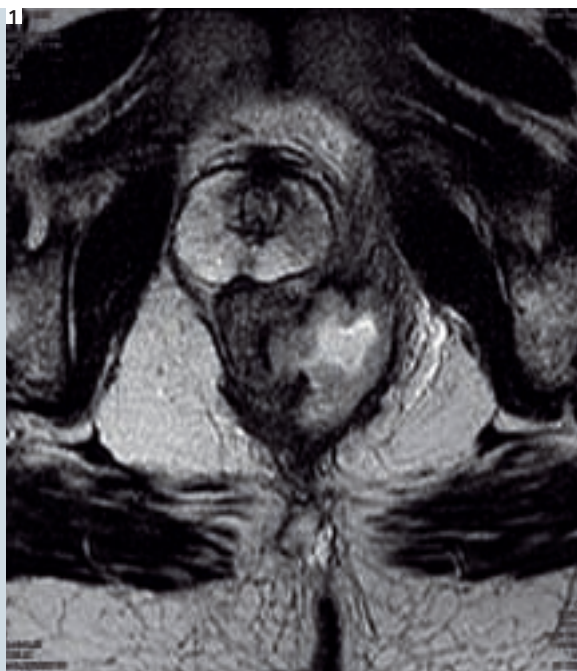
## Is Imaging Required?

In the early stages of perianal inflammation, the localized perianal abscess can be successfully drained without guidance. Perianal fistula occurs in the chronic phase of perianal abscess. If a surgeon can define the fistulous track from the

external to the internal openings with a probe, the fistula can be cured by deroofting it internally (fistulotomy).

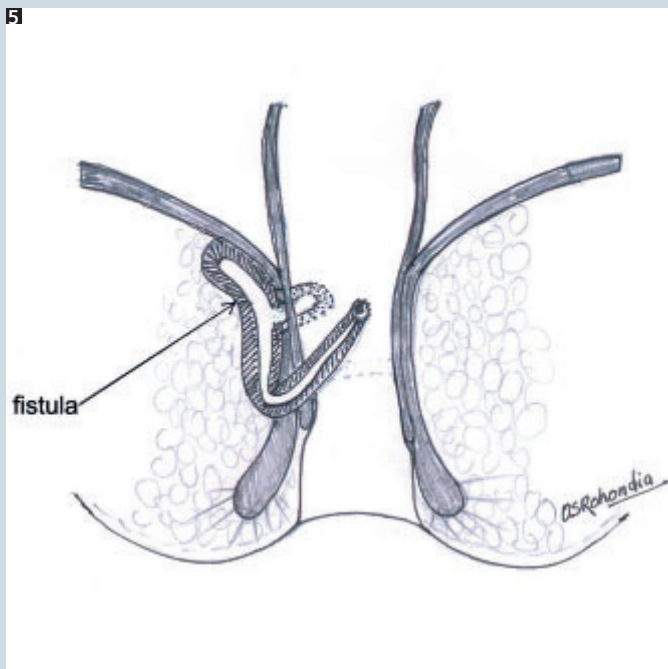
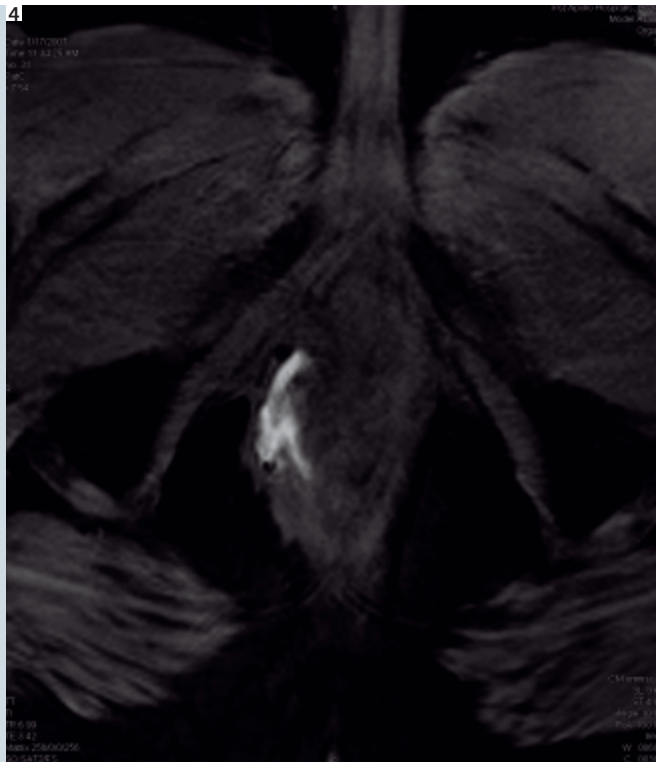
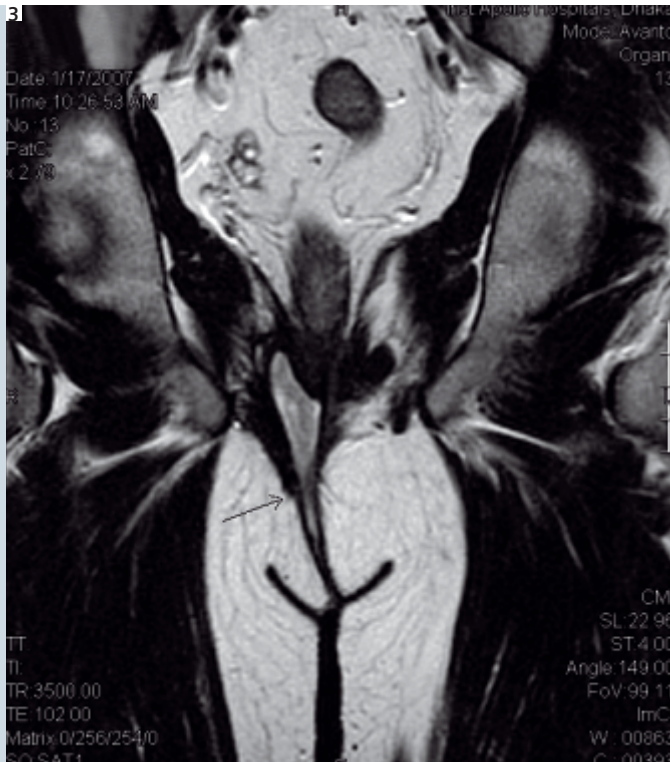
However, 5–15% of fistulas have a complicated course and require a road map before the proper surgical approach can be devised (Figs. 1, 2).

The goals of imaging include defining the presence and cause of any secondary tracks and to gauge the extent of sphincteric involvement by the fistula to best plan surgery and prevent relapse [2] (Figs. 3, 4, 5).



**1** High-resolution axial T2-weighted TSE image shows a large abscess with trans-sphincteric extension.

**2** Coronal T2-weighted TSE image in the same patient as Fig. 6 shows grade 5 complex fistula. The patient had no external opening and had a healed scar from prior perianal abscess drainage. The MRI information helped to decide on the appropriate therapy

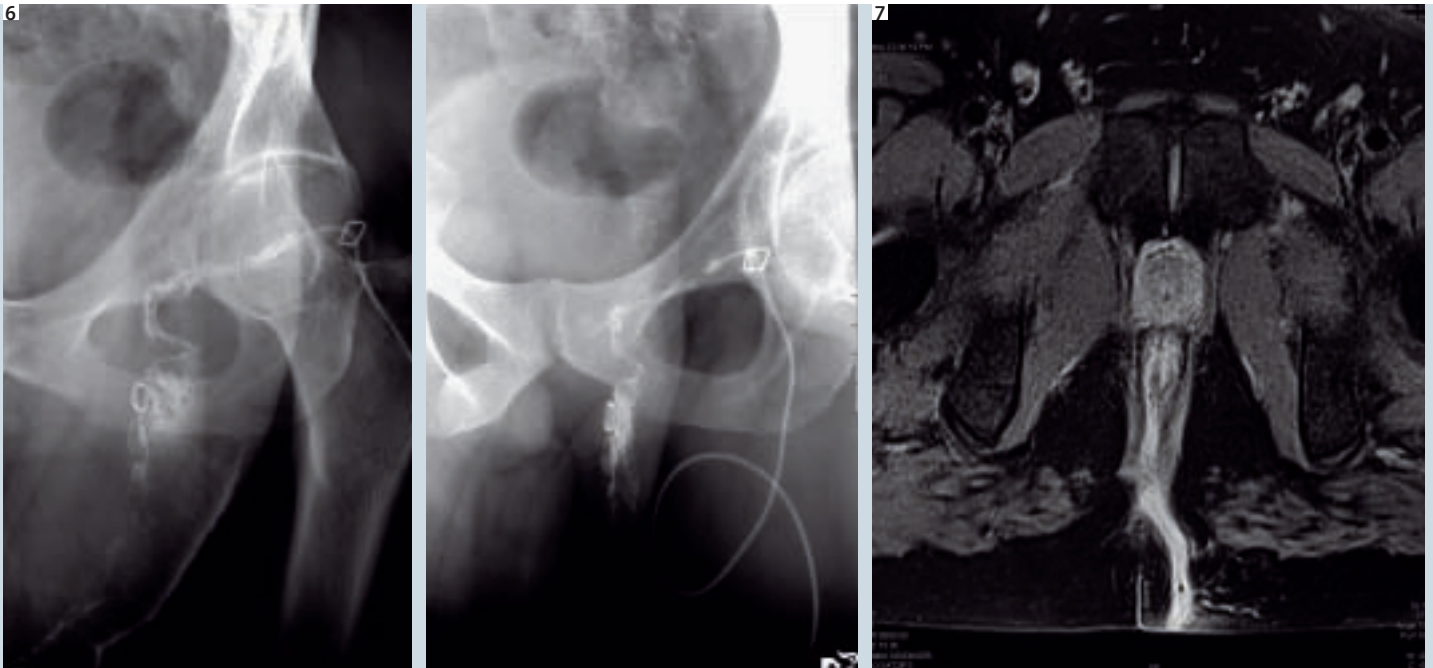


**3** High-resolution coronal T2-weighted TSE image in this patient with recurrent fistula operated 5 times earlier reveals presumably simple intersphincteric fluid intensity well defined fistula.

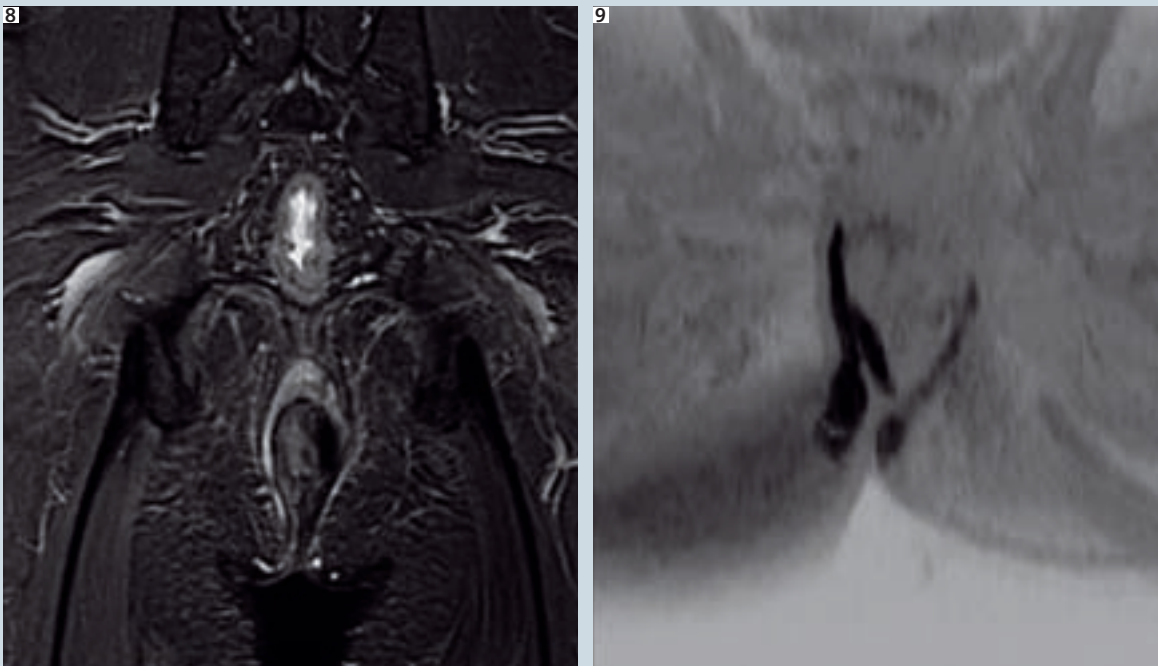
**4** MR Fistulogram after injection of dilute gadolinium using 3D VIBE sequence reveals medial transsphincteric ramification of the fistula.

**5** The findings were surgically confirmed and this image is the surgeon's perspective of the complex fistulous tract in the lithotomy position.

*Courtesy of Dr. O.P. Rohandia, Apollo Hospitals, Dhaka, Bangladesh.*



- 6 X-Ray Fistulogram in a male patient with recent history of perianal abscess drainage reveals an irregular fistulous tract. However, the exact anatomical relationships are difficult to ascertain.
- 7 Delayed protondensity-weighted axial MR image after MR Fistulography shows well delineated tract with transphincteric extension. The internal opening was not appreciated by examination under anesthesia and confirmed by injection of Gentian Violet at surgery. Due to the information delivered by MR Fistulography the surgeon treated this successfully by excision and seton.



- 8 Coronal T1-weighted TIRM sequence shows intersphincteric tract. Inverted U-shape.
- 9 MR Fistulogram (inverse image) confirms horseshoe fistula and also delineated secondary tract.



## MR Imaging Techniques

Although direct sinogram, CT scan and endoanal ultrasound have been used to assess the fistula, all of those techniques have had their limitations. For example, although the direct sinogram may delineate the track, it can be very difficult to correlate the track route with the local anatomic musculature and spaces necessary for pre-operative planning (Figs. 6, 7).

Endosonography has also been reported to be no more accurate than examination under anesthesia. MR imaging has become the method of choice due to its orthogonal display of the perineum and lower pelvis along with its superior contrast resolution, allowing faithful reproduction of the anatomy and pathology of the tracks. Compared to the body coil, the quadrature phased array and the Body Matrix coils afford better contrast and spatial resolution both with 2D and 3D sequences. However, the results of fistula imaging with endoanal coil have been disappointing. Investigators in a large study in which endoanal MRI was compared with body coil MRI found a surgical concordance rate of 68% for endoanal MRI as compared to 96% for body coil MRI [3]. In addition to conventional and turbo spin echo sequences, fat suppressed dynamic gadolinium enhanced imaging has been performed and found useful especially with digital subtraction [4]. MR fistulography with instillation of saline can facilitate the detection of fistula tracks, but the technique is cumbersome and depends on the existence of an external opening [5].

## Our Experience

All our studies were performed on a 1.5T unit (MAGNETOM Avanto, Siemens Medical Solutions, Erlangen, Germany) with 32x8 channel Tim technology, using Body- and Spine Matrix coil combination. No special bowel preparation was used although the patients were advised to keep their perianal regions clean for cannulation.

**Table 1: Routine protocol**

Sequence	FoV	SL./gap	Matrix	Average	Sat
T1 TIRM Cor (Scout)	350	5/10%	320/80	1	Superior
T2 TSE Cor	210	4/10%	256/100	1	Superior
T1 TSE Cor	210	4/10%	256/100	1	Superior
T1 TSE Tra	210	4/10%	320/80	2	Parallel
T1 TIRM Tra	210	4/10%	320/80	1	Parallel
T2 TSE Sag	210	3/10%	320/80	2	Superior
T1 VIBE Fs Tra	210	2.5/20%	256/100	1	Parallel
T1 VIBE Fs Cor	210	2.5/20%	256/100	1	Superior
T1 VIBE Fs Tra (Post-Con)	210	2.5/20%	256/100	1	Parallel
T1 VIBE Fs Cor (Post-Con)	210	2.5/20%	256/100	1	Superior

Following a routine protocol in supine position (see Table 1) the patient is placed in prone position and the site of fistula opening is cleaned well with alcohol and povidone-iodine (Win - Medicare) solution. For cannulation we use an infant feeding tube or butterfly cannula without the needle and with the tube cut in bevelled fashion to facilitate easy and non-traumatic entry. If there is resistance at the opening, we usually use mosquito forceps to widen it. The tip of the cannula is dipped in xylocaine gel for lubrication and local anesthetic effect. Prepared solution (1 ml Gadolinium, Omniscan, Amersham Health, Cork, Ireland) mixed in 20 ml of sterile normal saline) is gradually injected through the cannula (all air in the syringe is evacuated prior to the injection). As soon as reflow occurs or there is flow through secondary track and opening, we close the opening with sterile gauze and clean any contrast refluxed on the skin surface. After this the Body Matrix coil is placed on the pelvis covering the region of interest and isocentred within the magnet (Figs. 8, 9).

## Conclusion

Our experience shows that phased array Body Matrix coils afford sufficient image contrast and resolution for accurate as-

essment of perianal fistulas. We also believe that a combination of the above with MR Fistulography enhances the diagnostic yield of the examination and also reduces the false positive diagnosis of fistulous tracks by distinguishing from the healed partially fibrotic but T2 hyperintense tracks. We also found that this technique may better define the internal opening for surgical planning.

## References

- 1 www.surgical-tutor.org.uk.
- 2 Beets-Tan RGH, Beets GL, Geerard Vanderhoop, AG, Kessels AGH, Vlieghe RFA, Baeten CGMI, Van Engelsehoven JMA. Preoperative MR imaging of anal fistulas: does it really help the surgeon? Radiology 2001; 218: 75–84.
- 3 Halligan S, Bartram CI. MR imaging of fistula in ano: are endorectal coils the gold standard? AJR 1998; 171: 407–412.
- 4 Schaefer O, Lohrmann C, Langer M. Digital subtraction MR fistulography: now diagnostic tool for the detection of fistula in ano. AJR 2003; 181: 1611–1613.
- 5 Komatsu S et al. Circ J 2005; 69(1): 72–77.
- 6 Myhr GE, Myrvold HE, Nilseth G, Thoresen JE, Rinck PA. Perianal fistulas: use of MR imaging for diagnosis. Radiology 1994; 191: 545–549.