NOTE

This protocol was provided by **Prof. Michael Recht, NYU School of Medicine**, Dep. of Radiology, NY, USA, on behalf of the MSK Advisory Board

2D SCAN

contrast:	PD	PD	T2	PD	T1	T2	PD
sequence type:	TSE	TSE	GRE	TSE	TSE	MEDIC	TSE
slice orientation:	transversal	transversal	coronal	coronal	coronal	sagittal	sagittal
acquisition time [min:s]:	02:53	03:45	03:30	03:43	01:44	03:44	04:15
resolution [mm³]:	0.2x0.2x2.0	0.3x0.3x2.2	0.3x0.3x1.5	0.3x0.3x2.2	0.3x0.3x3.0	0.3x0.3x1.5	0.3x0.3x2.2
matrix [Px2]:	384x384	320x320	320x320	320x320	256x256	320x240	320x320
bandwidth (Hz/Px):	260	260	180	260	369	182	260
turbo factor:	9	9		9	4		9
TR [ms]:	3000	4560	500	4520	500	740	4520
TE [ms]:	40	50	10	50	11	22	50
TI [ms]:							
field of view [mm]:	80	80	80	80	80	80	80

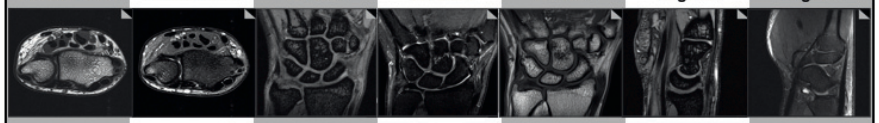

3D SCAN

NOT YET AVAILABLE

	total scan time [min:s]							
2D scan	23:34	pd_tse_tra	pd_tse_fs_tra	t2_fi2d_cor	pd_tse_fs_cor	t1_tse_cor	t2_me2d_sag	pd_tse_fs_sag
clinical requests	12:42		pd_tse_fs_tra	t2_fi2d_cor	pd_tse_fs_cor	t1_tse_cor		
	12:42		pd_tse_fs_tra	t2_fi2d_cor	pd_tse_fs_cor	t1_tse_cor		
general	12:42		pd_tse_fs_tra	t2_fi2d_cor	pd_tse_fs_cor	t1_tse_cor		
injury intrinsic ligaments	12:42		pd_tse_fs_tra	t2_fi2d_cor	pd_tse_fs_cor	t1_tse_cor		
osseous	12:42		pd_tse_fs_tra	t2_fi2d_cor	pd_tse_fs_cor	t1_tse_cor		
tendons	12:42		pd_tse_fs_tra	t2_fi2d_cor	pd_tse_fs_cor	t1_tse_cor		
ECU instability								
carpal tunnel								
AVN								

MAGNETOM Verio

Wrist Protocol

www.siemens.com/magnetom-world

SIEMENS