

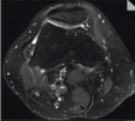
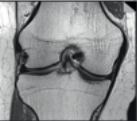

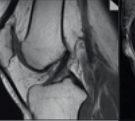
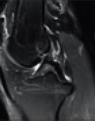
NOTE

This protocol was provided by
**Prof. Michael Recht, NYU
 School of Medicine**, Dep. of
 Radiology, NY, USA, on behalf of
 the MSK Advisory Board

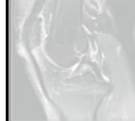

contrast:
 sequence type:
 slice orientation:

acquisition time [min:s]:
 resolution [mm³]:
 matrix [Px2]:
 bandwidth (Hz/Px):
 turbo factor:
 TR [ms]:
 TE [ms]:
 TI [ms]:
 field of view [mm]:

2D SCAN

PD TSE transversal	PD TSE coronal	PD TSE coronal	PD TSE sagittal	T2 TSE sagittal
				
04:31	03:35	03:54	03:35	03:51
0.5x0.4x3.0	0.3x0.3x2.5	0.4x0.3x3.0	0.4x0.3x2.5	0.5x0.4x3.0
384x288	448x403	448x381	512x384	384x288
181	180	180	257	181
15	4	5	5	15
5380	2630	3750	3000	5590
50	38	35	20	60
140	140	140	140	140

3D SCAN

	
N O T Y E T A V A I L A B L E	

clinical requests

general

injury ligaments
 osseous
 minisci
 quadriceps tendon

degenerative pain cartilage

total scan time [min:s]

2D scan → 19:26

15:51

15:51

15:32

15:51

15:32

pd_fs_tra	pd_cor	pd_fs_cor	pd_sag	t2_fs_sag
pd_fs_tra		pd_fs_cor	pd_sag	t2_fs_sag
pd_fs_tra		pd_fs_cor	pd_sag	t2_fs_sag
pd_fs_tra	pd_cor		pd_sag	t2_fs_sag
pd_fs_tra		pd_fs_cor	pd_sag	t2_fs_sag
pd_fs_tra	pd_cor		pd_sag	t2_fs_sag

MAGNETOM Verio Knee Protocol

www.siemens.com/magnetom-world

SIEMENS