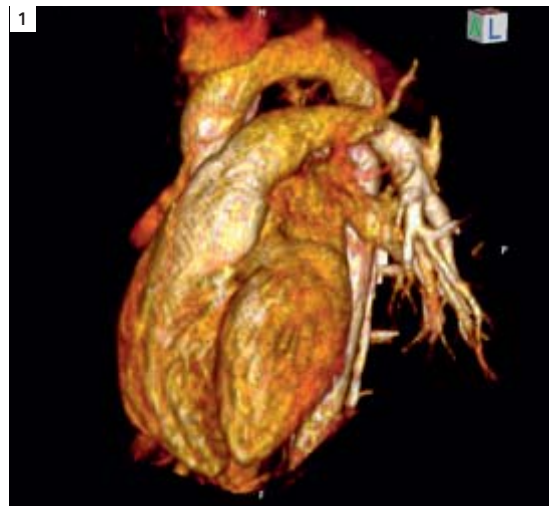


# MR Imaging of Congenital Heart Disease

Vivek Muthurangu, M.D.; Michael Hansen, M.D.; Andrew M. Taylor, M.D.

UCL Institute of Child Health & Great Ormond Street Hospital for Children, London, UK



**1** 3D volume-rendered image of the normal heart and great vessels, recreated from a 3D navigator and ECG-gated TrueFISP dataset viewed from left anterior oblique.

Conventionally, more detailed anatomical and functional assessment has been acquired with x-ray cardiac catheterization. Cardiac catheterization gives good definition of vascular anatomy and enables assessment of haemodynamics (vascular stenosis, quantification of cardiac shunting, and pulmonary vascular resistance), but is associated with risks due to the invasive nature of the procedure and the exposure to ionizing radiation. In addition, x-ray fluoroscopy provides a projection image and has only limited three-dimensional (3D) capabilities.

More recently, cross-sectional cardiovascular imaging (MR and CT) has become a very important tool for diagnosis and follow-up of children and adults with CHD. Not only does cross-sectional imaging allow accurate description of cardiac and vascular anatomy in relation to the other structures of the chest, but MR imaging, in particular, can provide accurate quantification of cardiac function and vascular flow.

## MR imaging

The majority of cardiovascular MR images are acquired using cardiac (ECG) gating during a breath-hold, to reduce the artifacts associated with cardiac and respiratory motion. For a complex case, MR imaging is performed over approximately 1 hour, though this can be considerably reduced if a focused question is addressed.

Imaging sequences can be broadly divided into:

- **'Black-blood'** spin-echo images, where signal from blood is nulled and thus not seen – for accurate anatomical imaging
- **'White-blood'** gradient echo or steady-state free precession (TrueFISP) images, where a positive signal from blood is returned – for anatomi-

CMR imaging allows accurate description of cardiac and vascular anatomy and provides accurate quantification of cardiac function and vascular flow.

## Introduction

Congenital heart disease (CHD) has an incidence of 6–8 per 1000 at birth with prevalence increasing due to improvements in diagnosis and treatment. Management of patients with CHD relies heavily on imaging. Echocardiography is the first line investigation. However, echocardiography provides poor images of the peripheral vasculature, is user dependant and can be limited by difficult acoustic windows. These problems are exacerbated in patients with CHD as they often have restricted acoustic window access due to multiple previous operations and furthermore the structures that must be visualized in CHD are difficult to assess at echocardiography (i.e. right ventricle and pulmonary arteries).

cal, cine imaging, and quantification of ventricular volumes, mass and function

- **Phase-contrast imaging**, where velocity information is encoded – for quantification of vascular flow, and
- **Contrast-enhanced MR angiography**, where non-ECG gated 3D data is acquired after Gadolinium contrast medium has been administered – for thoracic vasculature imaging.

Imaging should be performed in the presence of a cardiovascular MR expert in conjunction with an MR technician to ensure that the appropriate clinical questions are answered. Currently, our own practice is to perform all cardiovascular MR in children less than 8 years of age under general anesthesia, as this enables the safe acquisition of accurate data (reduced movement and respiratory artifact). With the development of even faster sequences, breath holding may become less of a necessity, and MR data may then be acquired more easily during sedation.

There are many CHD's that lend themselves to cardiovascular MR. However; it is beyond the scope of this brief review to cover all these conditions. We will therefore discuss some of the most common lesions referred for cardiovascular MR: Aortic coarctation, tetralogy of Fallot, transposition of the great arteries (TGA), and the assessment of the functional single ventricle.

## MR imaging of common conditions

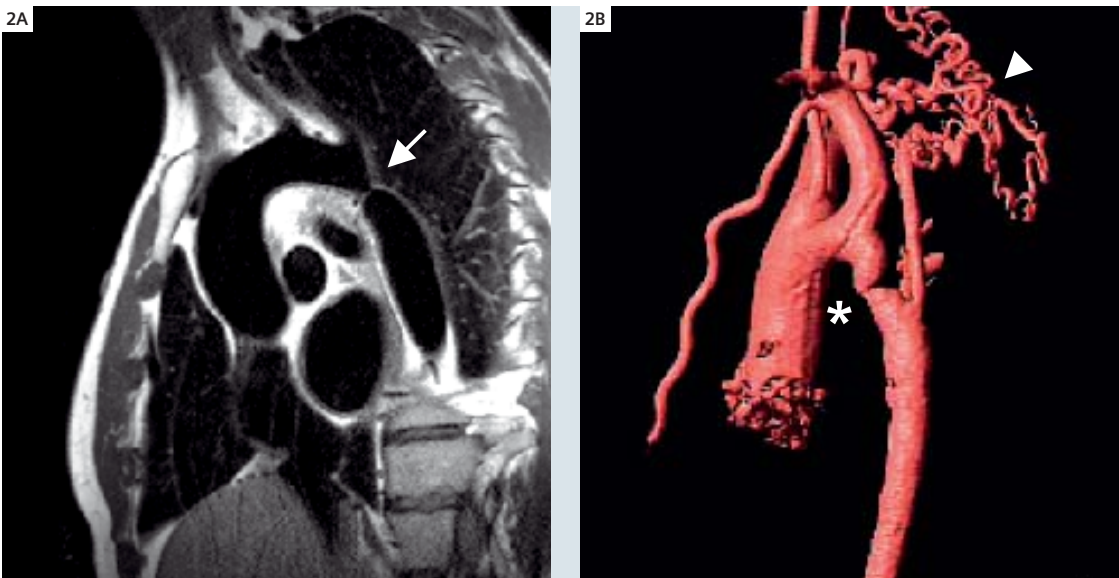
### Aortic coarctation

Coarctation occurs in 6–8% of live CHD births with a predominance of males. There is an area of narrowing in the thoracic aorta in the region of insertion of the arterial duct (aortic isthmus, Fig. 2). There is a risk of hypertension, atherosclerosis and end organ damage, even in patients who have undergone surgical repair. Treatment in infancy with surgical excision of the narrowing is usually performed, though in older subjects balloon angioplasty may be undertaken, and following re-coarctation, aortic stenting can be used. In the neonatal population, echocardiography is used in the initial diagnosis. Echocardiography can also be used in follow up, but as children grow this becomes more difficult and imaging with MR is required in later life to establish if there is re-coarctation after repair (3–35% of patients), aneurysmal dilatation, or left ventricular hypertrophy secondary to hypertension. MR imaging is preferred if there are no contraindications, as this reduces population radiation.

Imaging is crucial for management decisions to establish the location and degree of stenosis, length of coarctation segment, associated aortic arch involvement (such as tubular hypoplasia), the collateral pathways (internal mammary and posterior mediastinal arteries), relationship to

The most common CHD referred for cardiovascular MR are aortic coarctation, tetralogy of Fallot, TGA, and the assessment of the functional single ventricle.

Multiple follow-up imaging exams are needed in CHD patients. Increasing utilization of CMR helps reducing population radiation.



**2** Aortic coarctation. (2A) Oblique sagittal, 'black-blood' TSE image through a severe, discrete aortic coarctation (arrow). (2B) 3D, volume-rendered MRA image of another severe aortic coarctation (\*), with multiple collaterals (arrowhead).

aberrant subclavian artery, post-stenotic dilatation and left ventricular hypertrophy.

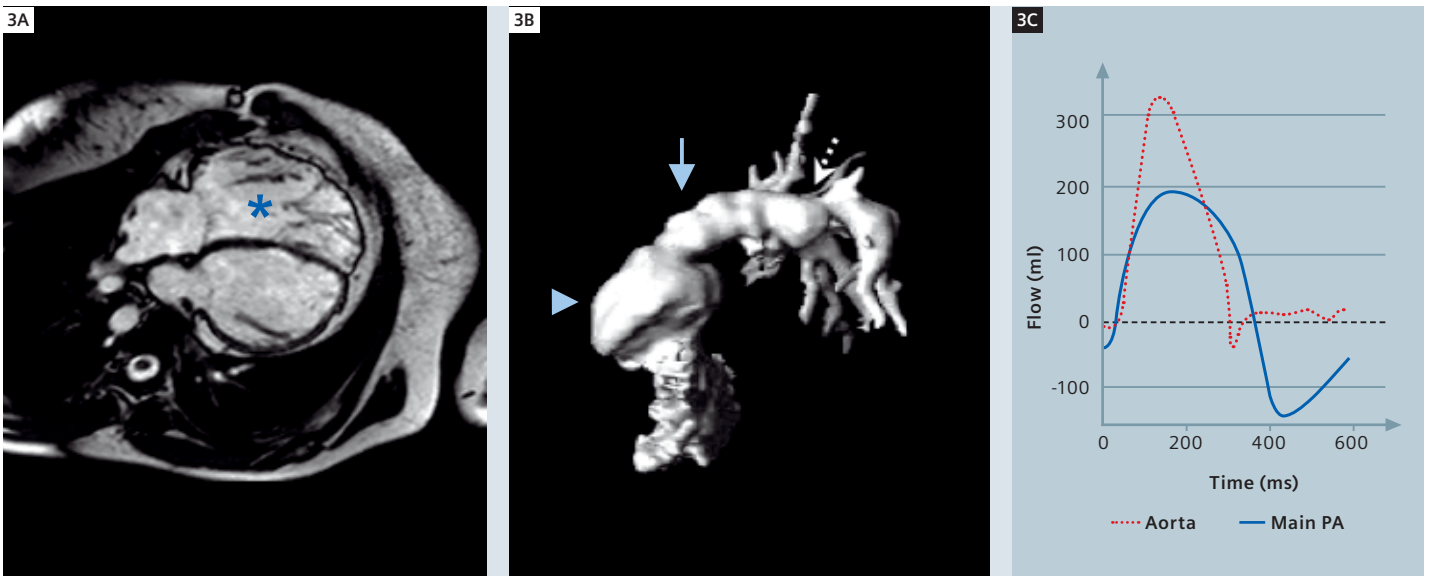
### Tetralogy of Fallot

Tetralogy of Fallot is the most common cyanotic congenital heart defect with an incidence of approximately 420 per million live births. It is caused by malalignment of the infundibular septum, which leads to right ventricular outflow (RVOT) obstruction, a sub-aortic ventricular septal defect (VSD) with aortic override, and right ventricular hypertrophy. Current management consists of early single stage reconstructive surgery, with closure of the VSD, and relief of the RVOT obstruction, with possible placement of a trans-annular patch. Staged reconstruction is still required if there is significant hypoplasia of the central pulmonary arteries, with placement of a modified Blalock and Tausig (BT) shunt – a systemic to pulmonary anastomosis, usually between the innominate artery and the right pulmonary artery. This shunt is then taken down during subsequent definitive repair. Pre-operatively, cross sectional imaging has a role in delineating pulmonary artery anatomy, which helps decide between a single stage or multi-stage repair. However, the main role of imaging patients with tetralogy of Fallot is in the assess-

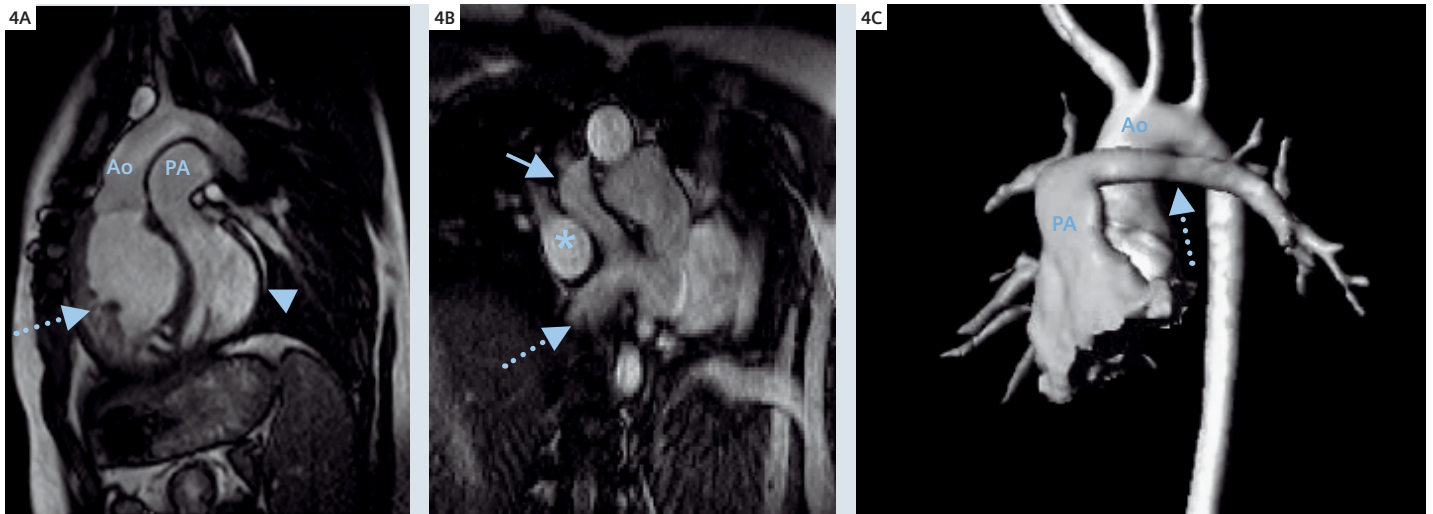
ment of post-operative complications (Figure 3). The most common late post-operative complication is pulmonary regurgitation secondary to trans-annular patch reconstruction of the RVOT/pulmonary annulus. This is often associated with aneurysmal dilatation of the RVOT. Surgical or trans-catheter valve replacement is the current method of managing patients with severe pulmonary regurgitation. Accurate quantification of regurgitation and assessment of RVOT anatomy and right ventricular (RV) function are particularly important in deciding the type and timing of procedures.

Branch pulmonary stenosis may also be present in this patient group and are best imaged by MR angiography. These can contribute to RV dysfunction, and significant obstructions should be repaired at the same time as valve replacement. The final role of MR is in evaluating RV function. This is important for timing of invasive therapeutic measures and evaluating the effect of any invasive procedure. It has been shown that, using a combination of MR ventricular volumetry and tricuspid and pulmonary flow maps, precise information about global and diastolic ventricular function can be assessed in patients with repaired tetralogy of Fallot.

Using a combination of CMR ventricular volumetry and tricuspid and pulmonary flow maps, global and diastolic RV function can be assessed precisely.



**3** Repaired tetralogy of Fallot. (3A) TrueFISP 4-chamber image showing RV dilation (\*). (3B) 3D, volume-rendered MRA image of the right ventricular outflow tract (RVOT) and proximal pulmonary arteries – lateral view. Note the large RVOT aneurysm is seen at the site of previous transannular patch repair (arrowhead), the pulmonary trunk (arrow), and the narrowed proximal left pulmonary artery (dashed arrow). (3C) Flow plotted against time for the aorta and pulmonary artery demonstrating pulmonary incompetence (regurgitant fraction = 33%) from phase contrast velocity maps.



**4 Transposition of the great arteries.** (4A) TrueFISP sagittal image; the aorta (Ao) arises anteriorly from the hypertrophied right ventricle (arrow); the posterior pulmonary artery (PA) arises from the left ventricle (arrowhead). (4B) TrueFISP images of intra atrial baffles in a patient who has undergone the atrial switch Senning operation –pulmonary venous blood into the right atrium (\*), systemic venous blood into the left atrium, superior pathway (arrow), inferior pathway (dashed arrow). (4C) 3D volume-rendered MRA of the aorta (Ao) after the arterial switch operation. Anterior pulmonary arteries: pulmonary trunk (PA), left pulmonary artery (dashed arrow).

## Transposition of the great arteries

Transposition of the great arteries (TGA) is the second most common cyanotic congenital heart disease in the first year of life with an incidence of 315 per million live births. It is defined as ventriculo-arterial discordance with an anterior aorta arising from the anterior RV, and the pulmonary artery arising from the posterior left ventricle (LV) (Fig. 4). Surgical therapy for this condition was revolutionized during the 1960's with the introduction of the Senning and Mustard procedure, in which blood is diverted from the right atrium to the left ventricle, and from the left atrium to the right ventricle. Both procedures produce a physiologically normal, but an anatomically very abnormal circulation (systemic venous return to the left atrium to LV and then to pulmonary artery; pulmonary venous return to the right atrium to RV and then to aorta). In 1975, the first arterial switch operation was performed. In this operation, the aorta and main pulmonary artery are transected, switched and re-anastomosed to the correct ventricle. This results in both a physiological and anatomically normal circulation, and for this reason, the arterial switch operation has become the procedure of choice for TGA. The arterial switch operation is performed in the first few days of life, and currently trans-thoracic

echocardiography is the imaging modality of choice for pre-operative diagnosis and assessment. The role of cross-sectional imaging is mainly in diagnosis of post-operative complications, particularly those that develop, as the child grows older. The main complications of the arterial switch operation are RVOT or branch pulmonary artery obstruction. Due to the unusual position of the pulmonary arteries immediately behind the sternum, trans-thoracic echocardiography is poor at detecting these lesions. Cardiovascular MR is ideal for imaging the RVOT and branch pulmonary arteries in this group of patients. Contrast enhanced MR angiography can be used to visualize the relationship between the pulmonary arteries and the aorta, while spin-echo sequences are used to assess accurately the degree of stenosis. A less common complication of the arterial switch operation is coronary stenosis secondary to the re-implantation procedure. Although the majority of coronary complications cause early post-operative mortality, a sub-set of patients suffer from late coronary events. In this group, coronary catheter angiography probably represents the modality of choice for investigation. However, coronary MR angiography or MDCT angiography are useful non-invasive methods for investigating the coronary arteries, particularly the proximal segments.

CMR is ideal for the detection of the main complications of the arterial switch operation: RVOT or branch pulmonary artery obstruction.



Anatomy, morphology, function and flow: CMR allows a comprehensive assessment of congenital heart diseases.

Although intra-atrial repair has been superseded by the arterial switch operation there is a sizeable population who have undergone either a Senning or Mustard operation. The most common complications of intra-atrial repair are baffle obstruction or leak, arrhythmias, and RV dysfunction. A combination of contrast MR angiography, spin-echo and phase contrast MR techniques allows comprehensive assessment of intra-atrial baffles.

### The single ventricle

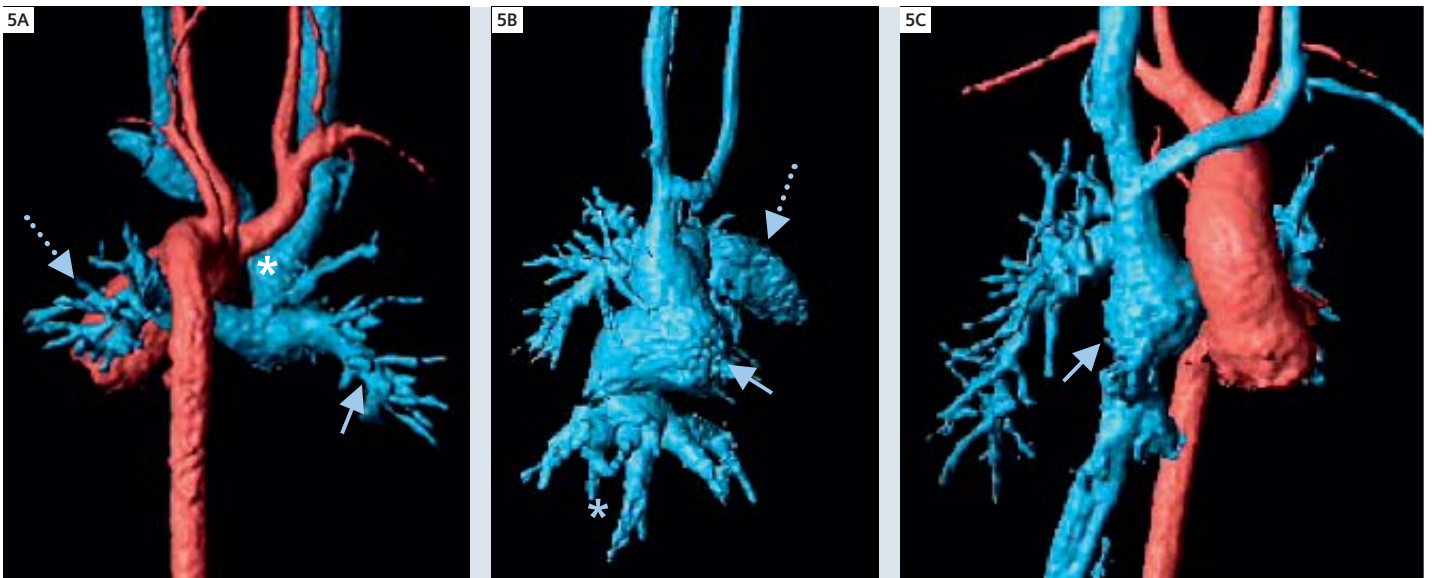
The single ventricle can be either an anatomical entity, for example in tricuspid atresia (single left ventricle) or hypoplastic left heart syndrome (single right ventricle), or a functional entity, where there are two ventricles connecting by a large VSD (Fig. 5). Even when there is anatomically a single ventricle, there is usually a vestigial remnant of the other ventricle. Depending on the size of the ventricles, and the great vessel anatomy, it may be possible to surgically 'septate' the ventricles to create a bi-ventricular circuit. If the ventricular sizes are not potentially equal, separation of the pulmonary and aortic circulations is required (the Fontan circulation), such that the single ventricle pumps blood into the systemic circulation, and systemic venous return is directed in to the pulmonary circulation.

### Bi-directional Glenn circulation

The first stage in the creation of a single ventricular circulation is the bi-directional Glenn operation (or hemi-Fontan operation). In this procedure, a side-to-side anastomosis is created between the superior caval vein (SVC) and pulmonary arteries, and a patch is inserted to divide the SVC from the right atrium. Any systemic to pulmonary artery shunts are also taken down at this time. MR can be used to assess branch pulmonary artery narrowing and pulmonary venous obstruction prior to completion of the Fontan circulation otherwise the circulation may fail.

### Fontan circulation

The Fontan circulation is completed by either anastomosis of the right atrium to the Glenn shunt (classical Fontan operation) or creation of a lateral or extra-cardiac tunnel between the inferior caval vein and the Glenn shunt (total caval pulmonary connection – TCPC). The latter procedure is now the preferred option; there remains however, a sizeable population with a standard Fontan circulation who require diagnostic assessment.



**5 Fontan circulation.** (5A) 3D volume-rendered MR angiogram of a bi-directional Glenn shunt (blue), posterior view – right pulmonary artery (arrow), left pulmonary artery (dashed arrow) superior caval vein (\*), and descending aorta (red). (5B) 3D volume-rendered MR angiogram of a classical Fontan circulation showing severe right atrial dilation (arrow) – right atrial appendage (dashed arrow) and IVC drainage (\*). (5C) 3D volume-rendered MR angiogram of a total caval pulmonary connection (TCPC) lateral tunnel Fontan circulation – lateral tunnel (arrow).

## Conclusion

Cardiovascular imaging is important for the diagnosis and follow-up of children and adults with CHD. In young patients, echocardiography is the first line imaging modality; however, when echocardiography cannot provide a complete diagnosis, cross-sectional imaging with MR is rapidly becoming the next line of investigation, with interventional catheter angiography reserved for problem solving, for the assessment of the coronary arteries, and for the assessment of pulmonary vascular resistance.

In older children and adults, where echocardiography is less easy (poor acoustic windows and multiple operations), cross-sectional imaging is essential. MR in particular is important in this setting, as

there is no radiation burden, and both anatomy and function can be assessed to enable optimal follow-up and timing of future interventions.

### Contact

Andrew M. Taylor, M.D., MRCP, FRCR  
 Reader in Cardiovascular Imaging  
 Director – Centre for Cardiovascular MR  
 Cardiothoracic Unit  
 UCL Institute of Child Health & Great Ormond Street  
 Hospital for Children  
 Great Ormond Street  
 London WC1N 3JH  
 United Kingdom  
 Tel: +44 (0) 207 404 9200 (ext. 5616)  
 Fax: +44 (0) 207 813 8263  
 E-mail: a.taylor@ich.ucl.ac.uk

The Advanced Cardiac Package includes the navigator and ECG gated 3D TrueFISP protocol for whole-heart imaging.

## MR imaging protocol for congenital heart disease

The protocol below is a general protocol for imaging of CHD. It should be altered to answer clinical questions depending on patient anatomy.

1. Scouts and reference (parallel imaging) scans
2. HASTE black-blood axial imaging
3. Navigator-echo gated TrueFISP 3D volume of whole heart and great vessels
4. 2D single-slice TrueFISP cine images
  - a. Vertical long axis
  - b. Four-chamber view
  - c. RVOT in two planes
  - d. LVOT in two planes
  - e. Both branch pulmonary arteries
5. 2D multi-slice TrueFISP cine images – entirety of both ventricles in short-axis
6. 2D single-slice black-blood TSE imaging
  - a. Branch pulmonary arteries
  - b. Aortic arch
  - c. Vascular stenoses
7. Phase-contrast velocity mapping
  - a. Main pulmonary artery through-plane
  - b. Ascending aorta through-plane
  - c. Vascular stenoses in-plane
8. 3D contrast-enhanced MR angiography of the thoracic great vessels

### Recommended reading

Paediatric Cardiology 2nd Edition. Eds: Anderson RH, Baker EJ, Macartney FJ, Rigby ML, Shinebourne EA, Tynan M. Churchill Livingstone, London, 2002. ISBN 0 443 07990 0

Hoffman JL, Kaplan S. The incidence of congenital heart disease. *J Am Coll Cardiol* 2002; 39:1890–1900

Anderson RH, Razavi R, Taylor AM. Cardiac anatomy revisited. *Journal of Anatomy* 2004; 205:159–77

Echocardiography in Pediatric Heart Disease. Snider AR, Serwer GA, Ritter SB. Mosby, 1997. ISBN 0 815 17851 4

Diagnosis and Management of Adult Congenital Heart Disease. Eds: Gatzoulis MA, Webb GA, Piers Daudeney P. Churchill Livingstone, London, 2003. ISBN 0 443 07103 9

Clinical Cardiac MRI. Eds: Bogaert J, Dymarkowski S, Taylor AM. Springer, Berlin, Heidelberg, New York, 2005. ISBN 3 540 40170 9

Coats L, Khambadkone S, Derrick G, et al. Physiological and clinical consequences of relief of right ventricular outflow tract obstruction late after repair of congenital heart defects. *Circulation* 2006; 113(17):2037–44

Schievano S, Migliavacca F, Coats L, et al. Planning of percutaneous pulmonary valve implantation based on rapid prototyping of the right ventricular outflow tract and pulmonary trunk from magnetic resonance imaging data. *Radiology* 2007; 242(2):490–7