

Case Report: Paraspinal Vascular Mass

Randolph Otto, M.D.

Seattle Children's Hospital, Department of Radiology, Seattle, WA, USA

Patient history

7-year-old female undergoing follow-up of a large paraspinal muscular hemangioma.

Sequence details

Images were acquired on our 1.5T MAGNETOM Avanto, using the Body Matrix coil.

MR Angiography (MRA) using 6 ml Magnevist administered IV.

TE 1.17 ms, TR 2.7 ms, FOV 261 x 380, matrix 220 x 320, PAT factor 2, partition time 3.61 sec, acquisition plane coronal

Imaging Findings

There is a right paraspinal vascular mass with lumbar arterial feeding vessels and draining veins to the intraspinal venous plexus and overlying cutaneous tissues. Prominent feeding lumbar arteries are again seen from T12 through L4. There is associated displacement of the right kidney, the inferior vena cava (IVC) and right main renal artery. Both the IVC and right main renal artery remain patent. Draining vessels are seen communicating with the intraspinal venous plexus.

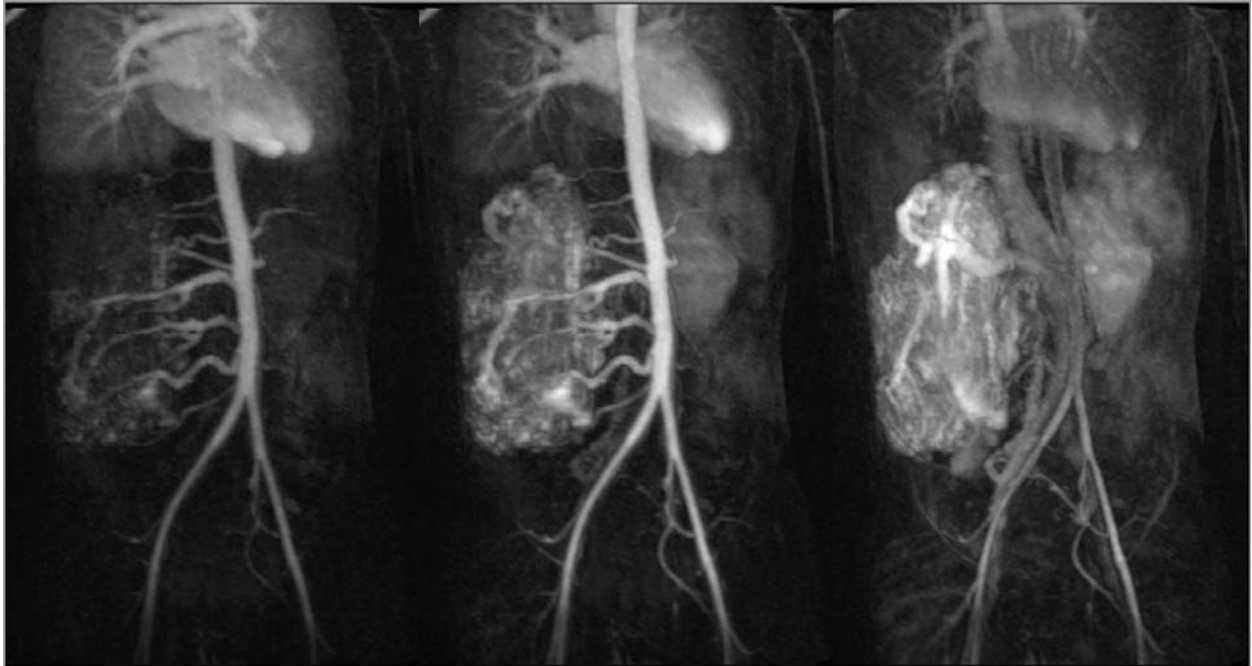


Figure 1: The images display the pattern of contrast enhancement.

Results and Discussion

The partial k-space acquisition techniques inherent in the *syngo* TWIST sequence allow for excellent temporal resolution of filling characteristics of large high flow vascular abnormalities in the abdomen.