

Interventional angiography of anterior communicating artery aneurysm Supported by syngo Neuro PBV IR*

Courtesy of James V. Byrne, M.D., and Mudassar Kamran, M.D.

Department of Neuroradiology at Oxford Radcliffe Hospitals, University of Oxford, UK

Patient history

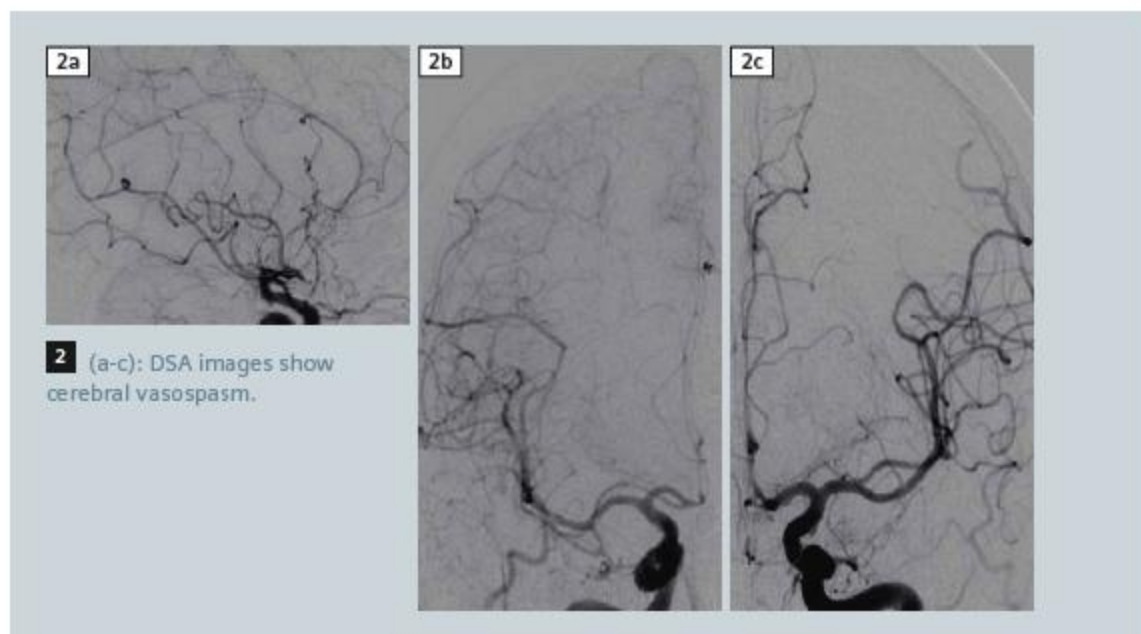
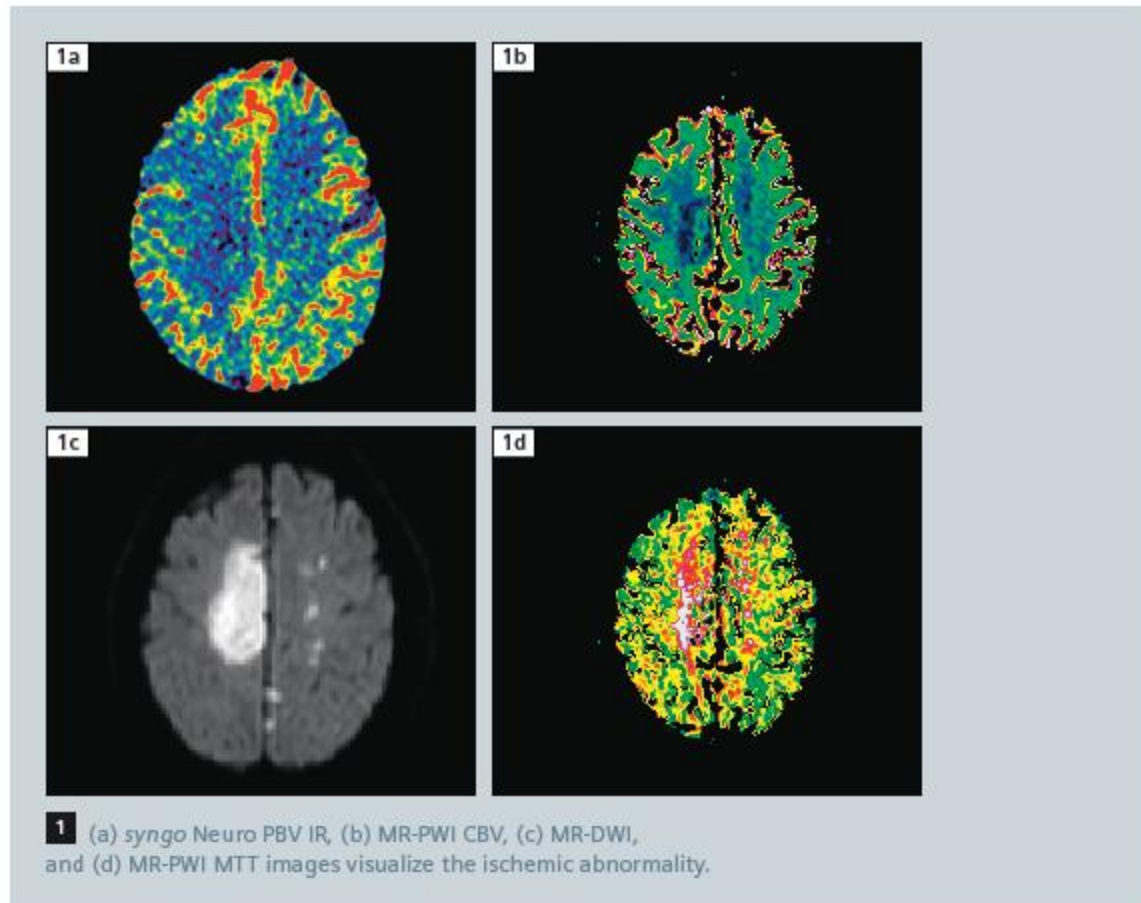
A 60-year-old lady presented (day 0; WFNS grade 1) with ruptured anterior communicating artery aneurysm (5 × 7 mm). The patient was treated by coil embolization (day 1) and she recovered well without neurological deficits (WFNS grade 1). On day 3, her level of consciousness deteriorated with onset of numbness in the left arm and leg. CT scan, performed on the same day, was normal and excluded ischemia, re-bleeding, or progressive hydrocephalus. On day 4, the patient developed weakness of both legs and was transferred to Neuro ITU for supportive therapy.

Diagnosis

Perfusion weighted MRI (MR-PWI) on day 4, showed asymmetric cerebral hypo-perfusion, more marked in the right hemisphere (Fig. 1). On catheter angiography, cerebral vasospasm was evident affecting the anterior cerebral arteries (Fig. 2).

Treatment

A syngo Neuro PBV IR scan was performed during the same session as catheter angiography. On the syngo Neuro PBV IR maps, demarcated areas consistent with ischemia were evident and these correlated well with both the angiographic distribution of vasospasm and areas of hypo-perfusion seen on MR-PWI. The patient was treated by intra-arterial injections of the vasodilator Nimodipine.



Contact

stefan.sl.lautenschlaeger
@siemens.com