

Issue no. 2 · 2004
RSNA Edition

www.siemens.com/magnetom-world

Content

3rd MAGNETOM
World Summit
Rottach-Egern,
Germany,
June 23-25, 2004

MAGNETOM FLASH



SIEMENS
medical

29

3rd MAGNETOM World Summit Rottach-Egern, Germany, June 23-25, 2004

The 3rd MAGNETOM World Summit has climbed greater heights than even its two predecessors – thanks to ~180 MAGNETOM users from 24 countries gathering together in the picturesque Alpine resort of Rottach-Egern.



Those who imagined Bavaria as a thrilling mix of copious quantities of beer and wine, good food and clean, fresh mountain air were not disappointed. Add to that an intoxicating mix of lusty singing and boisterous, thigh-slapping dancing, and you have some idea of just a little of the atmosphere of the MAGNETOM World dinner hosted in a typical Bavarian restaurant.



But to experience it all, you had to be there...







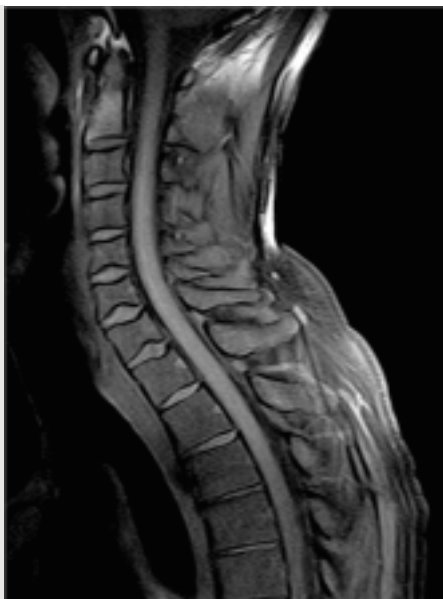Dr. Montag, Vice President of MR, introduced his talk with proud recognition of the 180 participants from 24 countries in attendance at the 3rd MAGNETOM World Summit. This multinational gathering accurately reflected the nature and purpose of the summit, of a world community bonding together. He also introduced the “Life” customer care program, demonstrating the continuous fruitful partnership between Siemens and its customers.



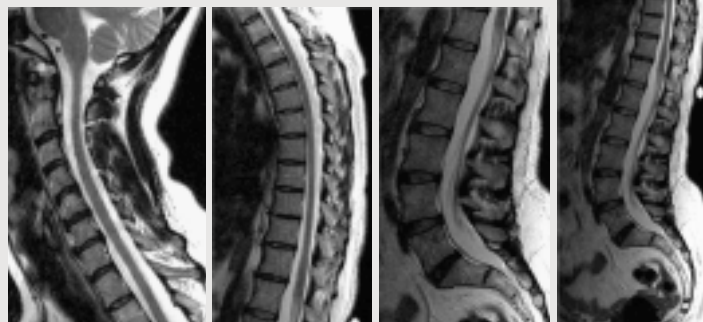Dr. Kolem, the President of MR, outlined the global organization of the MR Division with production in Germany, the United Kingdom, the USA and China. He also showed the market growth of Siemens MR with increased sales in USA, Japan and China. His final remarks were a reflection of developments in the production units: “Tim Technology is our future”.



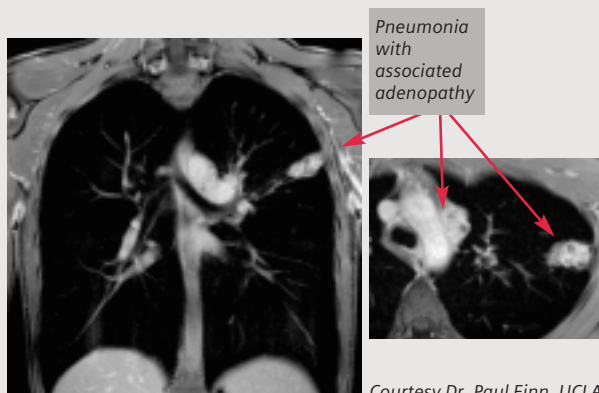
Stuart Schmeets from Siemens US described his experience with the MAGNETOM Avanto. He summarized the system as revolutionary in improving existing applications and helping to create new ones. The coverage with the Total Imaging Matrix allows evaluation of entire anatomic regions and even the whole body. He added that scan time reduction with iPAT had also created the perception that there are no boundaries to the capability of the system.



Fat suppression is excellent with MAGNETOM Avanto due to high homogeneity of the system.



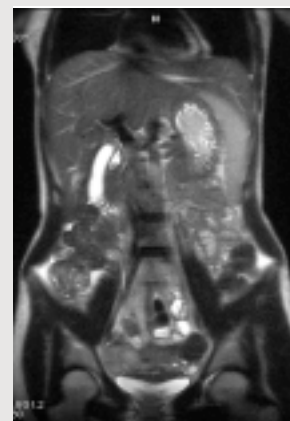
Tim sees all in evaluating large anatomic areas such as the spine by seamlessly integrating data-sets for a clearer understanding of the entire region.



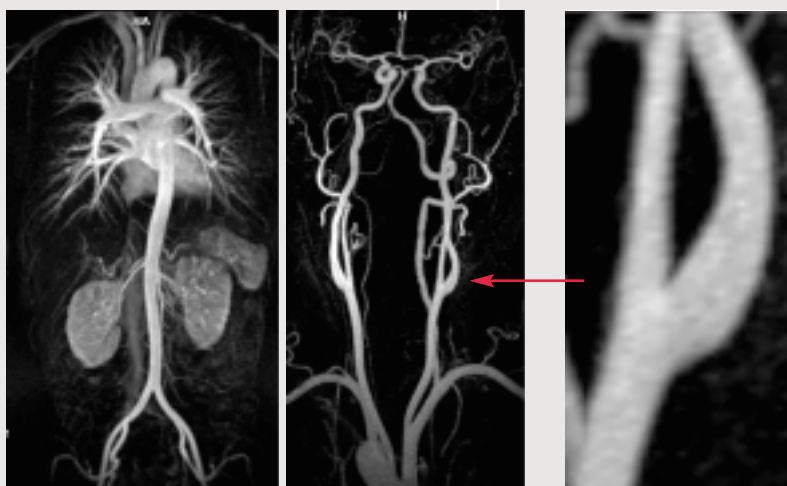
Pneumonia with associated adenopathy

Courtesy Dr. Paul Finn, UCLA

Excellent SNR. MAGNETOM Avanto provides high quality lung imaging with TrueFISP over the entire lung field. Notice also the consistency in the spectral fat suppression over the entire field of view.



Tim sees all by providing larger field of views with consistent signal to noise ratios across the entire field of view.



With the capability of up to 205 cm coverage, an entire region such as the arterial circulation of the chest, abdomen, and pelvis can be covered with a single injection or we can focus our attention in a specific region like the carotid arteries from the brachio-cephalic trunk to the circle of willis. All the while maintaining the high spatial resolution necessary for diagnosis.




From his perspective in Research and Development, at Siemens MR, Dr. Berthold Kiefer commented on the new developments to MAGNETOM Avanto and Tim, concentrating particularly on the major developments in parallel imaging brought about by MAGNETOM Avanto. He followed this with an examination of whole body applications, pre-scan normalize technique and workflow improvements. He also showed the results using new WiP techniques and new coils.

Parallel Imaging at Siemens

Both k-space and image domain based reconstruction modules

- Autocalibration based
- User selectable
- Always have optimal solution

*Mark Griswold et al., Generalized autocalibrating partially parallel acquisitions (GRAPPA). MRM 2002



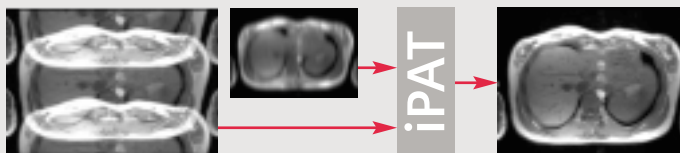
K-space.

Image Domain.

Parallel imaging at MAGNETOM systems comprises of both k-space and image domain based reconstruction modules. This provides the optimal solution for various applications.


Autocalibration

- + No separate prescan
- + Insensitive to pat. motion
- + Increased SNR

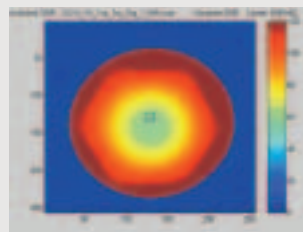


Calibration is integrated in the sequence with iPAT, no separate pre-scan is needed. The advantages of this approach are: no separate pre-scan is needed, increased SNR and also the sequence is insensitive to patient motion.

SNR maps: Volume Head Coil versus 12-Element Head Matrix



CP Head coil.

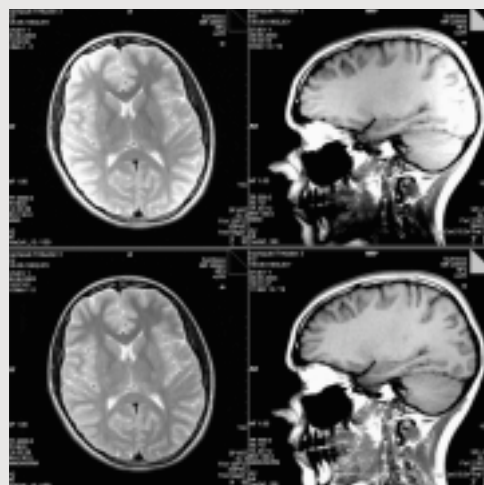


12-element Head Matrix.

Multichannel head coil SNR map. Comparison between a head volume coil and array coil shows an increase in SNR with 12-element Head Matrix coil.

Powerful Image Normalization with Prescan Normalize

Tim Head Matrix (12-element)



No
Normalize

Pre-scan
Normalize

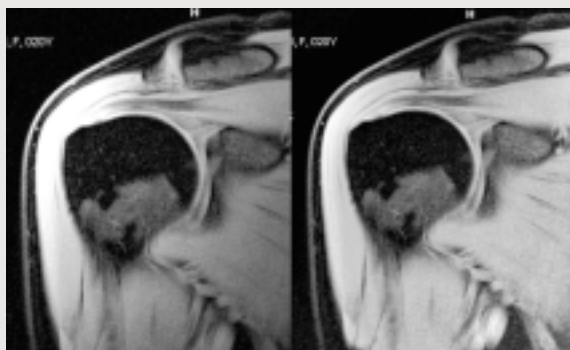
With Tim technology a powerful normalization algorithm is implemented which creates homogenous images with multi-channel array coils.

Prescan Normalize

Shoulder Array

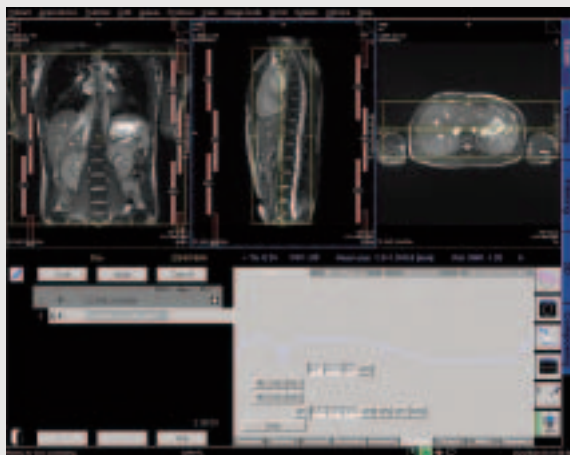
No Normalize

Pre-scan Normalize



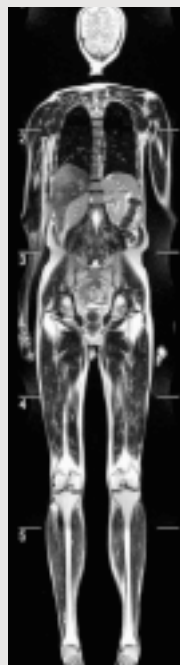
Homogenous signal intensity in the shoulder images with prescan normalize.

Intelligent Coil Control: Automatic coil position detection

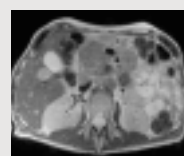
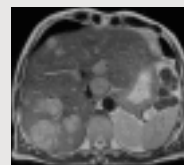


Location of elements of all connected coils is shown in the UI. Remote coil manipulation requires only the selection of the coil elements in the user interface with one mouse click.

Whole body Tumor Evaluation in 2:30 min



1. Fast HASTE
Screening showing
liver metastasis.
HASTE with
GRAPPA *2
Resolution:
1.3 x 1.1 x 6 mm



2. High resolution
T2w-TSE. Lymph node
and liver metastasis.

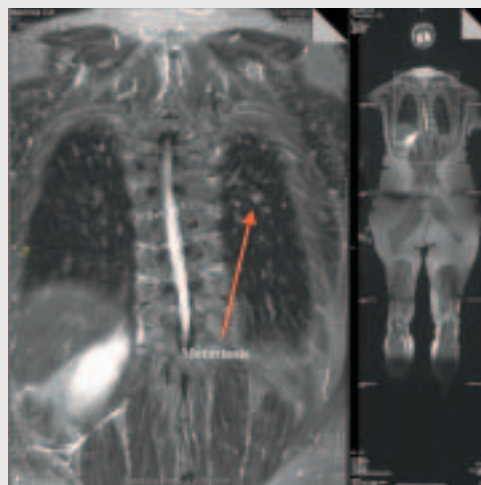
*Courtesy: J. Gaa, Klinikum
Rechts der Isar, Munich*

High resolution Whole Body imaging with local surface coils is a possibility with MAGNETOM Avanto systems. The composer software combines the images from different levels and provides a whole body image which simplifies the work of the examining physician.

Patient with Breast Carcinoma

STIR TSE with GRAPPA *2

Whole body measurement in 5 steps.

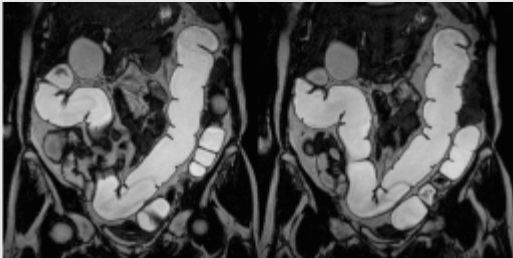


*STIR whole body imaging with resolution of
1.1 x 1.1 x 5 mm showing lung metastasis.*

Courtesy: H-P Schlemmer, University Tübingen

High Acceleration Factor with PAT²


Courtesy: J. Schäfer, University Tübingen



PAT factor 6 can be reached with the new Tim system from Siemens. An example of MR Colonoscopy of $1 \times 1 \times 2 \text{ mm}$, 88 partitions in only 18 seconds. 12 body matrix elements and 12 spine elements were used.

Advantages of TSENSE:

- No extra time needed for calibration
- Continuous update of coil sensitivity data




Work in progress topics were also mentioned during the talk. TSENSE is a new parallel acquisition strategy for dynamic applications with continuous update of coil sensitivity data.

Echo-Shared 3D + iPAT

Improved dynamic frame rate by combining

- iPAT
- echo sharing

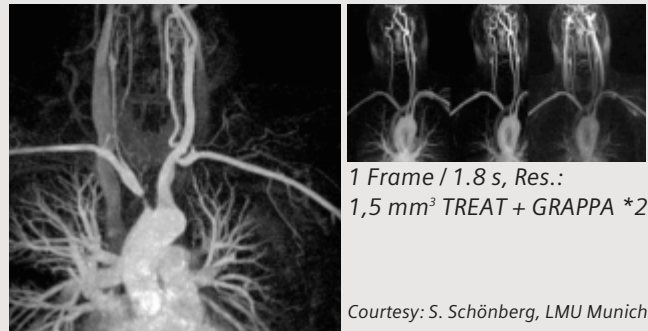


- Center of k-space lines (segment A) are updated more frequently than outer k-space lines
- Outer k-space segments are shared between adjacent measurements

Another works in progress topic was sequences with improved dynamic frame rate by combining iPAT and echo sharing.

Echo Shared dynamic MRA + iPAT

Patient with Subclavian Steal Syndrome



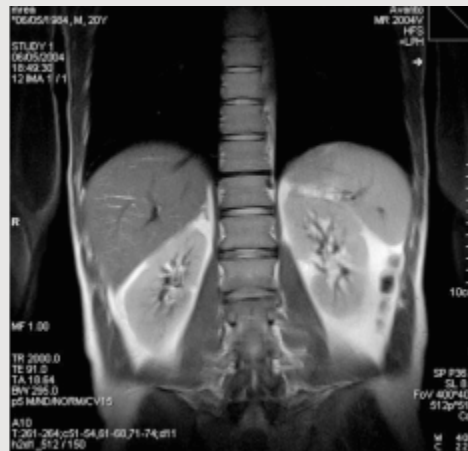High resolution angiography:
 0.7 mm^3

Carotid stenosis. left: high resolution 0.7 mm^3 , right: time resolved with shared echo + PAT x 2, temporal resolution = 1.8 s, spatial resolution: 1.5 mm^3 Retrograde flow in the vertebral artery.

Courtesy: S. Schönberg, LMU Munich

32 channel Cardiac array*

PAT shortens echotrain



GRAPPA *5

HASTE with 512 resolution is seen with the 32-channel Cardiac Array coil being developed by RAPID Imaging. Acceleration of factor 5 shortening the echo train and decreasing the blurring.

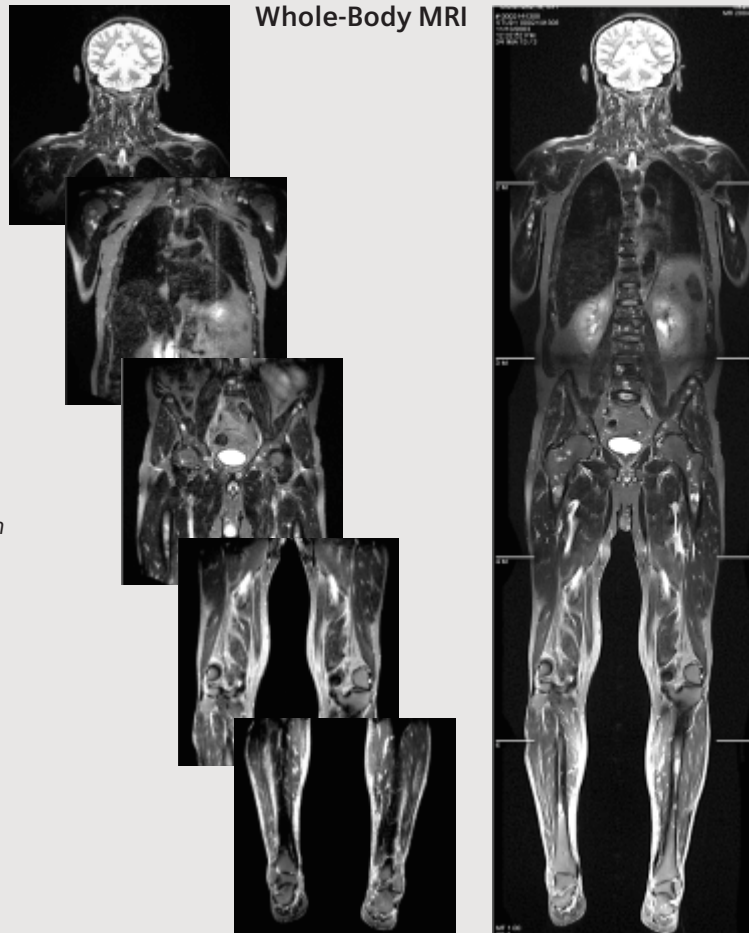
*WIP: The information about this product is preliminary. The product is under development and is not commercially available in the U.S., and its future availability cannot be assured.



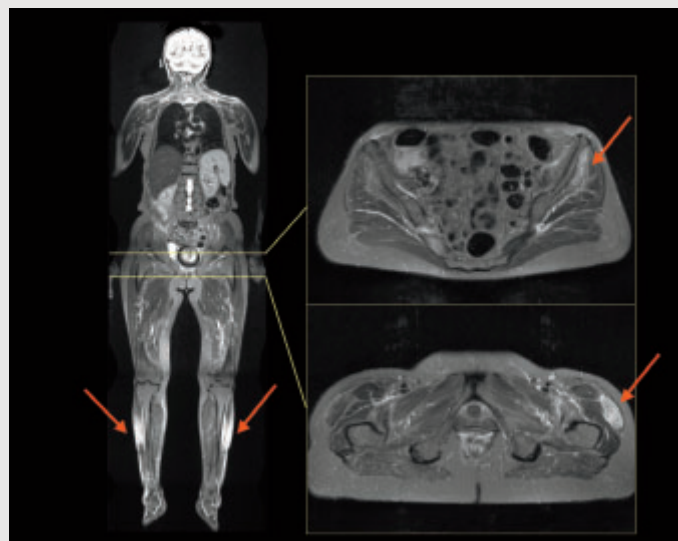
“Tuebingen University houses the first MAGNETOM Avanto site in Europe. Dr. Schlemmer summarized his experience with the system and focused on the whole body imaging and its effects in a routine daily practice. He indicated that whole body imaging was already a clinical reality in the area of MRI and that Avanto had introduced the idea of imaging the systemic effects of diseases during referrals from the clinicians. This approach, although beneficial for the patient, had increased the workload which, he said, must be improved with CAD (Computer Aided Diagnosis) and improved communication with PACS systems.



Whole-Body MRI in 5 steps with MAGNETOM Avanto providing high resolution images of all body parts.



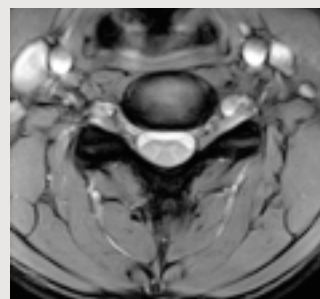
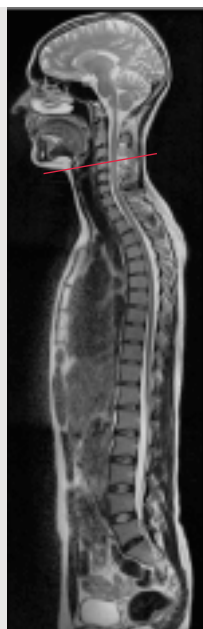
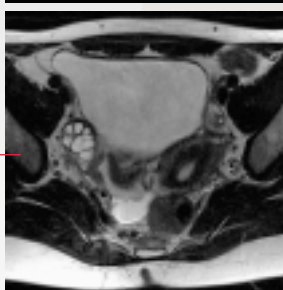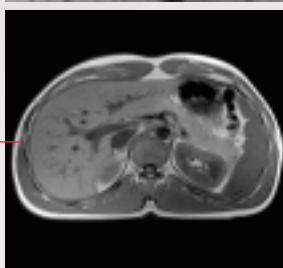
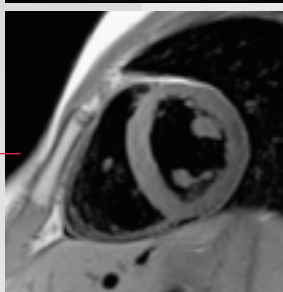
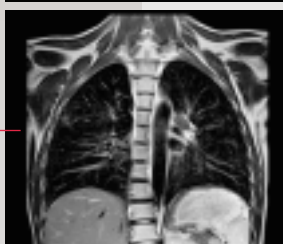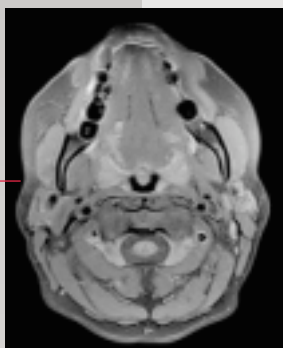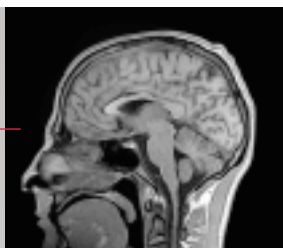Polymyositis



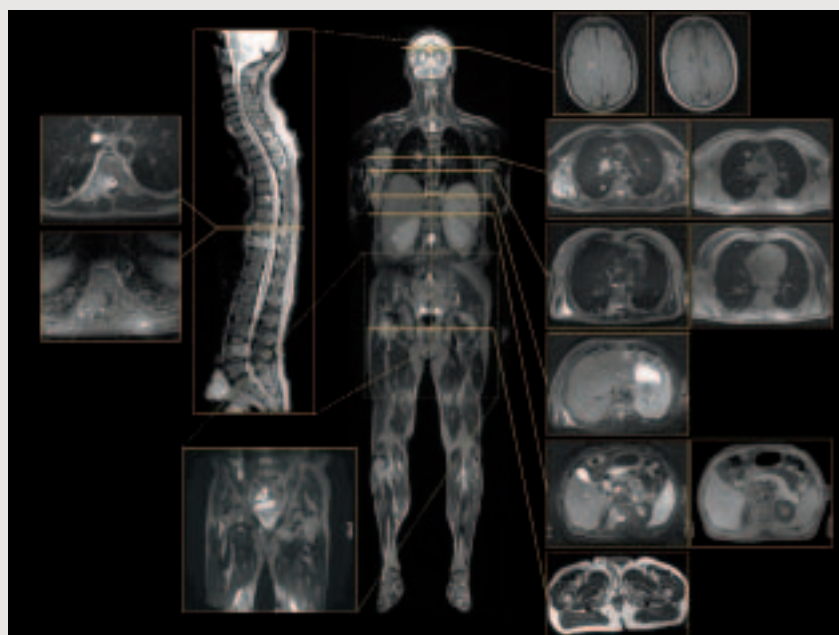
Polymyositis patient, whole body imaging in 15 minutes showing the affected areas providing the clinician necessary information to choose the appropriate biopsy sites.

Whole Body MRI =

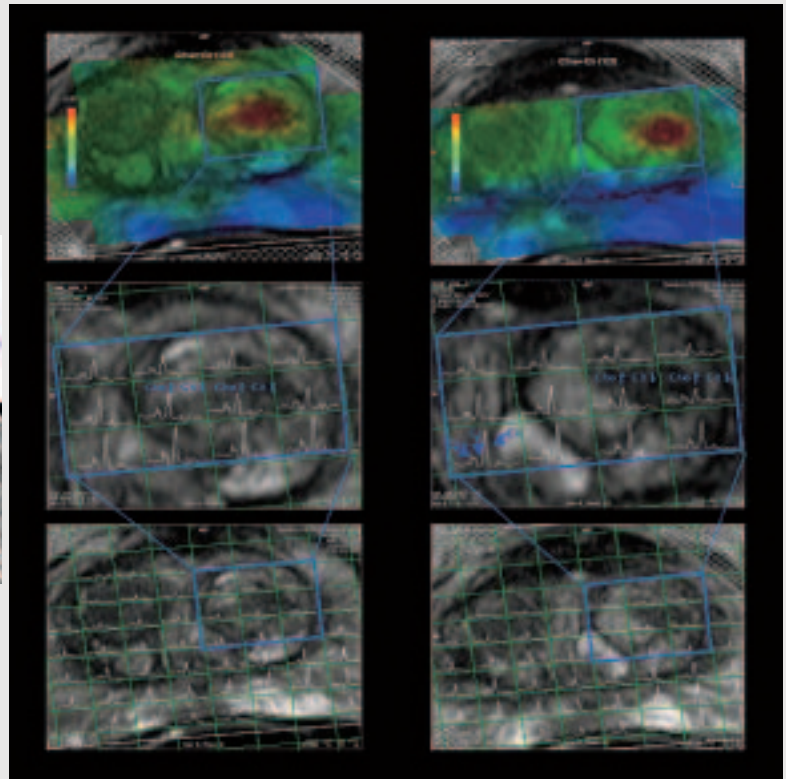
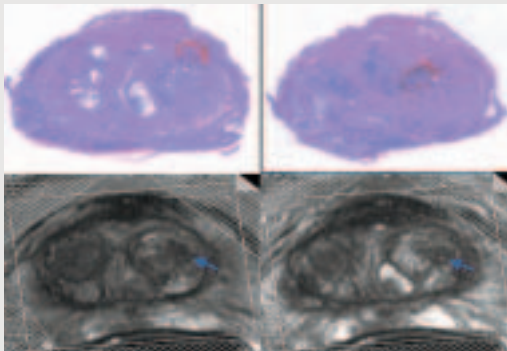
Comprehensive evaluation of entire functional systems.



With image composer it is possible to create views covering the whole spine. After general views, high resolution additional slices help to obtain more detailed information.

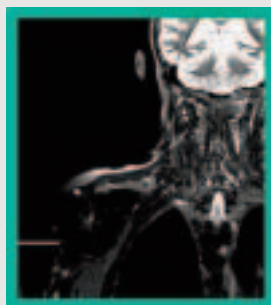

Use of whole body imaging for oncology can show various pathologies which were not seen by other modalities or only localized MR studies.

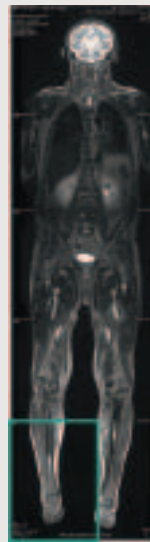
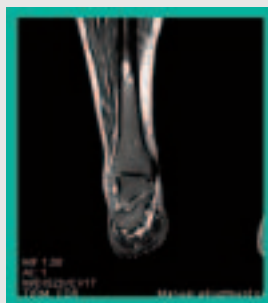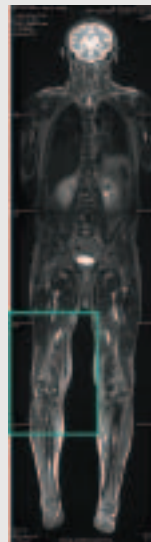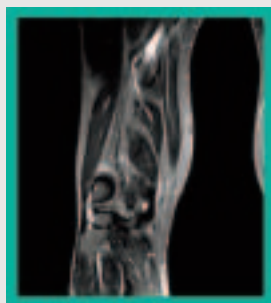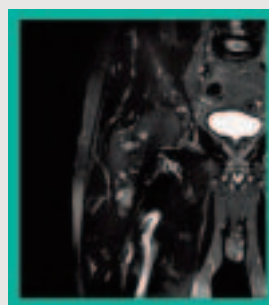
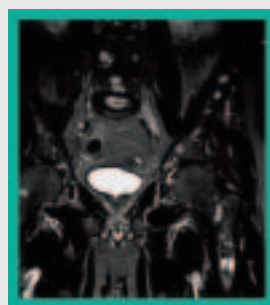

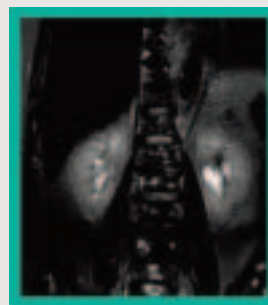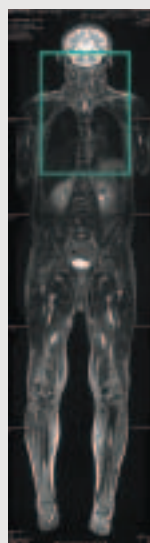
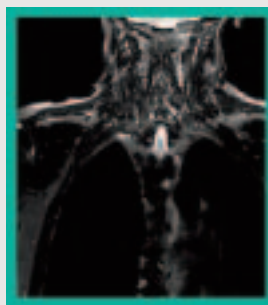
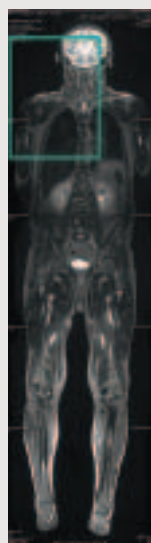


3D proton MR spectroscopy is helpful in providing more functional information to suspected pathologies that are seen during whole body imaging.

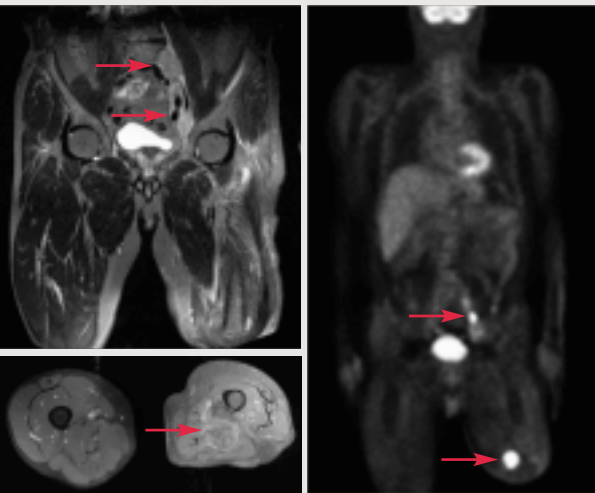
Plasmocytoma



Dedicated MRI can visualize more lesions in diagnosis and evaluating the spread of plasmocytoma.

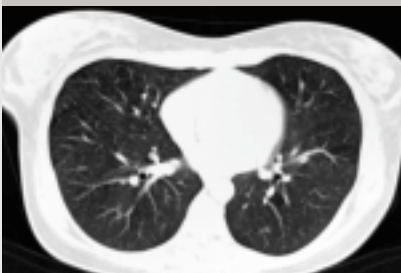

Sarcoma

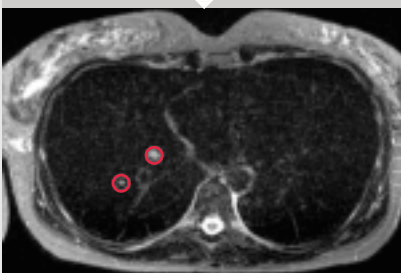


Lymphatic spread in the iliac area was diagnosed by MR and confirmed by PET.

Metastases with CT?

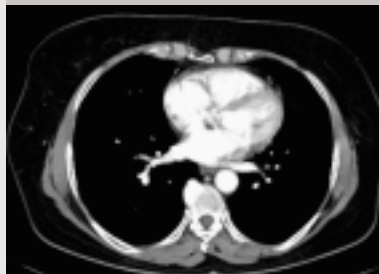

Lung Metastases with MR

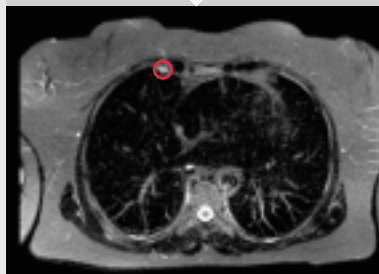

MRI might be more sensitive in visualization of various pathologies compared to CT even in lung imaging.

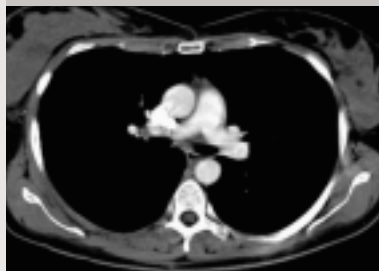Metastases with CT?



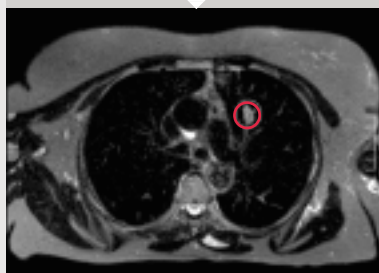
Pleural Metastasis with MR



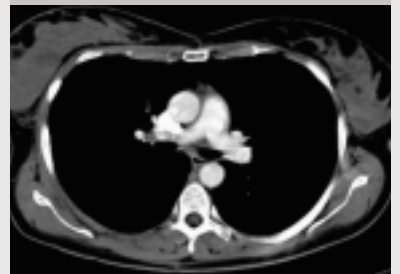Metastases with CT?



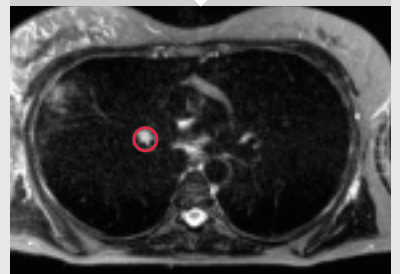
Lung Metastases with MR



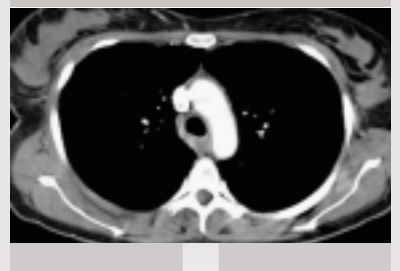
Metastases with CT?



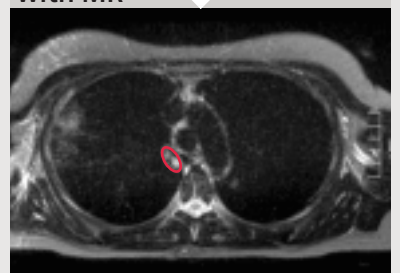Hilar Lymphoma with MR



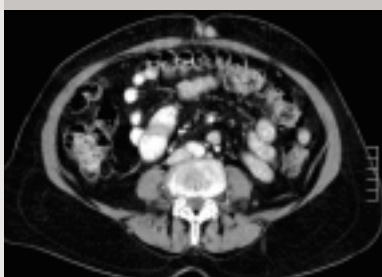Metastases with CT?



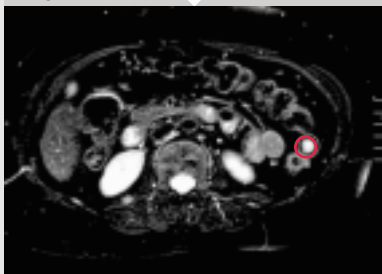
Mediastinal Lymphoma with MR



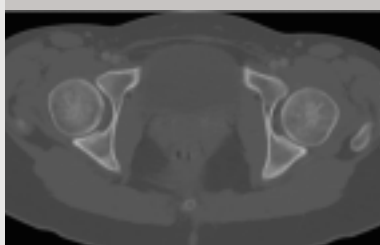
Metastases with CT?



Peritoneal Metastases with MR

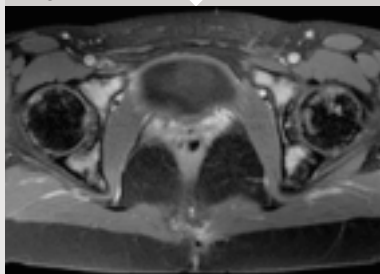


Metastases with CT?

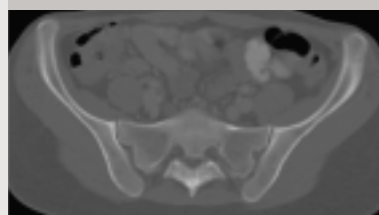


Malignant melanoma patient showing involvement of the bone

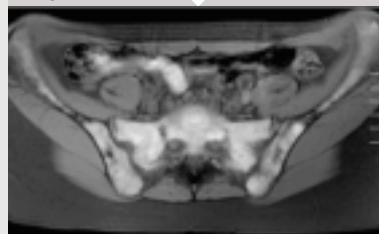
Bone Marrow Involvement with MR



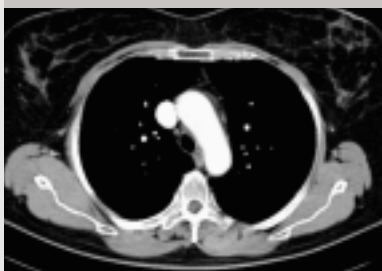Metastases with CT?



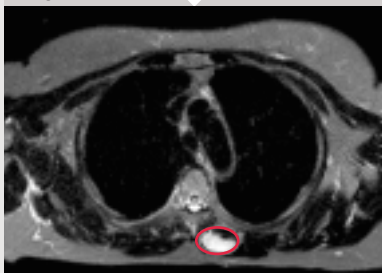
Bone Marrow Involvement with MR



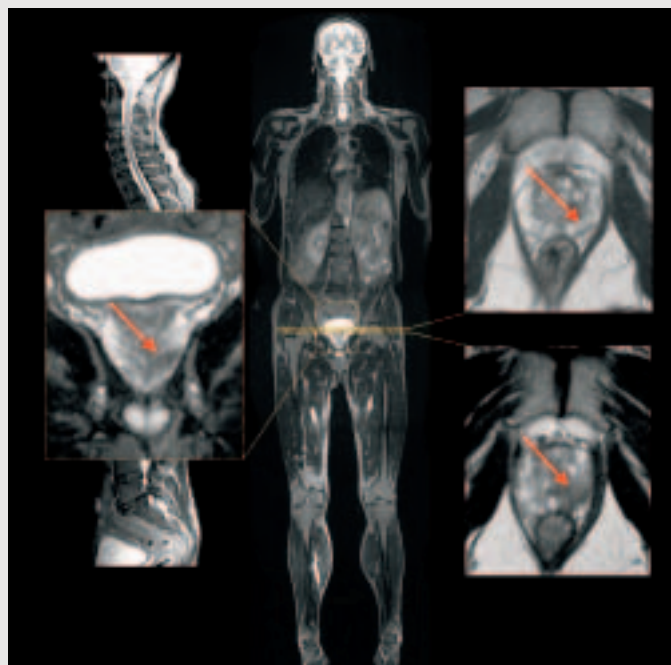
Metastases with CT?



Soft Tissue Metastasis with MR



Screening for Metastases



Low intensity lesion detected in the prostate from a patient who had a previous history of malignant melanoma and who had been referred for evaluation of metastasis. No metastasis was found but a prostate lesion was detected which after biopsy proved to be prostate carcinoma.



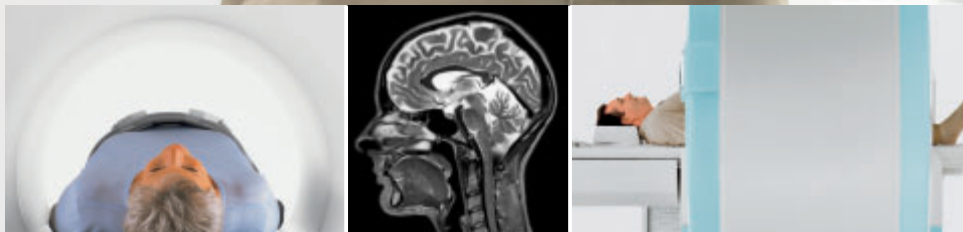We see a way to provide patients with CT-like comfort in a 1.5T MRI

At 1.5T, it will run
circles around any
other Open MRI.

MAGNETOM Espree
with **Tim.**

Results may vary. Data on file.

www.siemens.com/medical



M-Z876-1-7600

Proven Outcomes with Open Bore MRI.

Finally, the performance barrier has been broken in Open MRI. Introducing MAGNETOM® Espree™ with Tim™ (Total imaging matrix technology). The strength of 1.5T combined with the CT-like comfort of Open Bore MRI. With its 70 cm bore and 125 cm width, accessibility, flexibility, comfort, and power have all come together. For the most patient-optimized Open available today. MAGNETOM Espree

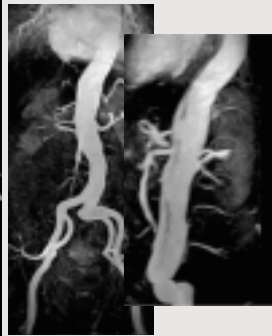
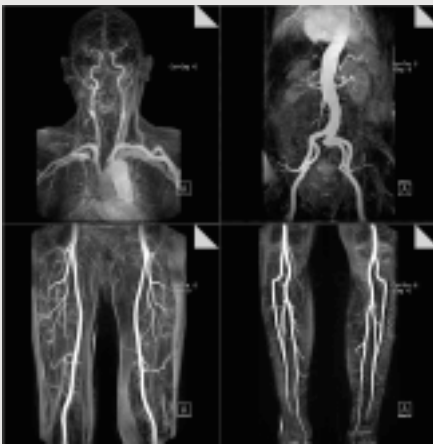
with Tim means shorter exam times. Much faster clinical routine. Higher SNR for superior image quality. And better contrast for true diagnostic precision. It's about power that doesn't hold anything back. And comfort that keeps patients coming back. MAGNETOM Espree. It goes where no Open has gone before.

SIEMENS
medical

Siemens **Medical Solutions** that help

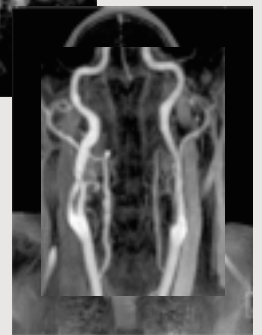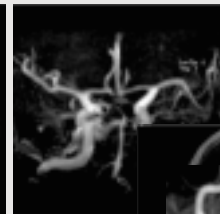
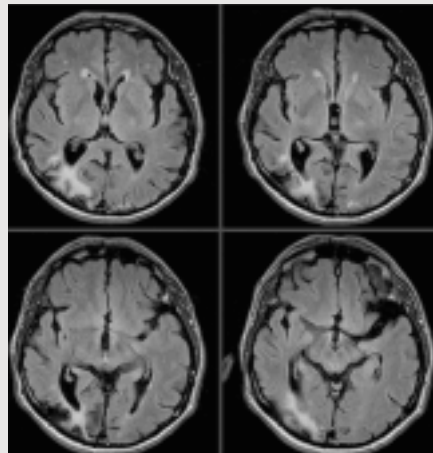


Dr. Stephan Miller, from the University of Tuebingen, showed results of whole body angiography applications from his clinic. Atherosclerosis, systemic diseases and vasculitis are the major indications for this application. He detailed the various imaging strategies and the differences between them.

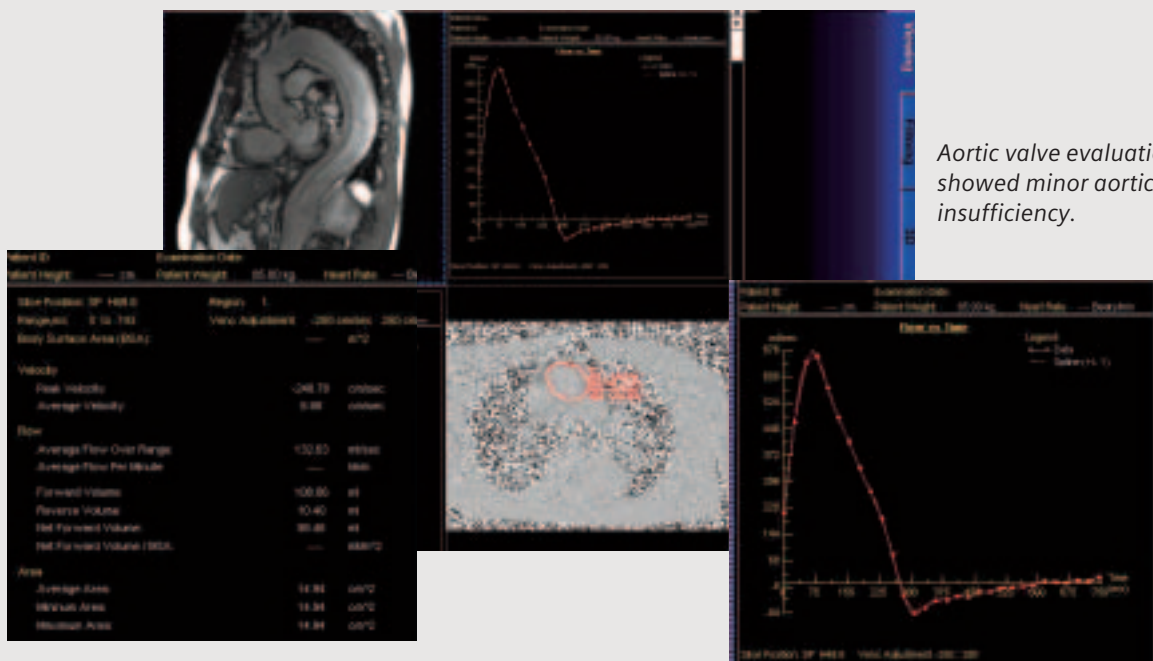


Previous aortic dissection (Type A), 69 year old patient after therapy including repair of the ascending aorta and reconstruction of the aortic valve. There is visualization of the dissection membrane in the descending aorta.

Perioperative stroke due to internal carotid stenosis and the following hemodynamic changes.



Male 69 year old, type A aortic dissection.

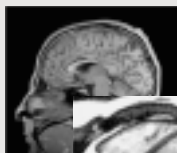

Aortic valve evaluation showed minor aortic insufficiency.

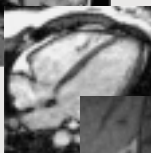Systemic Atherosclerosis

organs of predilection

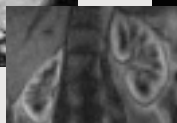brain



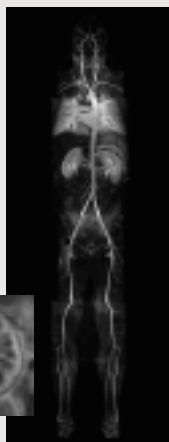heart



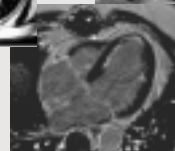
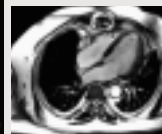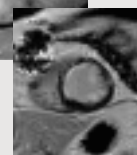
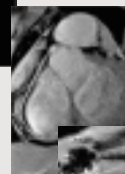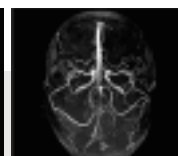
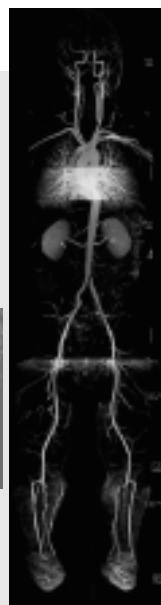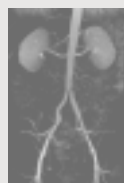kidneys



arterial system

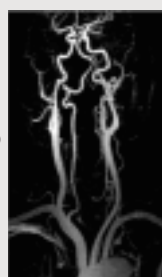

Major application of whole body MRA is evaluation of atherosclerosis.




Major application of whole body MRA is the evaluation of atherosclerosis and vasculitis which are both systemic diseases. The patient had proximal stenosis of the common iliac artery (left), late enhancement* of the anteroseptal wall, also there is dyskinesia of the wall seen with dynamic cine images in the same area.

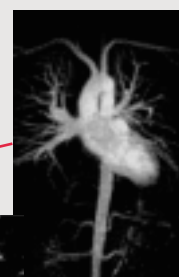> 90%



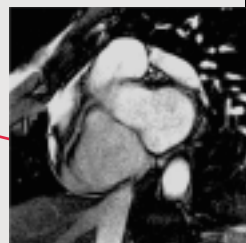
> 80%



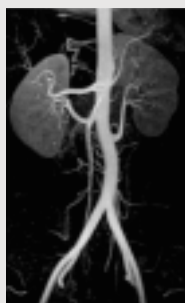100%



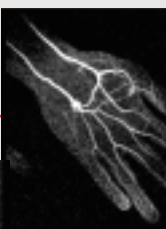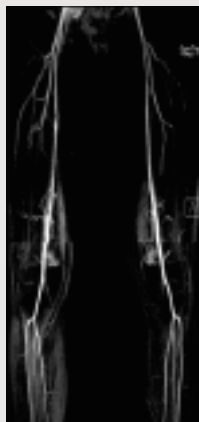40-74%



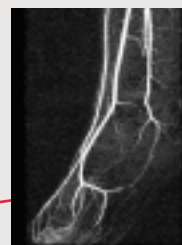90-100%



> 90%

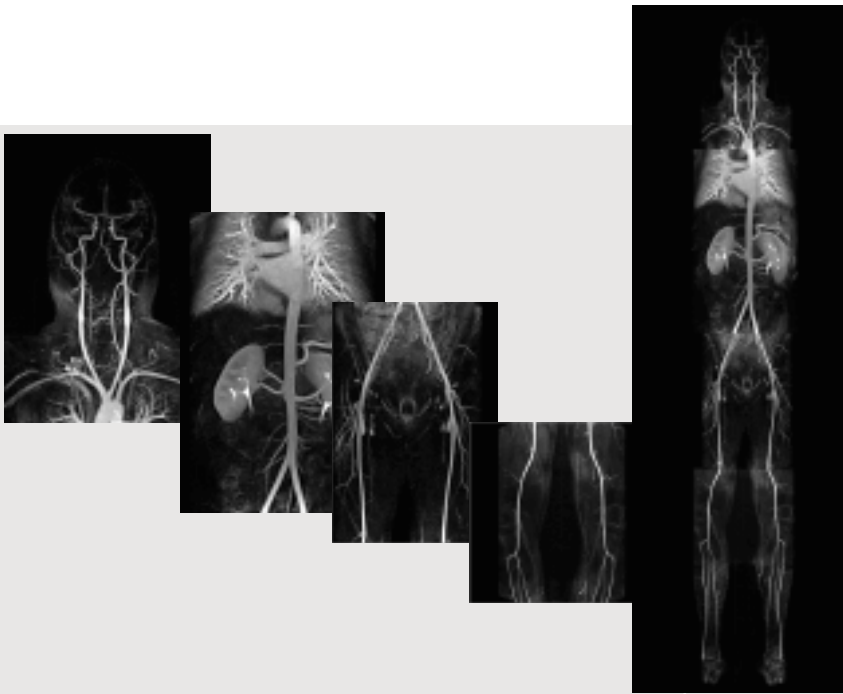


> 90%



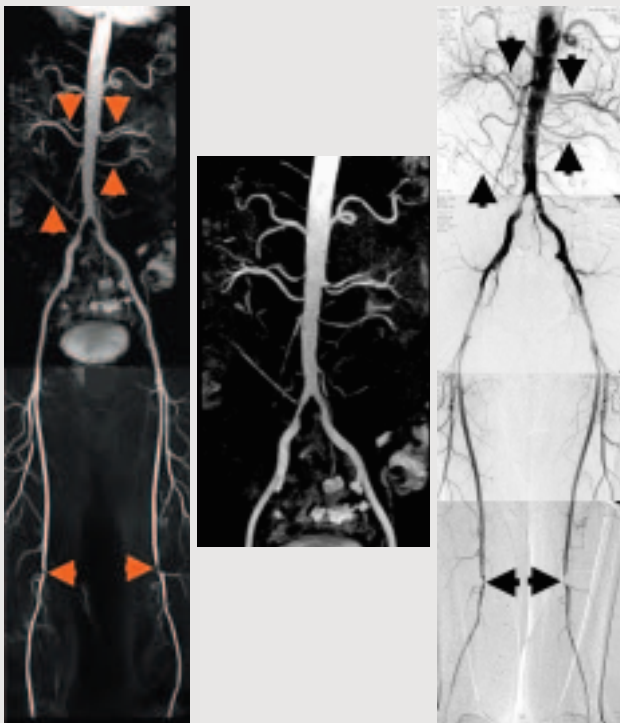
Diagnostic accuracy of MRA in diagnosis of different vascular pathologies.

*WIP: The information about this product is preliminary. The product is under development and is not commercially available in the U.S., and its future availability cannot be assured.



Tuebingen University Radiology department prefers double injection strategy for whole body MRA.

MRA vs. DSA



Comparison of DSA and MRA shows very high correlation between the two exams.

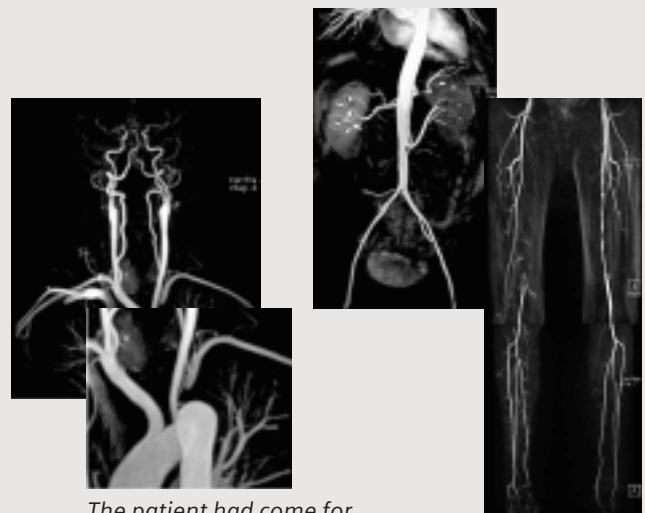Imaging parameters

no compromises!

	type	TR [msec]	TE [msec]	Flip	PAT	voxel [mm]
I - head	3D TOF	36	7.15	20°	1	0.8x0.6x0.8
II - Thorax	3D CE	3.4	1.14	25°	2	1.3x1.0x1.5
III + IV	3D CE	3.4	1.14	25°	2	1.6x1.0x1.5
V – low. leg	3D CE	3.4	1.14	25°	off	1.6x1.0x1.2

0.25 mmol Gd-DTPA/kg

MAGNETOM Avanto protocols used in Tuebingen University for whole body MRA.



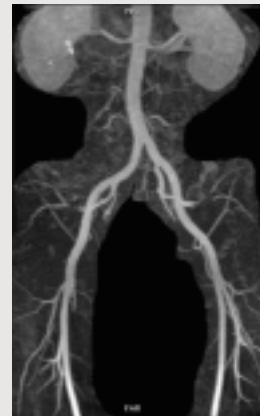The patient had come for evaluation of peripheral arterial disease, whole body MRA showed a subclavian steal syndrome.



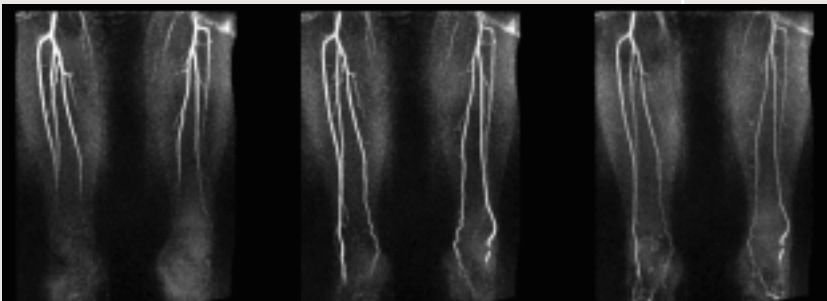New York University is the first MAGNETOM Avanto site in the USA. In her presentation, Dr. Hecht summarized the results from her clinic in the area of "Body MRI", claiming the new system had brought 1. Faster, better routine clinical imaging; 2. Enhanced functional, physiologic imaging, and 3. New applications which previously were not possible.



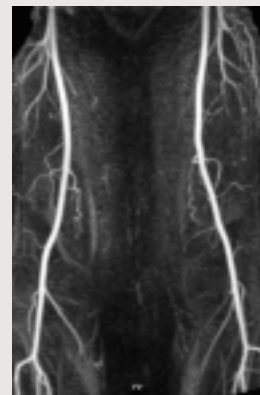The first MAGNETOM Avanto in the US was delivered to NYU.



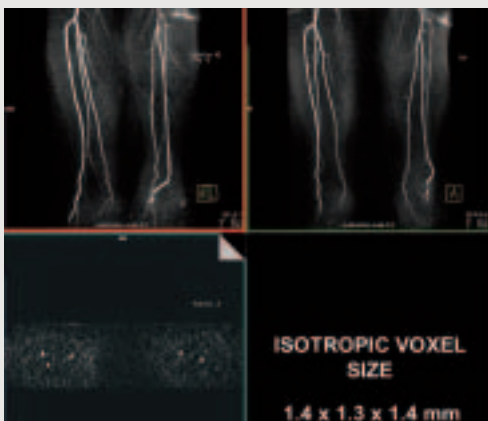
*First station of peripheral MRA:
3.3/1.2/25, 448 matrix,
1.4 mm x 80, 12.7 s, PAT x 3.*



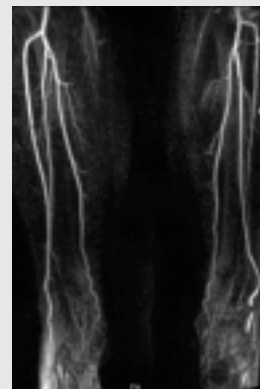
*NYU Peripheral MRA with MAGNETOM Avanto.
Nowadays NYU prefers to use 3D Time Resolved
Imaging for evaluating the distal vessels: PATx3,
3.4/1.2/25, 384 matrix, 1.4 mm x 52, 8.4 s acquisition
time.*



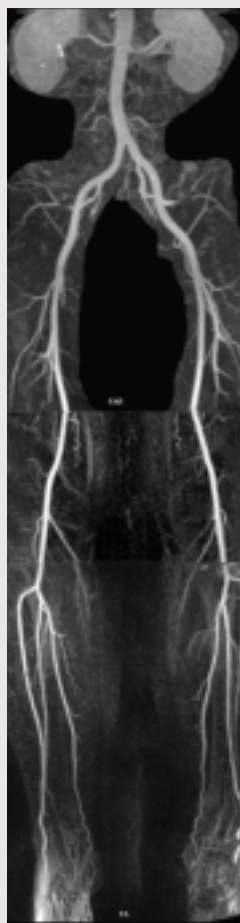*Second station of
peripheral MRA.
3.3/1.2/25, 448 matrix,
1.4 mm x 64, acquisition
time 9.4 s.*



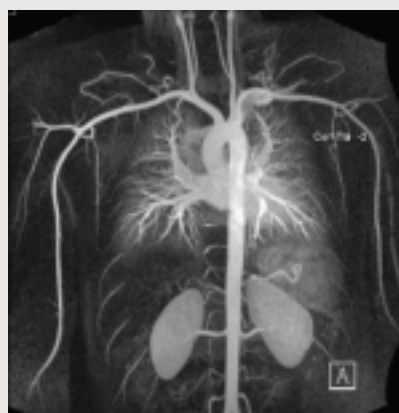
*Isotropic voxel size with time resolved MRA:
1.4 mm x 1.3 mm x 1.4 mm.*



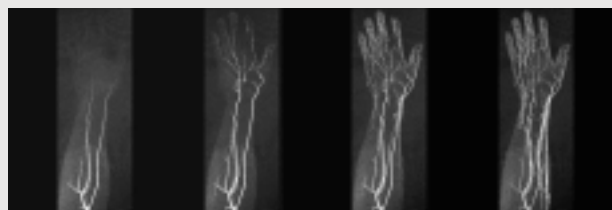
*Third station of
peripheral MRA
3.4/1.2/25, 448 matrix,
1.4 mm x 72, acquisition
Time 10.3 s, PAT x 3.*



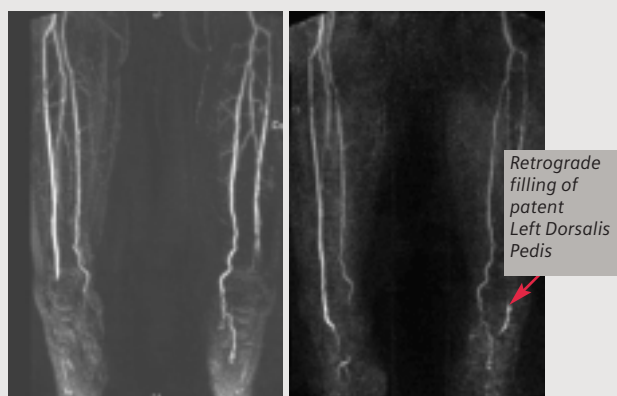
Peripheral MRA with coverage starting from renal arteries to distal foot vessels in less than 45 s.



Large FoV MR Angiography with MAGNETOM Avanto.

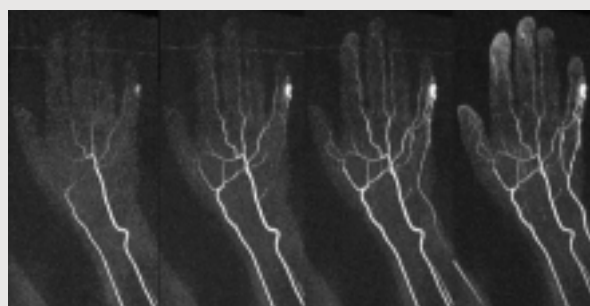


Time-resolved Hand MRA with MAGNETOM Avanto showing occlusion of right second finger digital artery.

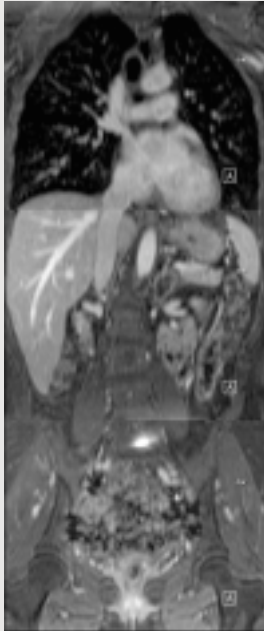


Bolus Chase 3rd Station Time-resolved MRA

Time-resolved MRA provides functional dynamic information which might lead to more detailed information compared to conventional MRA. Like in the case shown here, the conventional exam shows no dorsalis pedis artery but the time resolved exam shows retrograde filling of dorsalis pedis on the left side.



Time-resolved MRA helps in diagnosis of vascular malformations. PAT x 3, 384 Matrix, 1.4 mm x 64, 5.1 s.



CHEST

AX T1 IN/OP
AX DB HASTE
AX T2 TSE FS
AX VIBE PRE/POST

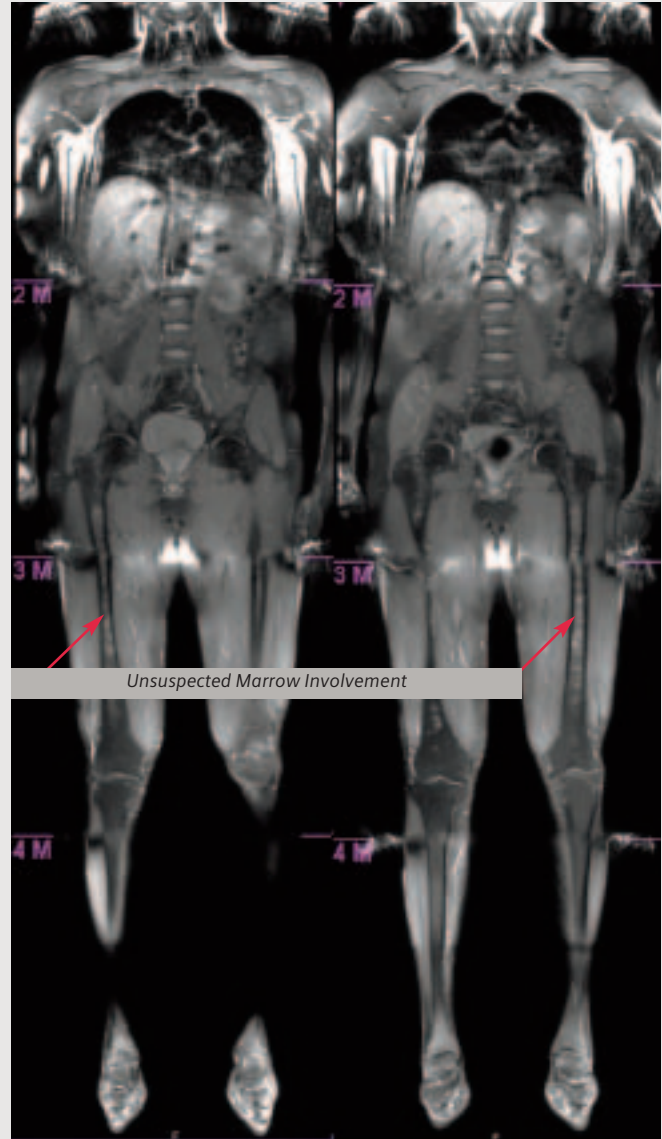
ABD

AX T1 IN/OP
AX HASTE
AX T2 TSE FS
COR HASTE
AX VIBE PRE
AX DYNAMIC VIBE

PELVIS

AX T1 IN/OP
AX T2 TSE FS
AX VIBE PRE/POST

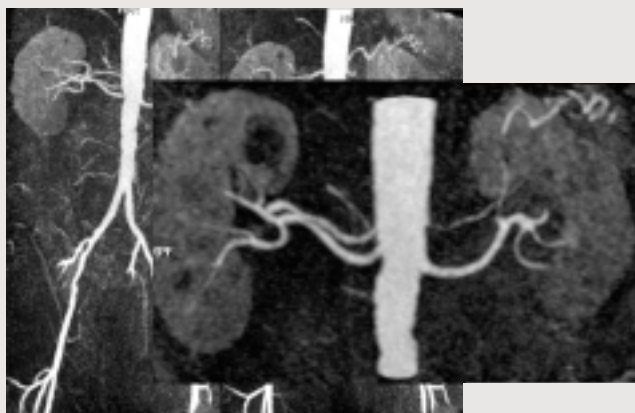
"Chest, abdomen and pelvis" examination is a common requirement for CT. MAGNETOM Avanto whole body imaging allows this examination to be performed easily with more detailed information without any radiation.



FS-Proton Density

In this case of sarcoidosis, a patient with foot neuropathy but no other known bone lesions was evaluated with MAGNETOM Avanto. The resulting whole body exam showed bone marrow involvement which was not diagnosed before.

iPAT x 4 Renal MRA



Renal MRA with PAT x 4.

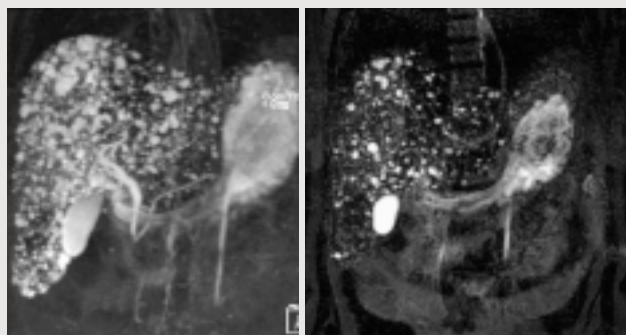
Scout	20 s
STIR x 2	19 s x 2
T1 GRE (in/out phase)	23 s
Coronal HASTE (MRCP)	20 s
Axial HASTE (MRCP)	20 s
Thick Slab-2D TSE (MRCP)	8 s x 3
Optional Gd-VIBE	24 s
All 256 matrix	

Former Liver/
MRCP Protocol



Scout	20 s
FS-T2 TSE	13 s
T1 GRE (in/out phase)	12 s
Coronal HASTE (MRCP)	20 s
Axial HASTE (MRCP)	20 s
3D TSE (MRCP)	2 min
Optional Gd-VIBE	14 s
Most 512 matrix (VIBE 320)	
Most with at least R = 2 – 3 (iPAT 2-3)	

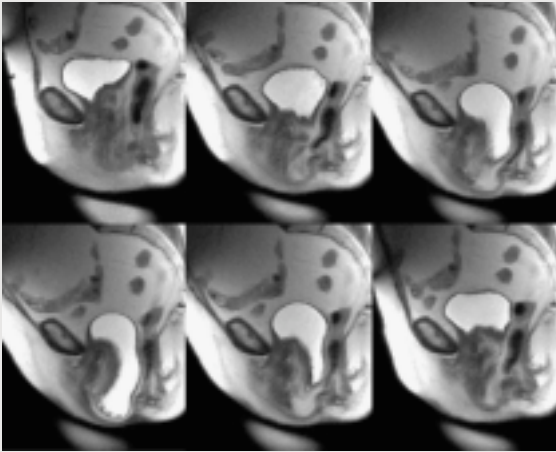
Parallel Imaging Protocol with MAGNETOM Avanto
today.



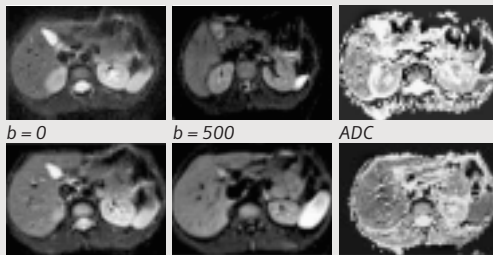
3D PACE TSE (2 min)

Source Images (1 mm slices)

3D TSE with parallel imaging!



With Parallel Imaging, multi-slice realtime imaging is possible for evaluation of pelvic floor pathologies. Comprehensive functional information can be obtained in less than 1 minute. This case shows cystocele and rectal prolapse after Valsalva maneuver.

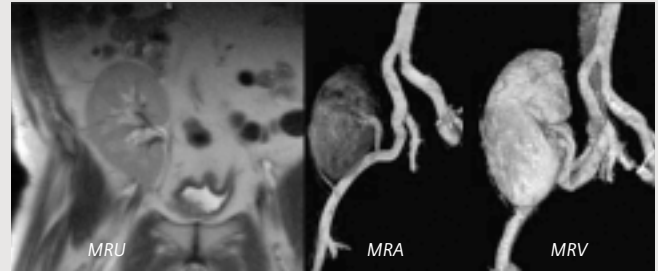


Conventional
Diff. SENSE

DTI-SENSE

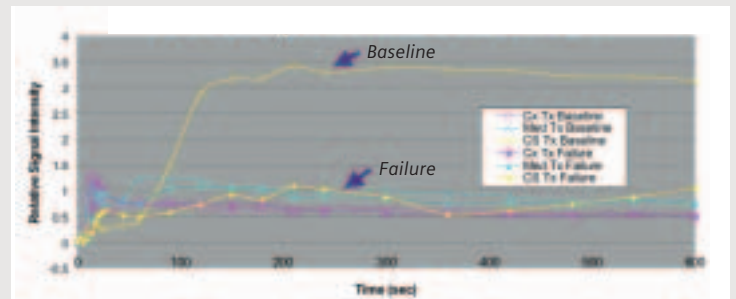
	SENSE-CDI	SENSE-DTI
Normal (n = 10)	1.52 ± 0.15 (1.28–1.80)	1.51 ± 0.21 (1.27–1.99)
HCV (n = 5)	1.17 ± 0.22 (0.72–1.39)	1.24 ± 0.20 (1.17–1.35)
P	< 0.006	< 0.03

NYU radiologists are working on the diffusion weighted imaging and Diffusion Tensor Imaging of the liver to figure out whether restricted water diffusion in cirrhosis patients might be related to liver fibrosis.



To evaluate graft dysfunction, an extensive examination of the transplant kidney includes MR urography, MR arteriography, MR venography and dynamic perfusion studies. Aim of these studies is to obviate biopsy in failing grafts.

Renal Transplant: Baseline and Failure



Biopsy = Acute Tubular Necrosis.

Kidney perfusion studies can be used to differentiate normal and pathology in kidney function. Baseline shows the normal kidney. Dysfunction is seen with impaired excretion and decreased collecting system enhancement.



Dr. Arne Reykowski, one of the guiding lights within Siemens MR in creating the Total Imaging Matrix coil technology, summarized the process of innovation dedicated to this coil system - from requirement engineering right through to the realization of Tim, the most advanced coil technology in MR systems today.

Total number of requirements: > 400!

There were three basic requirements that created the fundamental building stones of the Tim technology.

ELH231 Local Coils:

Posterior coils (Spine, lower parts Head and Neck) shall remain on the table when using basic coils

ELH557 Local Coils:

Head-, Neck-, Body-, Spine- and Peripheral Angio Coil shall support parallel imaging techniques as well as a scalable RF system architecture

ELH294 Patient Table:

Whole Body Coverage A patient table has to be developed that covers ≥ 190 cm (Final Version: 205 cm)

IPAT™ Integrated Panoramic Array

- Reduced patient setup times
- Almost all coils can be combined (LEGO® principle, build your own coil)
- Unique feature for MAGNETOM Harmony/Sonata

ELH231 Local Coils:

Posterior coils (Spine, lower parts Head and Neck) shall remain on the table when using basic coils

One of the answers was already available by Siemens: IPAT™

Whole Body Imaging

- MAGNETOM Avanto allows whole body imaging without patient repositioning
- Increased patient table movement range necessary
- Applications:
 - Metastasis search
 - Angiography

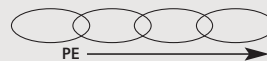
ELH294 Patient Table:

Whole Body Coverage A patient table has to be developed that covers ≥ 190 cm (Final Version: 205 cm)

Parallel Imaging Before Tim™

iPAT integrated Parallel Acquisition Technique

- SENSE, SMASH, GRAPPA, ...
- Reduction of acquisition time by knowledge of coil sensitivity profile
- Coil array must have several elements in phase-encoding (PE) direction



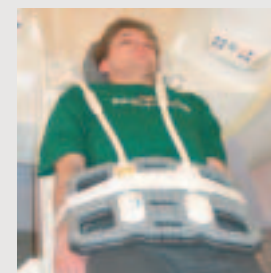ELH557 Local Coils:

Head-, Neck-, Body-, Spine- and Peripheral Angio Coil shall support parallel imaging techniques as well as a scalable RF system architecture

Parallel imaging was supported by MAGNETOM Symphony, Harmony and Sonata. The technological developments pushed for more channels and flexibility to use iPAT in different phase encoding directions and for all available applications. There was also need for a concept that would allow the use of the coils for iPAT imaging and when needed also for conventional imaging.

8 Channel Head Array

2 x 6 Channel Body Array

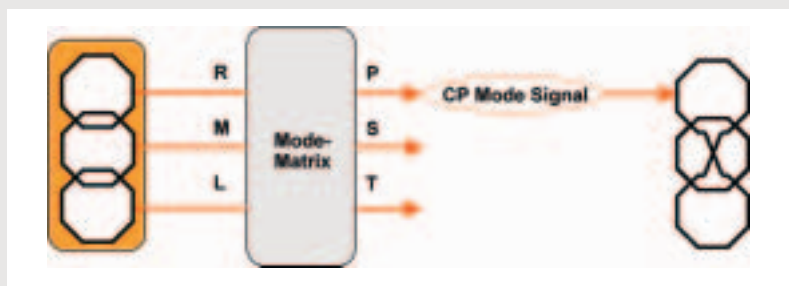


Dedicated iPAT coils for MAGNETOM Symphony and Sonata.

ELH557 Local Coils:

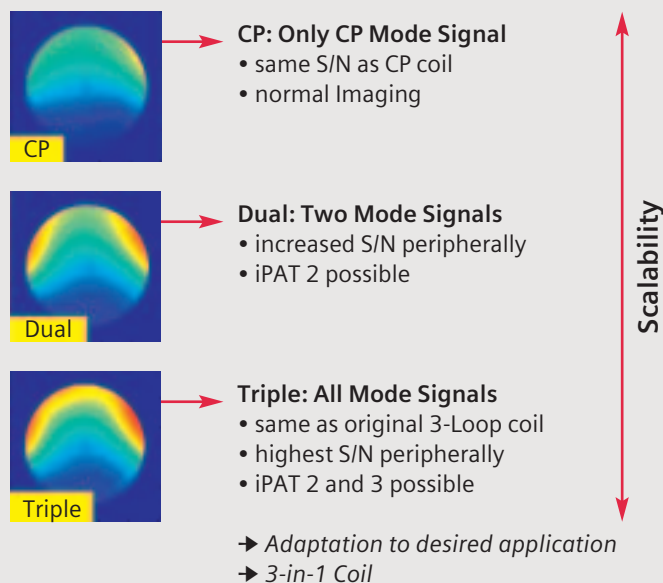
Head-, Neck-, Body-, Spine- and Peripheral Angio Coil shall support parallel imaging techniques as well as a scalable RF system architecture

Reorganizing The Signals Without Loss Of Information



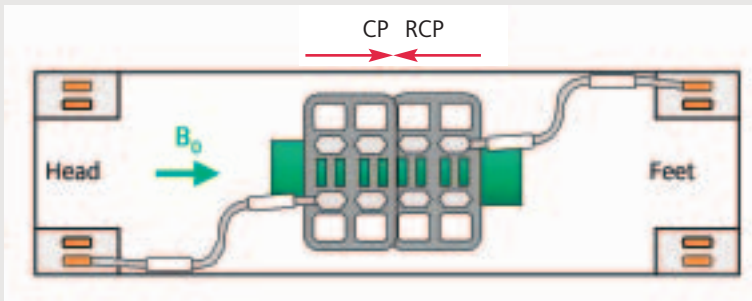
Scalability with the mode concept...
Either parallel imaging or CP imaging is possible with the Tim technology where you might adapt the coil elements according to the clinical imaging needs. The signals are reorganized without loss of information.

Mode Concept




Whole Body Imaging Challenge:

What happens when you rotate a CP coil by 180°?



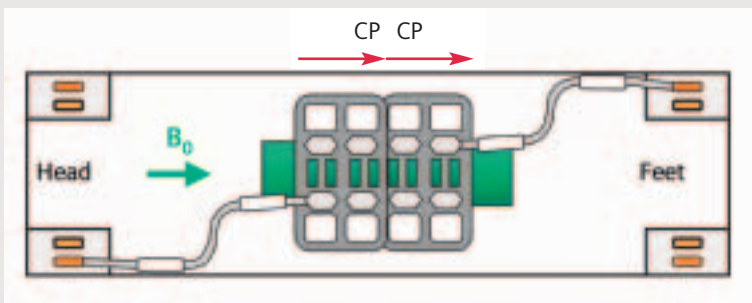
The challenge in whole body imaging was when you rotate a standard CP coil 180 degrees, you lose signal. The CP direction has to match the direction of the B_0 field.




Reverse CP signal with minimum SNR at center!

Whole Body Imaging Solution:

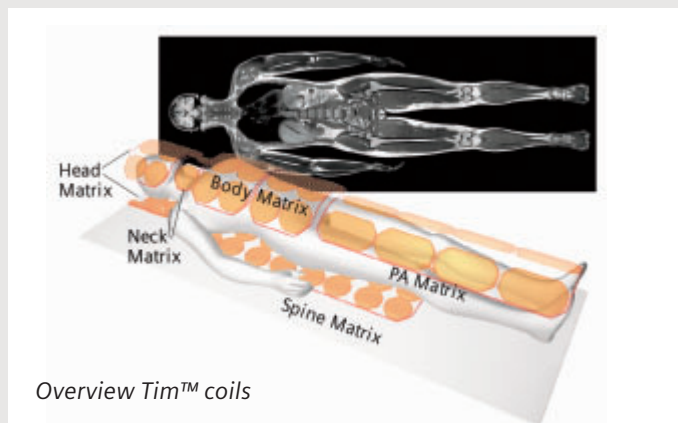

Integrated B_0 Field Sensor?



So as a solution the CP direction was rotated with the coil which provided the maximum signal.




CP signal with maximum SNR at center.



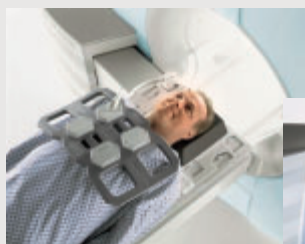Spine Matrix

- Whole Body exam
- Imaging range 110 cm
- 8 iPAT Elements x 3 = 24 channels
- 4/8/12 modes (x2)



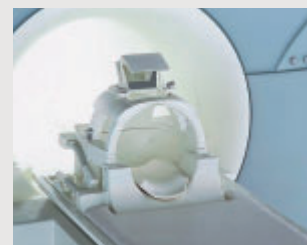
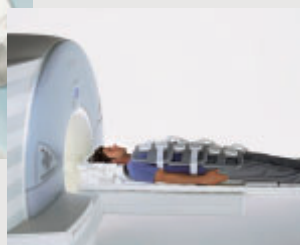Body Matrix

- CP direction switchable
- 4 to 6 iPAT elements are necessary for whole body exam
- 2/4/6 modes



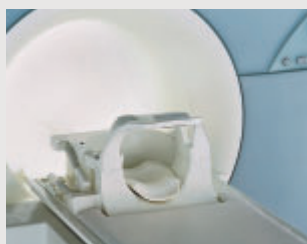Head Matrix

- 12 element coil
- 2 x 6 elements
- Elements organized in 2 rings stacked in head-feet direction
- Oval
- iPAT in all 3 orientations
- 4/8/12 modes

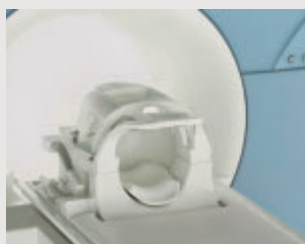

Neck Matrix

- 2 Coil Elements in shaped lower part
- 2 Coil Elements in rigid upper part
- 2/4 modes

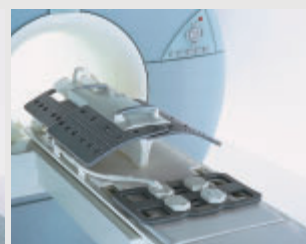



Head & Neck Matrix



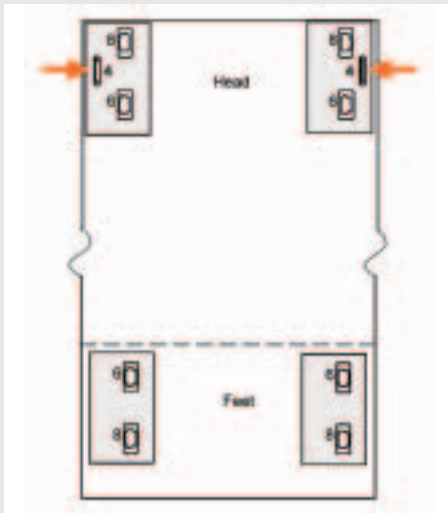
Peripheral Angio Matrix

- Similar to PAA from MAGNETOM Symphony
But:
- CP direction switchable (head first and feet first)
 - One cable only



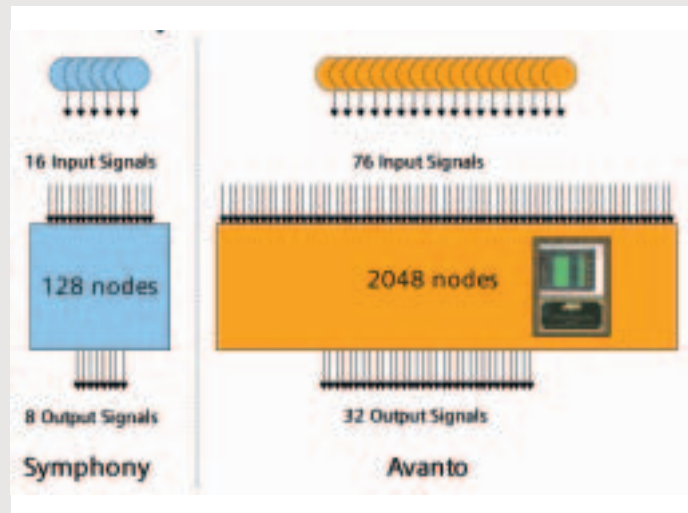
Consequences: Plugs

- 76 coil elements can be plugged in (MAGNETOM Symphony: 16)
- Plugs at head and feet side of the patient table




- The increased number of coil elements (76 instead of 16), led to an increase in the number of coil plugs (10 instead of 4) and also an increase in the number of signals per plug (up to 8 instead of 4).
- For whole body scanning plugs are located at head and feet side of the patient table.

Consequences: RF Infrastructure



- The RF switching matrix (a unique component in Siemens Systems since Symphony) which allows a totally free selection of coil elements fed towards the receivers, had to be drastically increased. The new switching matrix has a total of 2048 switching nodes as compared to only 128 in the Symphony.



Consequences: RF infrastructure

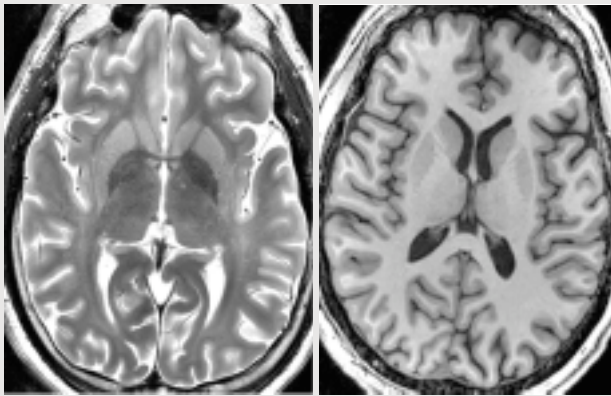

MENTOR GRAPHICS PCB Technology
Leadership Award 2004.

The RF infrastructure needed to adapt to the increased number of channels while keeping it IPA™ compatible with MAGNETOM Avanto. The creative solution to this complex problem was a board containing 22,000 discrete components. It has justifiably earned Siemens Medical Solutions the MENTOR GRAPHICS PCB Technology Leadership Award.



32 channels is the limit of MR technology today, thanks to the Total Imaging Matrix product within MAGNETOM Avanto. Dr. Wald, from the Massachusetts General Hospital (MGH) – one of the closest cooperation partners of Siemens – revealed his vision of the future of the RF technology in which a total of 128 channels could easily be reached. He also showed various image examples from different multi array coils that the MGH is currently working on for the 1.5T, 3T and 7T systems.

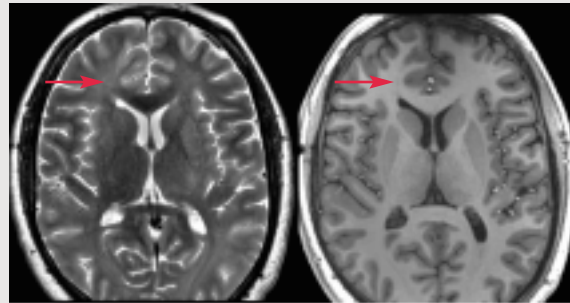
8 channel array coil built for 3T systems



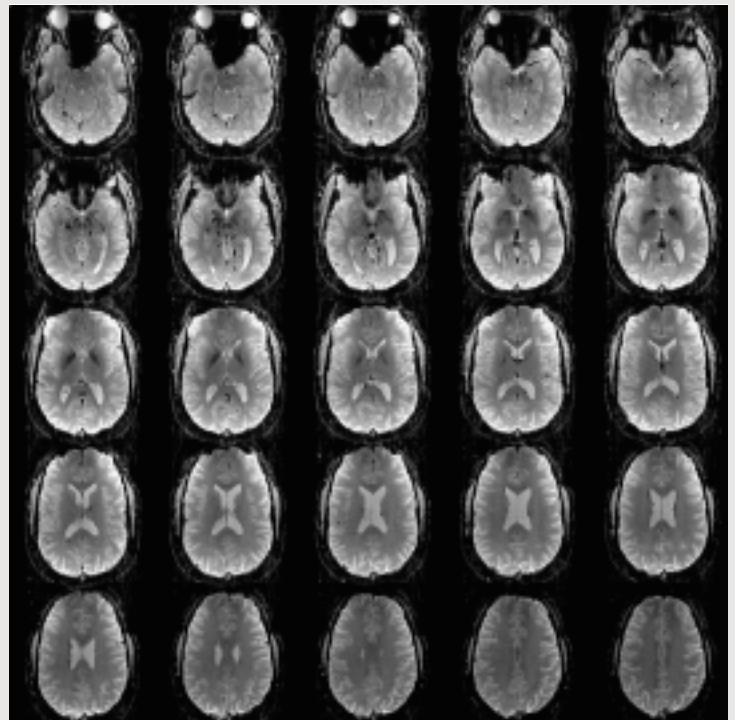
T2 TSE, 15 echoes, TR/TE = 6180/97, 400 μ m resolution, 3 mm slice, time acq = 7:25 min

T1 MPRAGE, TI/ TR/TE/flip = 1100/2530/3.3/7, 1.3 x 1 x 1.3 mm, time acq = 8 min


3T images with the MGH developed 8-channel array coil.



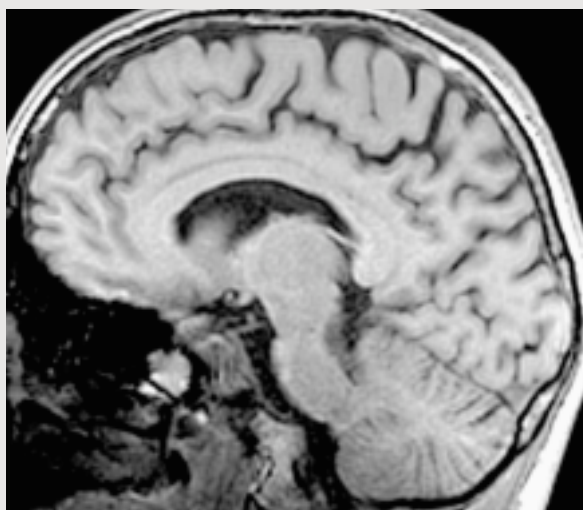
Subtle pathologies are seen easily with 3 Tesla.
Diagnosis: transmantle dysplasia.



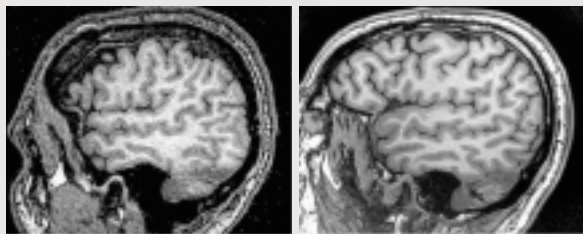
The first results with 23 channel array coil*



23 channel array coil system being developed for 1.5T systems by MGH.



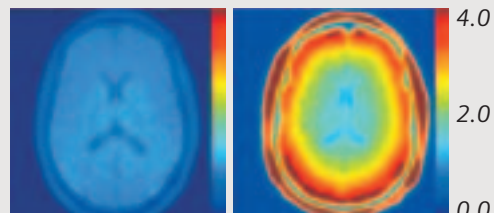
9 minute scan down to 1 minute with 23 channel array coil. 9 fold GRAPPA acceleration.
3D Flash, 1 mm x 1 mm x 1.5 mm, 256 x 256 x 128



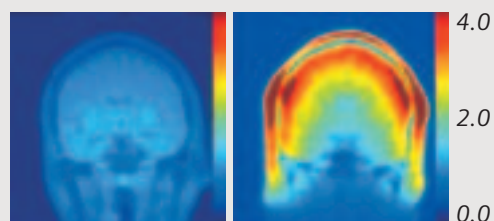
volume coil 23 channel bucky coil
1.5T, 1 mm isotropic 3D MPRAGE, TA = 8:32 min,
TI/TR/TE/flip = 1000 ms/2000 ms/2.8 ms/10°,
BW = 260 Hz/px

SNR Maps
Grad. Echo

Normalized to
volume coil
average (= 1.0)



SNR gain:
4 fold in cortex
1.75x in corpus
callosum



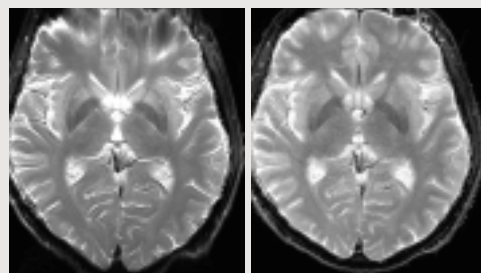
Volume coil 23 channel array

SNR maps for 23 channel array coil.

23 channel array
at 1.5T

4 x GRAPPA Accel.

Single shot EPI,
256 x 256,
230 mm FoV
TE = 78 ms

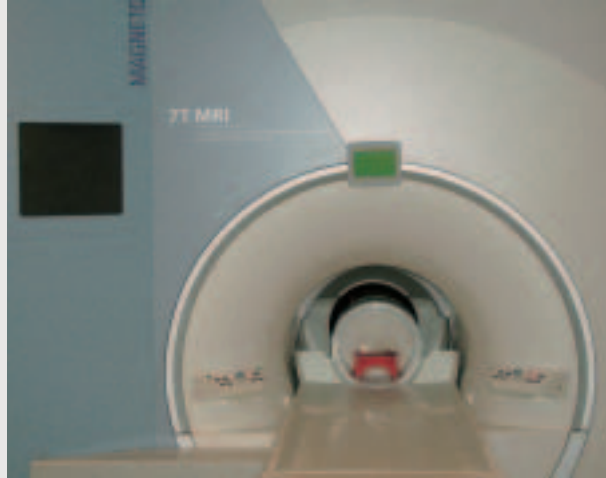


Volume coil 23 channel coil

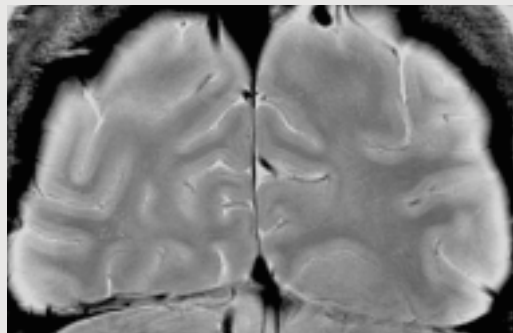
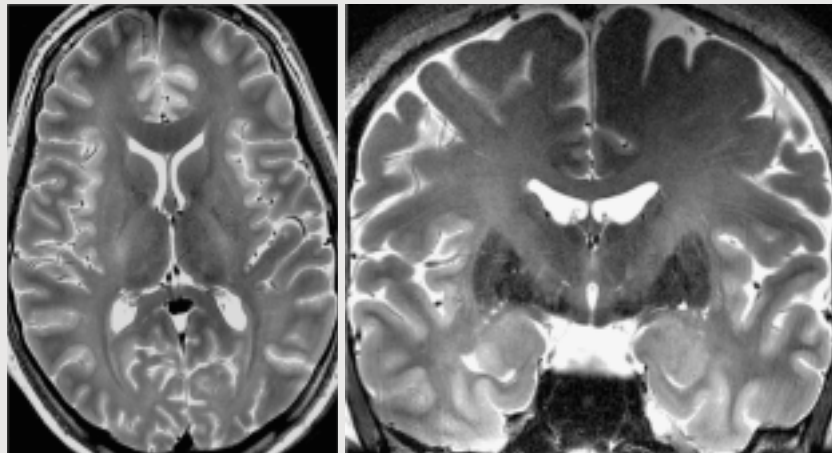
Less distortion in images resulting from EPI sequences with
23 channel array coil and factor 4.

*WIP: The information about this product is preliminary. The product is under development and is not commercially available in the U.S., and its future availability cannot be assured.

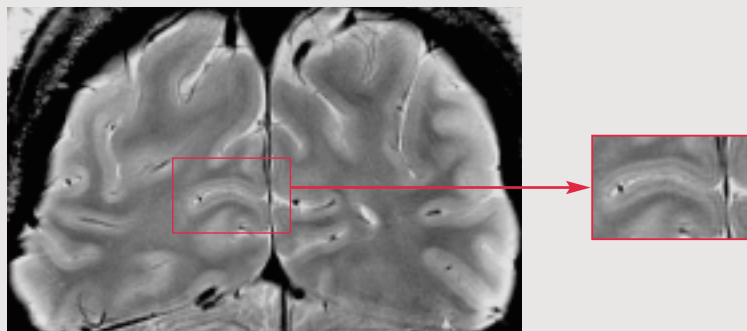
Parallel acquisitions at 7T*



*TR = 5210, TE = 80, Flip = 137,
0.5 x 0.5 x 2 mm voxels,
5 minute scan.*



*2D PD-weighted
TSE (11 echoes)
7 Minute acquisition
0.3 mm x 0.3 mm x 2 mm.*

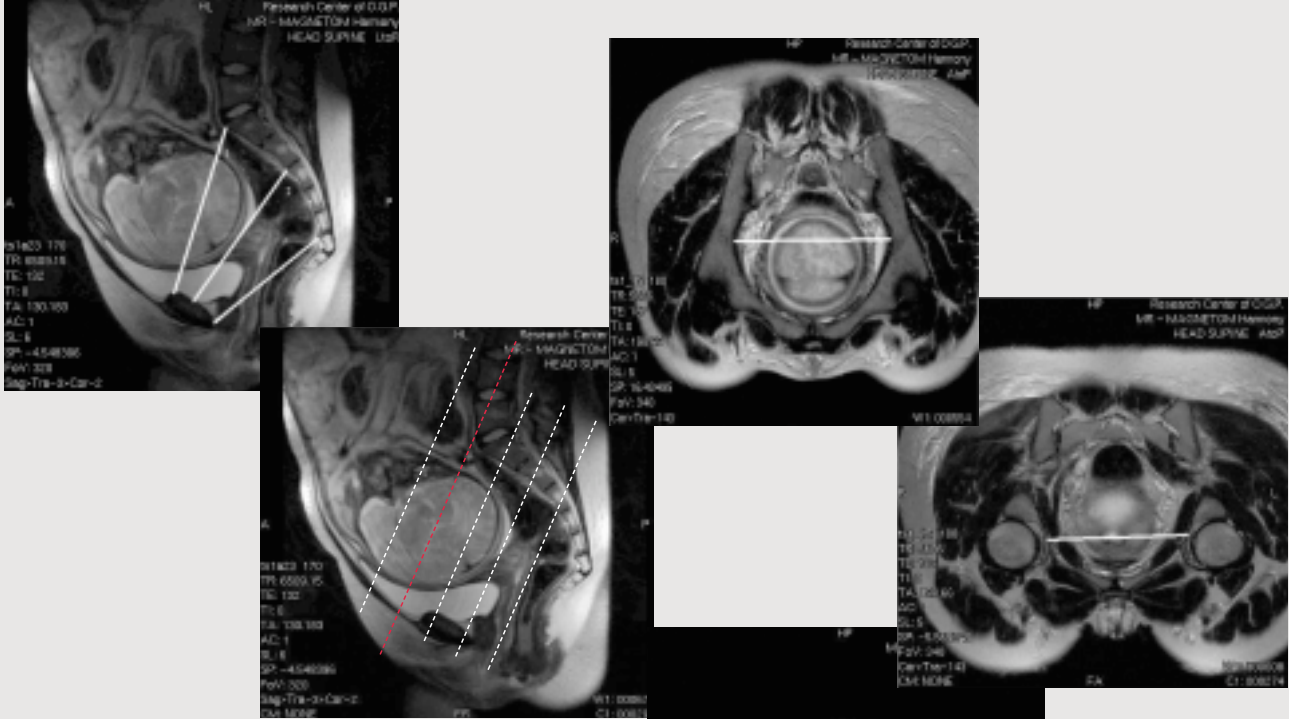


**WIP: The information about this product is preliminary. The product is under development and is not commercially available in the U.S., and its future availability cannot be assured.*

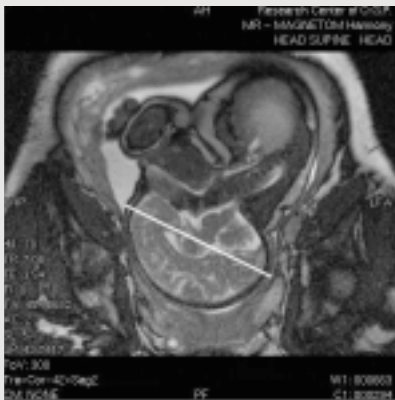High resolution TSE images from 8 channel array coil developed for 7T.



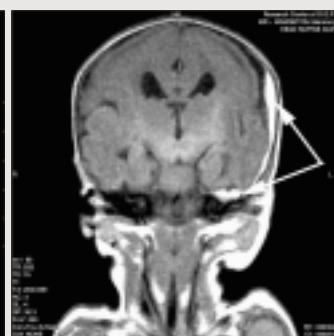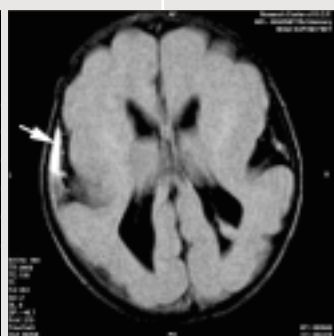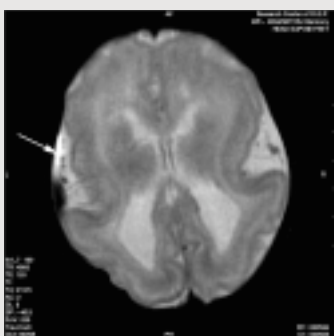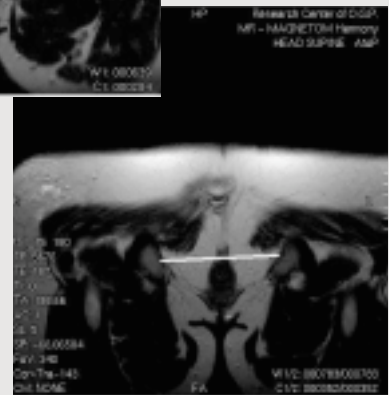
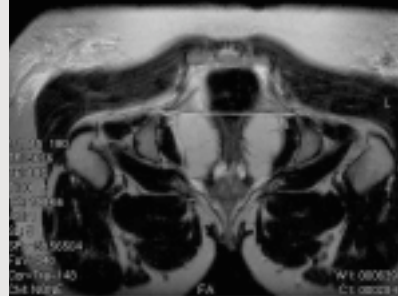
Dr. Panov, from the Russian Academy of Medical Sciences, began his talk with a summary of Radiology practice overall in Russia. Then he moved to the area of MR imaging in obstetrics, gynecology and perinatology. He concluded with the opinion that the time had come for a wider use of MRI in these clinical areas.



The method of MR pelvimetry...



T2-weighted TrueFISP.
MRI fetus cephalometry can be done with TrueFISP scanning.



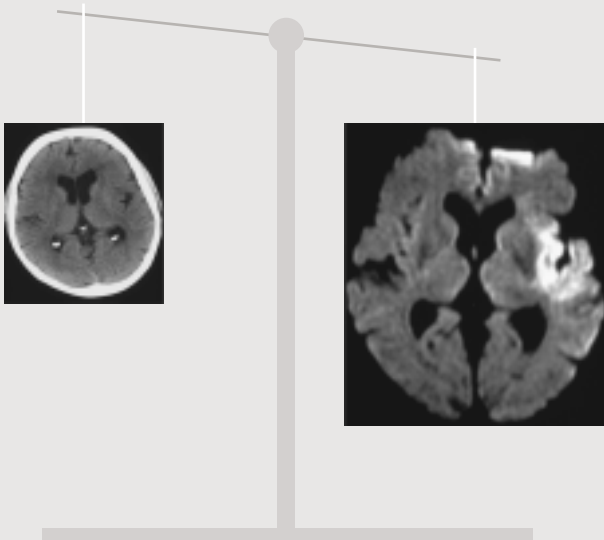
Prenatal hypoxia and birth trauma.
Brain MRI on the 7th day. Brain gray matter diffuse heterotopia and also subdural hematoma.

The safety of imaging (fetuses, infants) has not been established.

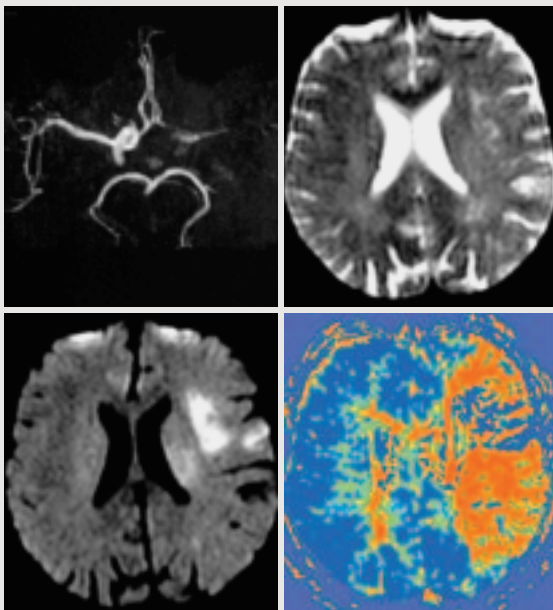


Dr. Fiebach (University Clinic of Heidelberg) compared CT to MR in the diagnosis of a hyperacute stroke and clear results showed the superiority of the MR in this area with diffusion and perfusion* imaging. Another important message he conveyed was that the latest studies showed that you did not need the CT to exclude the intracranial bleeding in a stroke patient before commencing fibrinolytic therapy, since here T2/T2*/DWI sequences would suffice for the diagnosis.

**WIP: The information about this product is preliminary. The product is under development and is not commercially available in the U.S., and its future availability cannot be assured.*

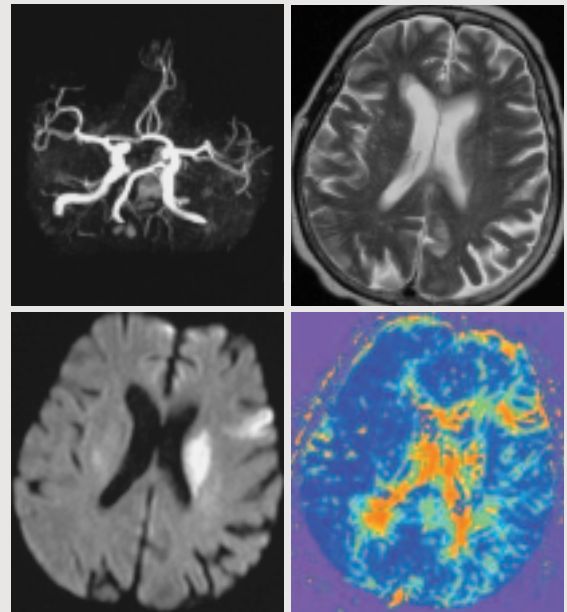


1st take home message for the audience regarding stroke imaging was that diffusion weighted MRI in ischemic stroke has increased sensitivity and accuracy compared to CT and lesion size can be estimated better than any other modality.

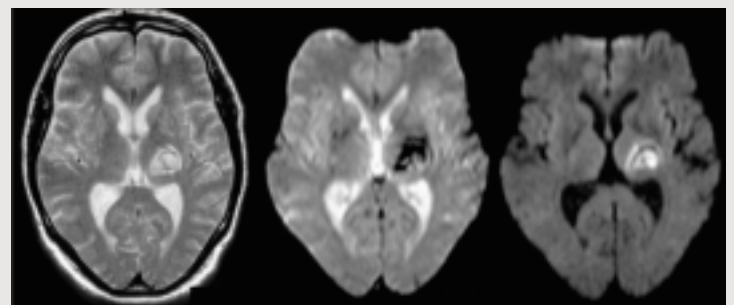


MCA occlusion – 2 minute MRA in a stroke patient showing MCA stenosis. Clearly seen infarct with DWI. The penumbra and the mismatch between perfusion and diffusion can be clearly seen.

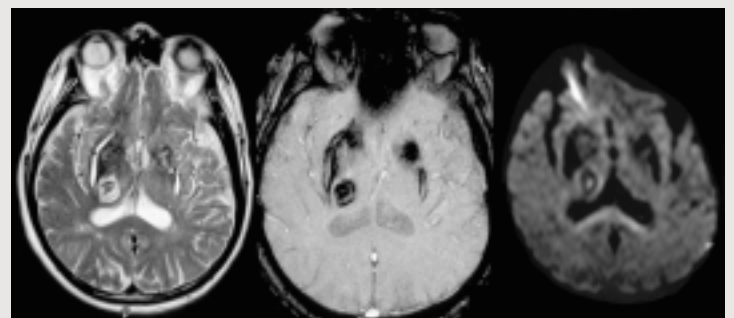
**WIP: The information about this product is preliminary. The product is under development and is not commercially available in the U.S., and its future availability cannot be assured.*



The diffusion and perfusion* match is clearly seen which makes the patient not a candidate for fibrinolytic therapy.



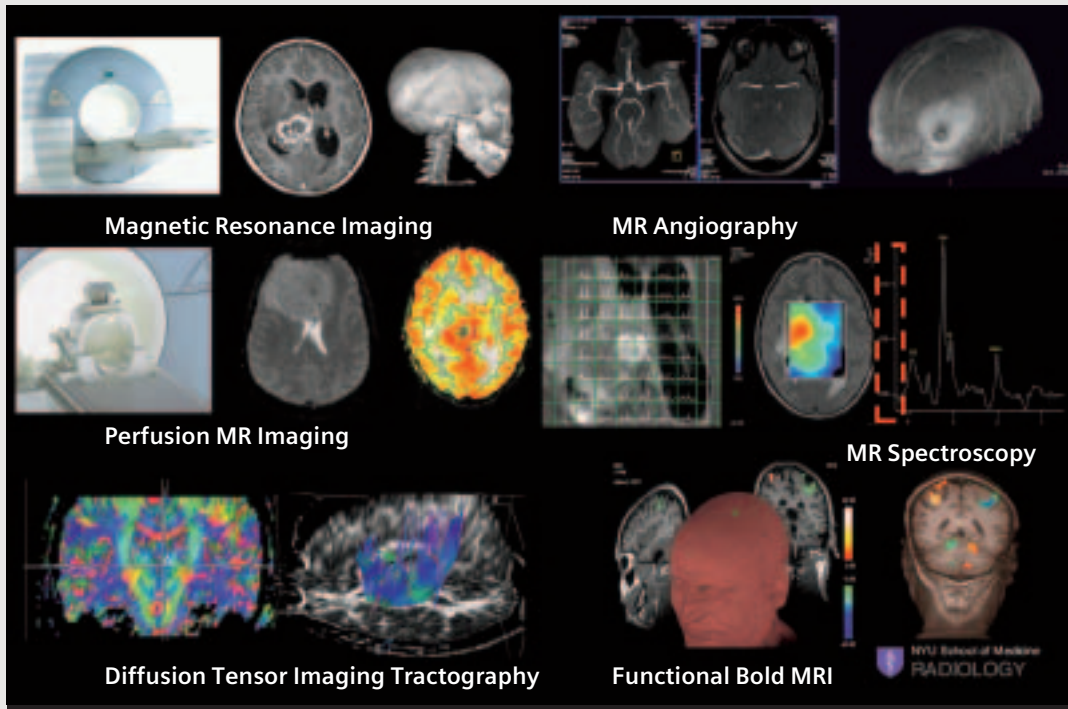
T2-w T2*-w DWI



Visualization of hemorrhage with different sequences. Dr. Fiebach's very important message to the audience was that CT was no longer needed to exclude ICH before any recanalization therapy in hyperacute stroke. It can be replaced with standard stroke MRI (T2*/T2/DWI).



The first US Tim system and its neuro MR applications... This was the exciting topic covered by Dr. Meng Law, Associate Professor of Radiology at NYU. He explained the developments and additional benefits created by MAGNETOM Avanto for routine brain-spine imaging, head & neck, brachial plexus, MRA contrast, MRA-plaque imaging, perfusion, diffusion tensor, spectroscopy, functional MR and image fusion. His comparisons of S/N increases using Total Imaging Matrix with previous 1.5 Tesla systems were striking.



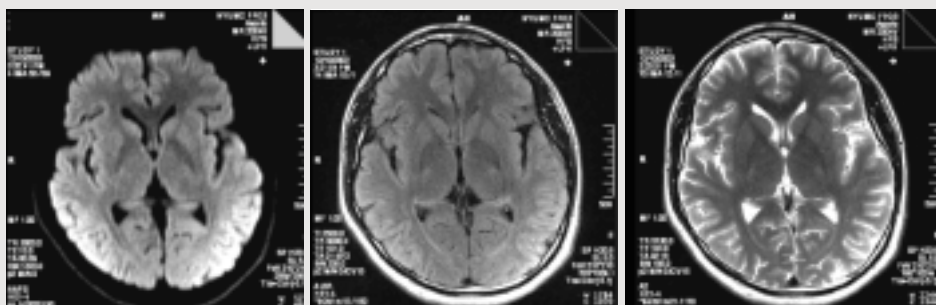
Routine neuro MR at NYU comprises of imaging, MR Angiography, Perfusion, MR Spectroscopy, Diffusion Tensor Imaging, Tractography and Functional Bold MRI.

The real advantage according to Dr. Law is that most of the sequences have doubled in matrix size and resolution from 256 to 512 and from 512 to 1024 matrix within the same scanning time of the previous systems. Spine imaging is the most prominent in terms of scan time reduction with increased resolution.

Neuro Imaging Protocol Scan Times

	Sonata/Symphony	Avanto/Tim
Routine Brain	12:14	12.30 *
NYU Tumor Protocol MRS/PWI/DWI	17:15	15.57 *
Routine Spine Protocol Sag/Axial T1 & T2	16.25	11.32 *

*On most of the sequences, matrix size and resolution x 2, iPAT x 2 with MAGNETOM Avanto

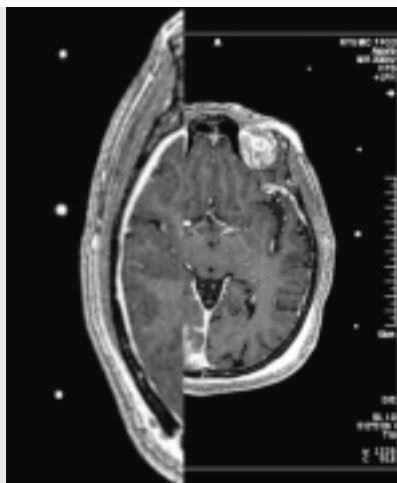

TA: 9 s

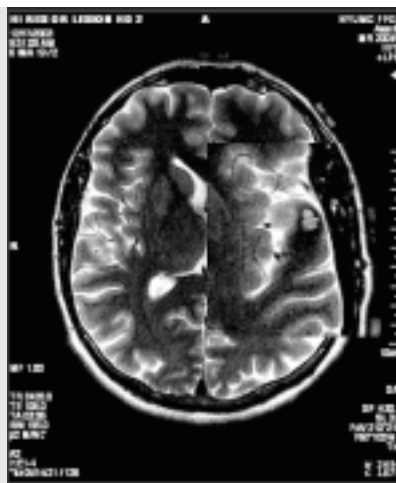TA: 2:18 s

TA: 1:48 s

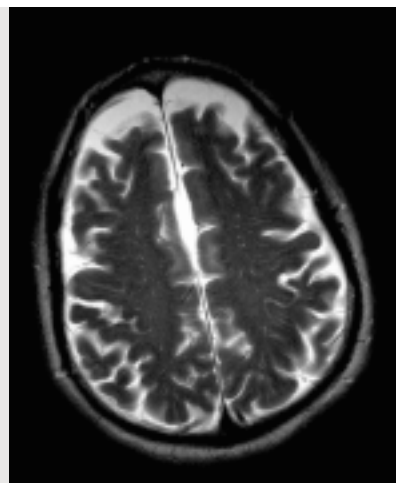
Some examples with 12 element head matrix coil.



CP Head coil used on stereotactic frame with MAGNETOM Avanto shows reduced susceptibility using iPAT. Notice the clarity of the fiducial rods.



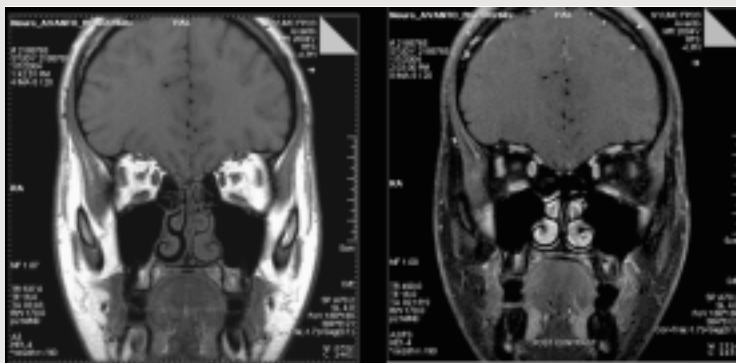
1024 matrix within 3 min scan time, increased conspicuity of the lesions with MAGNETOM Avanto compared to other 1.5T systems.



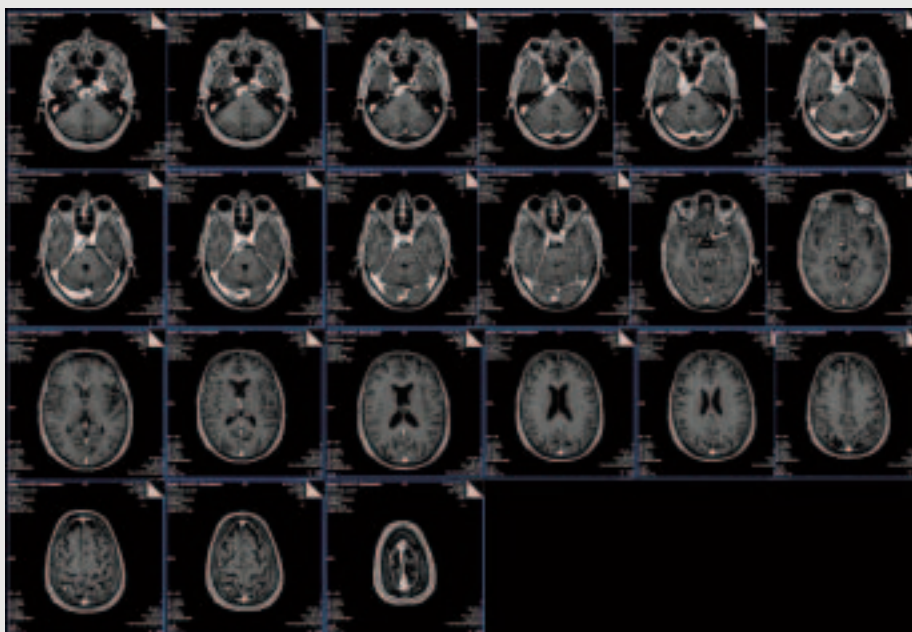
Increased conspicuity of perivascular spaces, Increased resolution, SNR, sensitivity and texture with Tim.

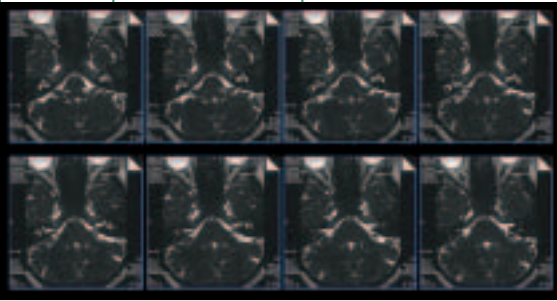
Neuro Imaging

Excellent fat saturation. Spin echo coronal head images with and without FatSat.

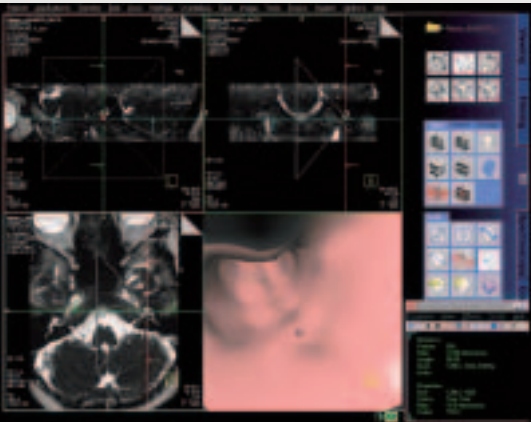


High resolution MP RAGE covering the whole head with 0.7 – 1 mm isotropic voxels within 5 minutes. Right CPA meningioma is seen.

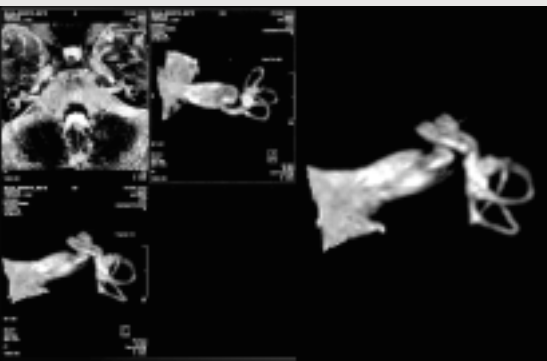




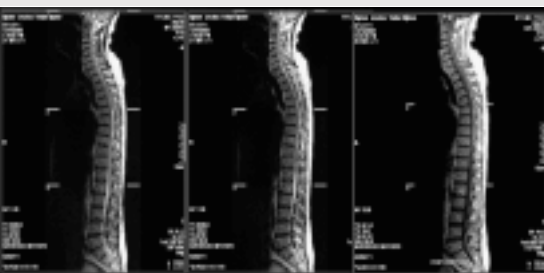
High resolution CISS images of the internal acoustic canal.



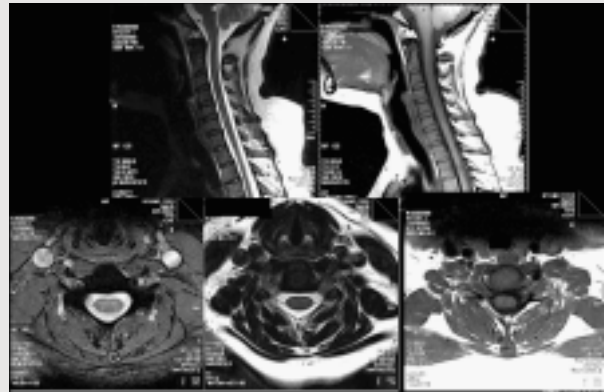
Fly through possibility through the cochlear canal to be able to show the fibrous bands.



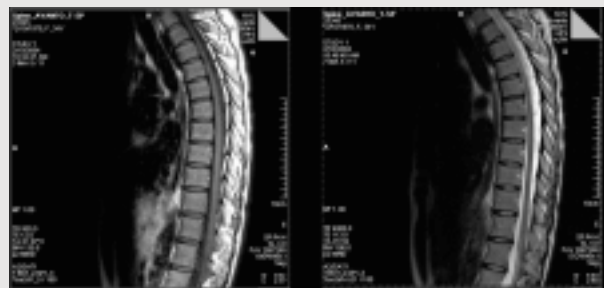MIP of internal acoustic canal demonstrates the cochlear structures and semicircular canals in detail.



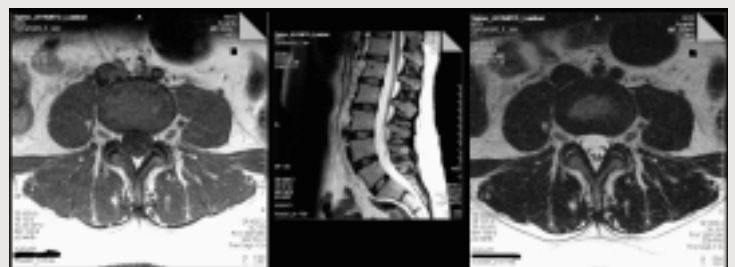
Total Spine composing for a better lesion evaluation and a PACS transfer of only total spine series saving archival space and providing radiologists with a total image which is less cumbersome than studies broken in small segments which have to be reviewed separately.



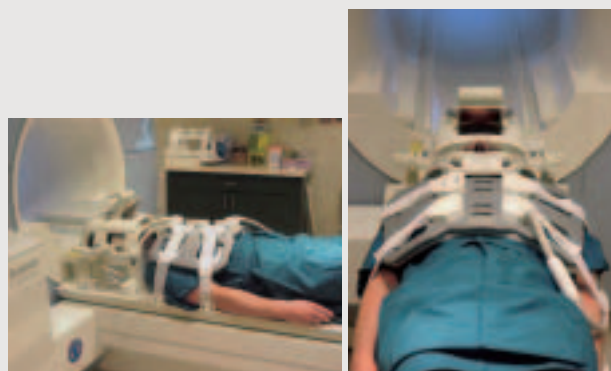
C-spine Imaging with the Neck Matrix Coil.



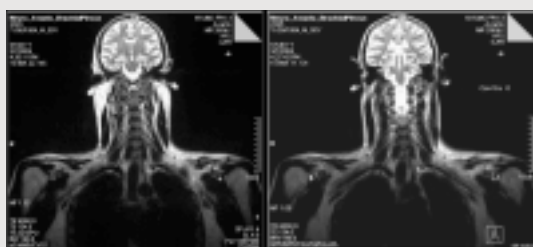
Hi-res thoracic spine imaging. T1-weighted imaging within 1 minute, T2-weighted within 1.5 min. PAT x 2 has been used in these examinations.



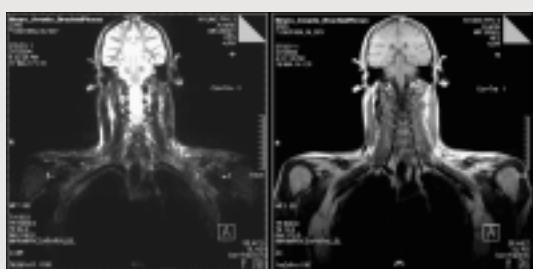
iPAT on axials is now a reality for improved scan times for difficult patients with back pain (No anterior coil is necessary). MAGNETOM Avanto is the only system which allows true parallel imaging from left to right for reduced scan times in axial imaging.



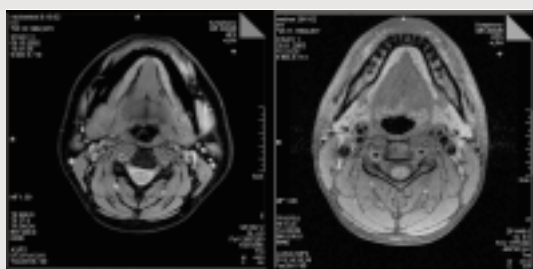
Tim technology of MAGNETOM Avanto is used for brachial plexus imaging utilizing 18-channels for a 48 cm FoV.



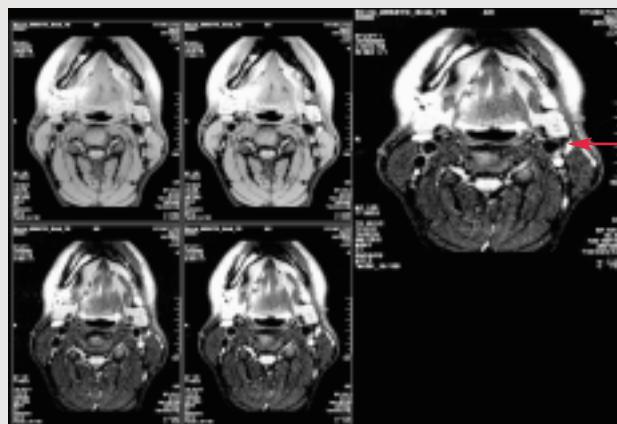
T2 TSE Coronal with MPR recons at a 48 cm FoV, iPAT factor of 3 at a 896 High resolution matrix.



STIR and T1 High resolution also acquired with PAT factor of 3 and 896 matrix without interpolation. MPR used to capture best angle of plexus.

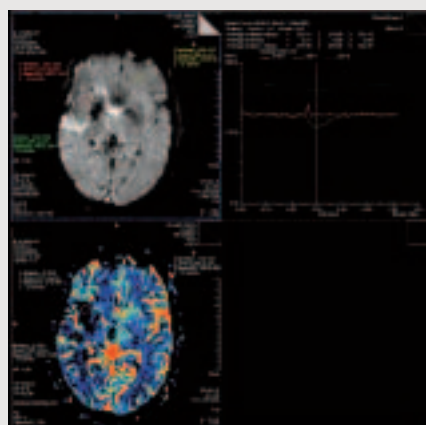


FatSat in very difficult areas like the head and neck region allows clear identification of small findings e.g. lymph nodes and metastasis.



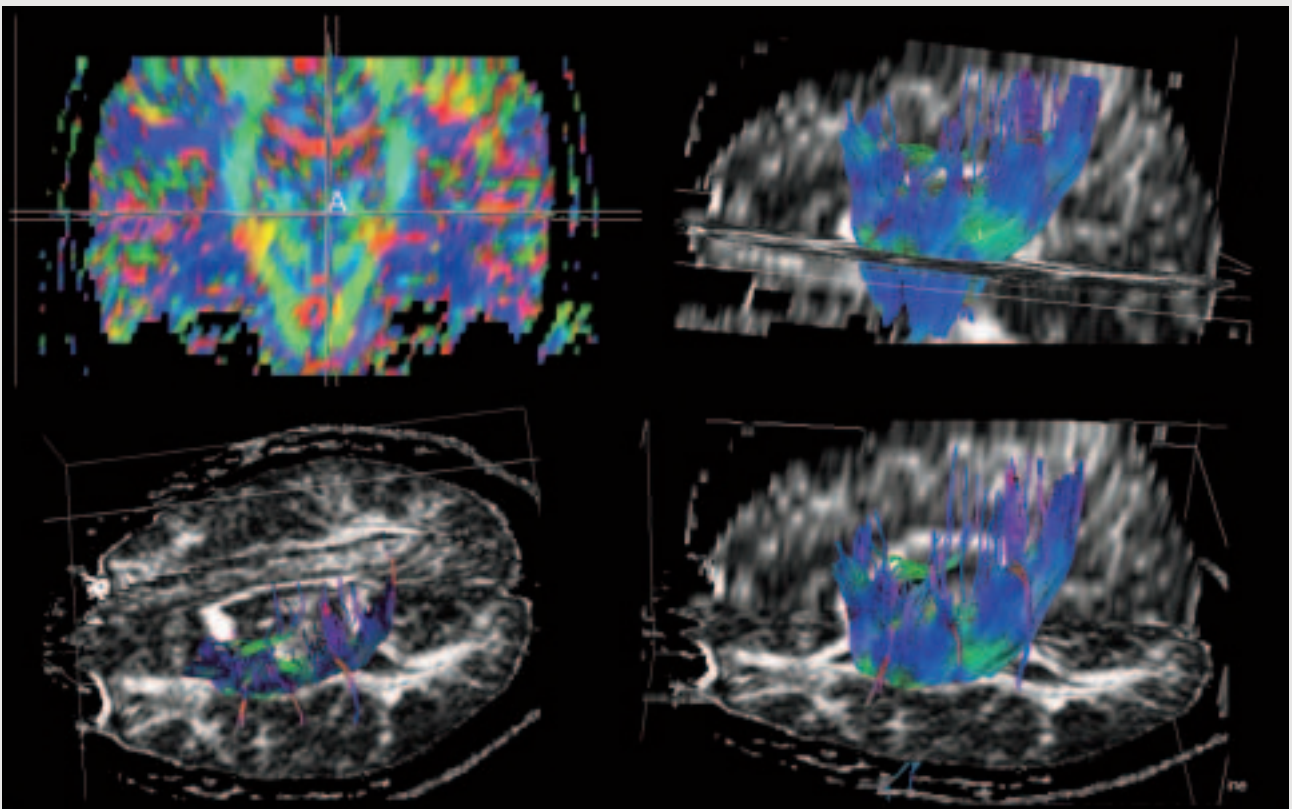
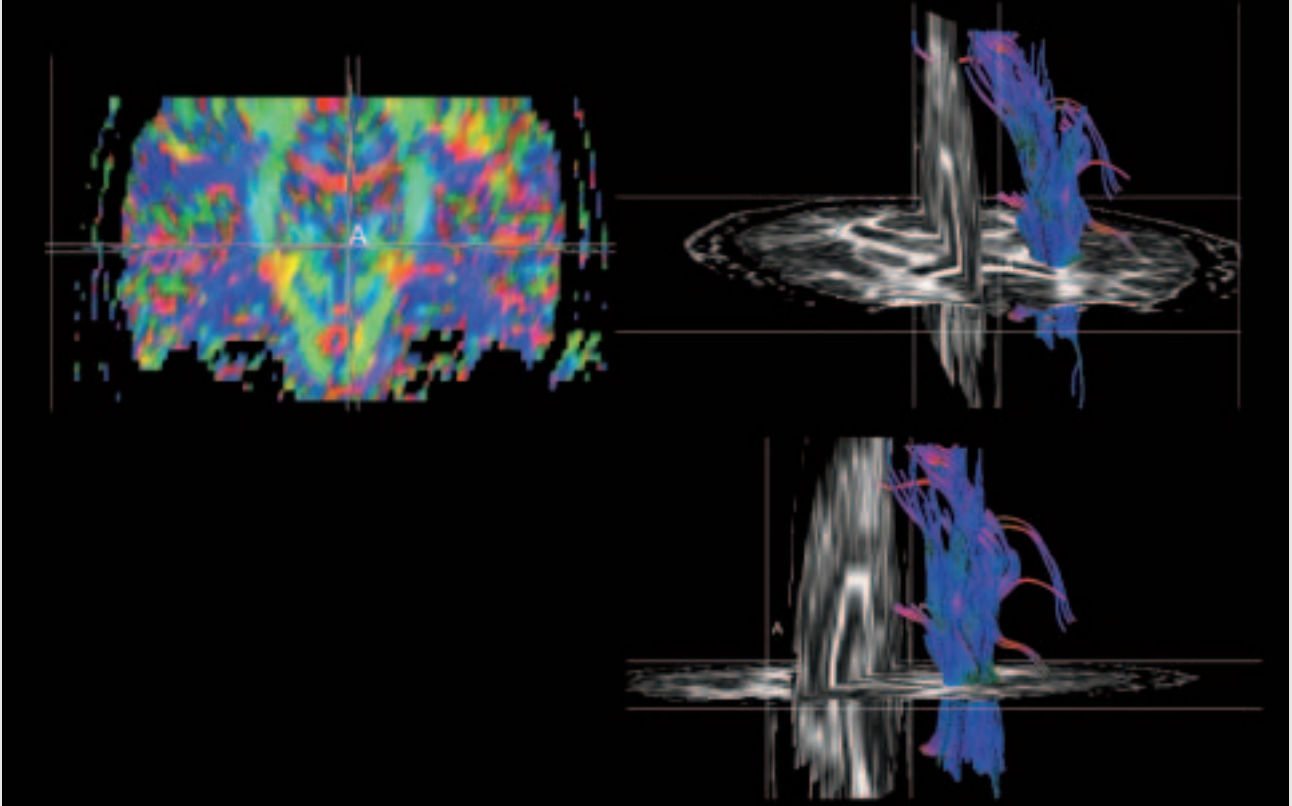
Black Blood
Carotid
Plaque
Morphologic
Imaging.

Carotid plaque imaging with dark blood sequences acquired on a MAGNETOM Avanto.



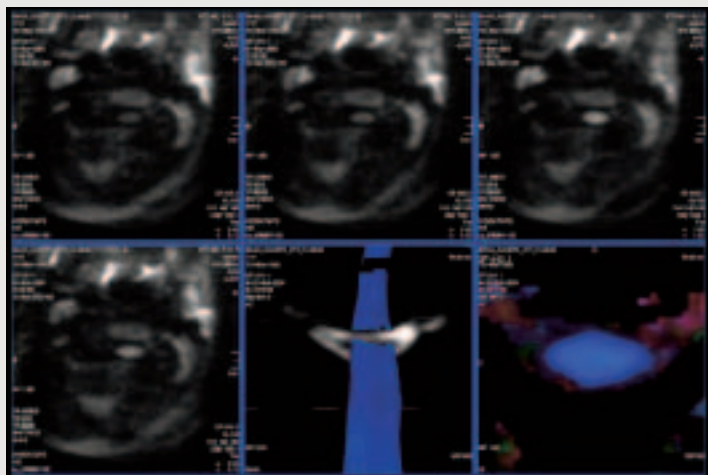
Perfusion* MR imaging with MAGNETOM Avanto.

*WIP: The information about this product is preliminary. The product is under development and is not commercially available in the U.S., and its future availability cannot be assured.

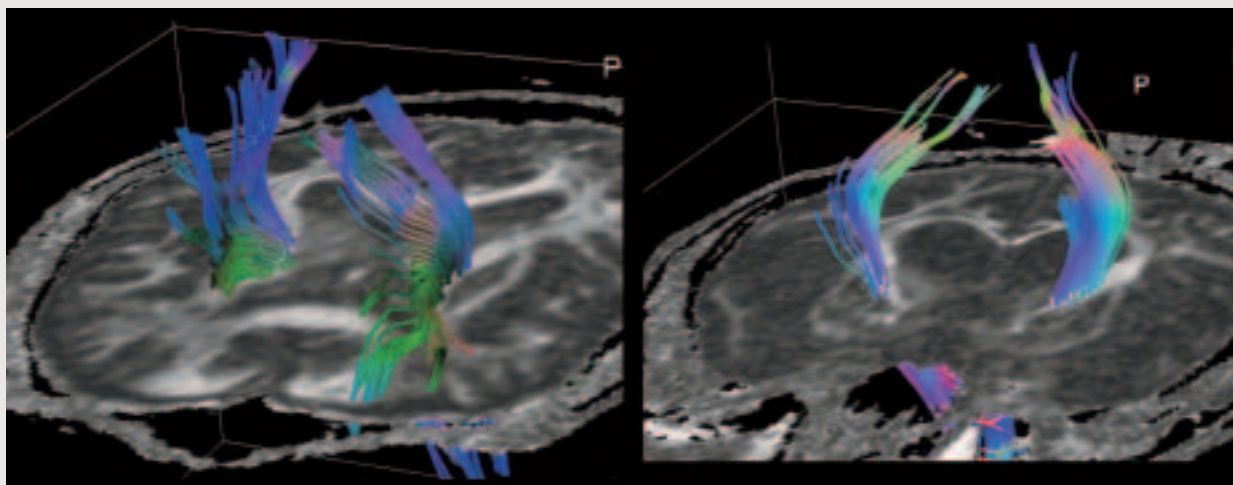


Diffusion Tensor Imaging Tractography.*

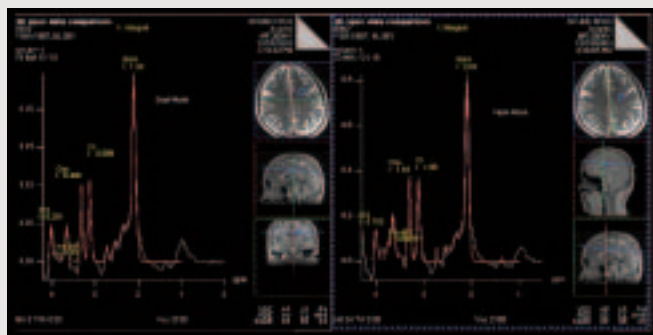
**WIP: The information about this product is preliminary. The product is under development and is not commercially available in the U.S., and its future availability cannot be assured.*



Spinal cord tractography*.



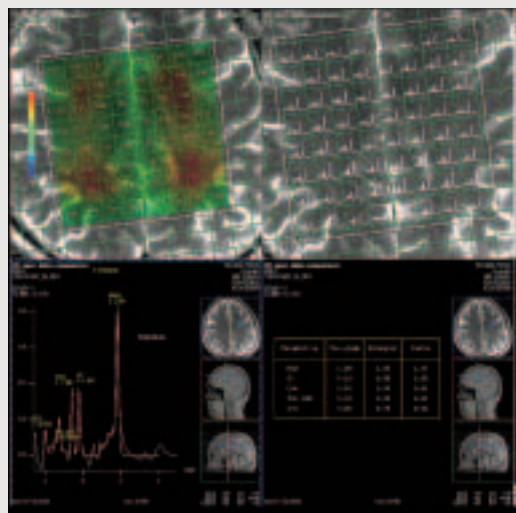
Tractography through the 20 pixel ROI in the area of maximal fractional anisotropy in the genu of the internal capsule. There is a decrease in the number of visualized fiber tracts in the patient with mild normopressure hydrocephalus (left) and severe normopressure hydrocephalus (right)*.



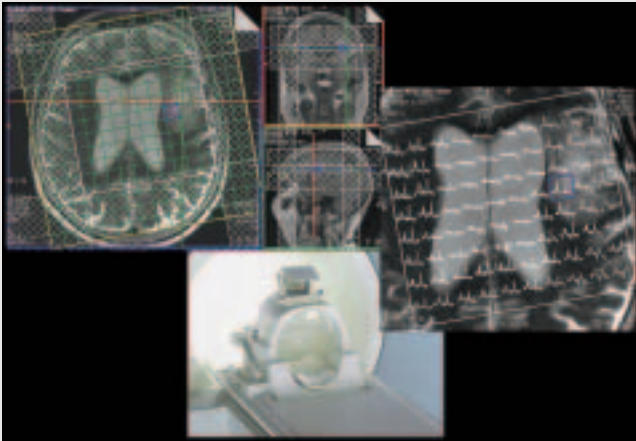
Dual Mode = 8-channel coil Triple Mode = 12-channel coil

Spectroscopy with matrix coils can decrease acquisition time.

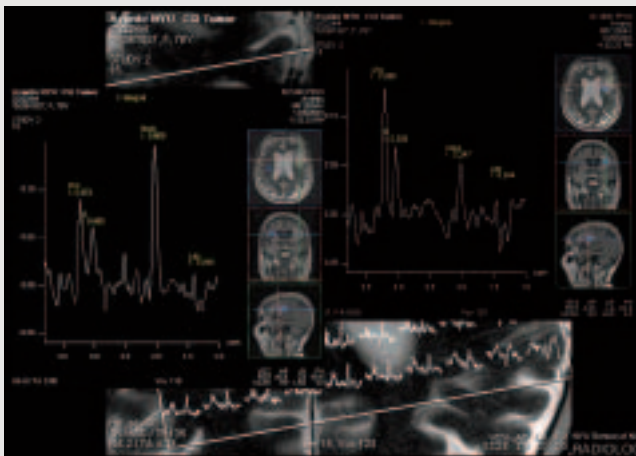
*WIP: The information about this product is preliminary. The product is under development and is not commercially available in the U.S., and its future availability cannot be assured.



Metabolite mapping.

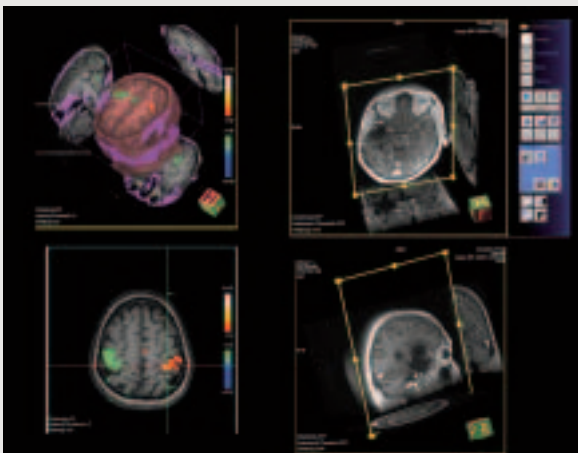


Matrix MR spectroscopy with 12-channel Head Matrix coil.
Diagnosis of a glioma.



Glioma Grading with multi-slice, multi-echo,
multi-channel MRS.

fMRI



fMRI with MAGNETOM Avanto.



Siemens –
NYU 7 Tesla*



NYU has also
received the latest
7 Tesla system
from Siemens.

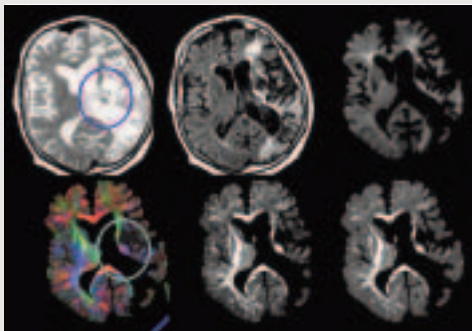
*WIP: The information about this product is preliminary. The product is under development and is not commercially available in the U.S., and its future availability cannot be assured.



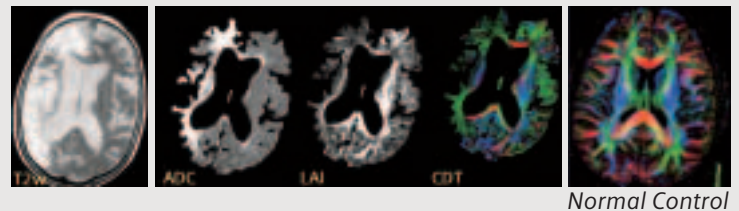
Dr. Achim Gass (Clinic of Mannheim) demonstrated the clinical possibilities for using diffusion tensor imaging and quantitative measurements of anisotropy. His topics covered cerebral ischemia, multiple sclerosis, space occupying lesions, epilepsy/developmental disorders, aging/dementia and psychiatric disorders, emphasizing the advantages of using DTI and fractional anisotropy to produce a more precise diagnosis. He also showed the developments in the area of fiber tracking.

Clinical Applications/Opportunities of DTI

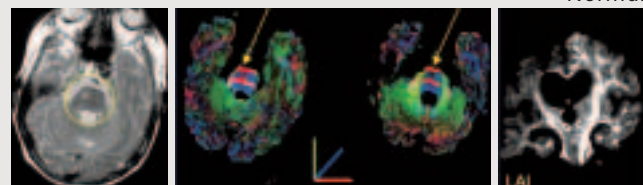
- Quantitative Tissue Characterisation (ADC, Anisotropy)
Topographical relationship of lesions (CDTI)
Structural Connectivity (Fiber tracking)
- Cerebral Ischemia
 - Multiple Sclerosis
 - Space occupying lesions
 - Epilepsy/Developmental disorders
 - Aging/Dementia
 - Psychiatric disorders



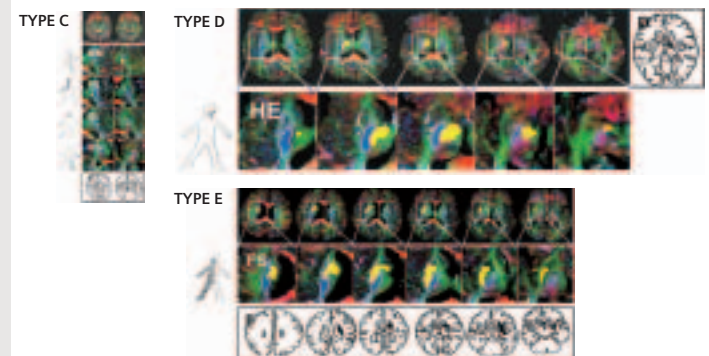
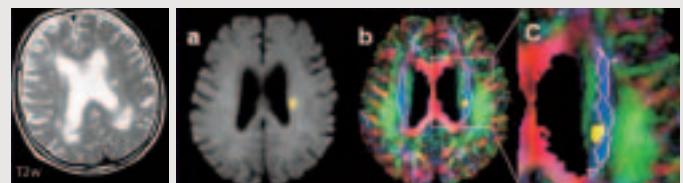
Extensive MCA Infarction – spared cortico-spinal tract fibers.



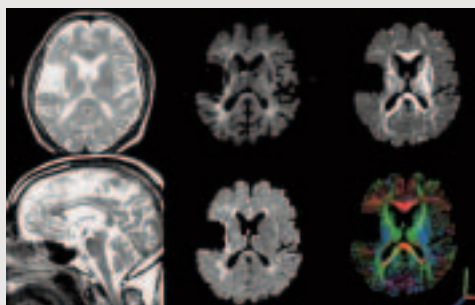
Normal Control



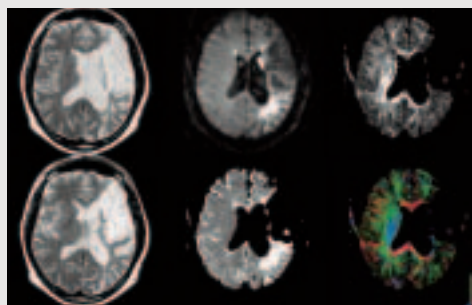
Chronic MCA infarction – Wallerian degeneration. (LAI lattice anisotropy, CDT color coded DTI).



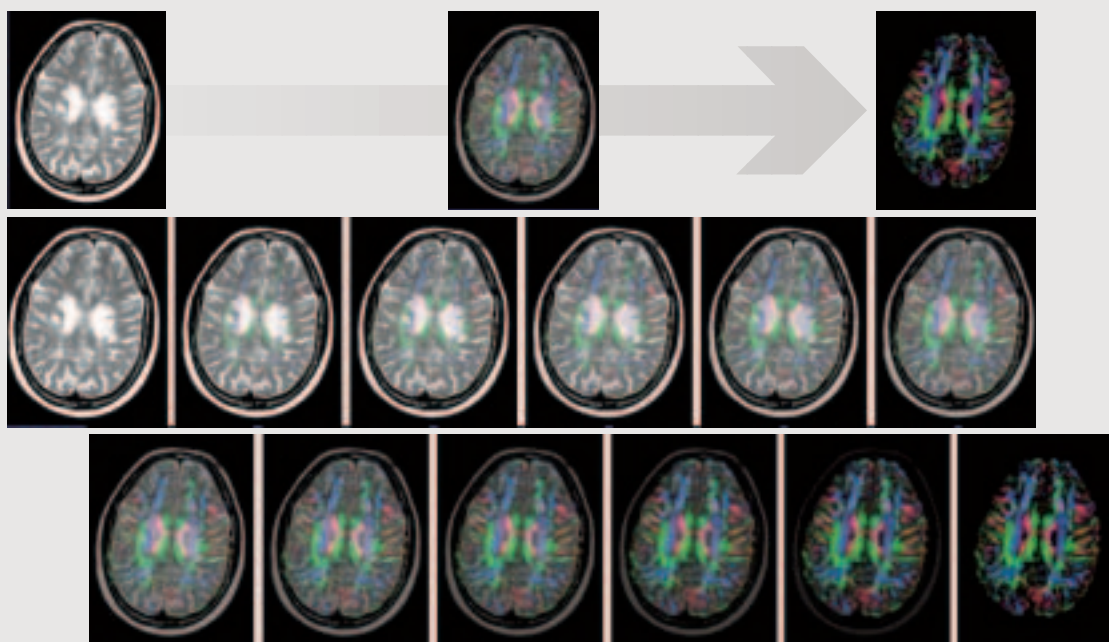
Lacunar stroke: Spared and damaged fibers and nuclear structures.



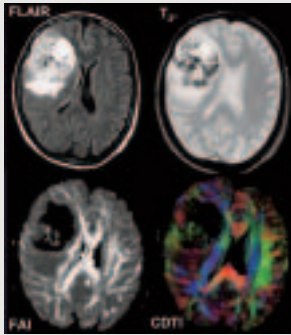
Chronic MCA infarction – locally limited tissue damage.



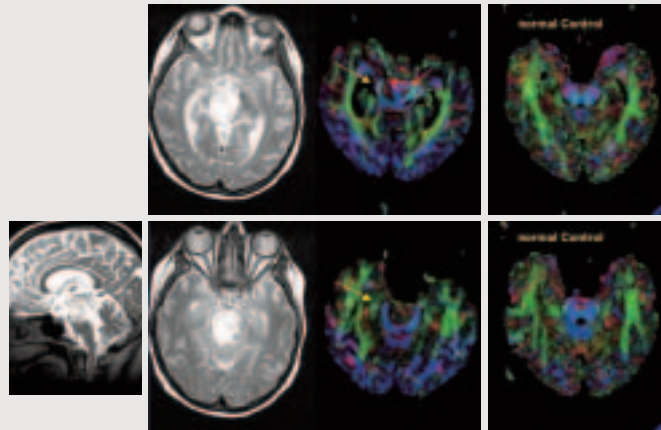
Chronic MCA infarction – improved estimation of tissue damage.



Color Coded DTI overlay in Multiple Sclerosis – combining 2 contrasts.

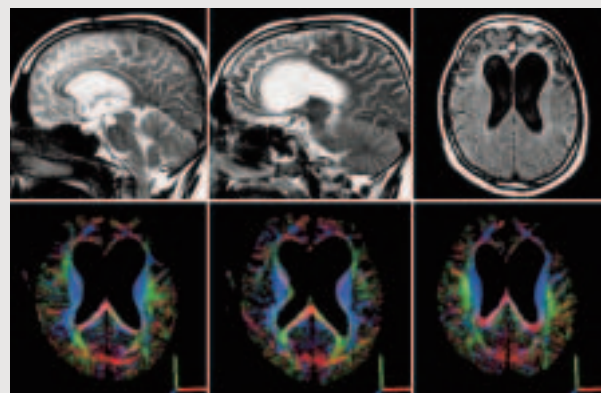
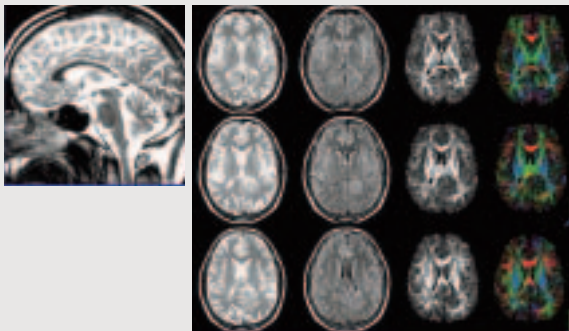


Glioblastoma, destructive-compressive growth (FAI fractional anisotropy, CDTI color coded DTI).



*Brainstem neoplasia.
Massive compressive effect on midbrain structures and fiber tracts.*

Cortical Dysplasia




Fronto-temporal dementia.

Friday, June 25, 2004



By common consent, the overall program was found very appealing, especially the first day when our collaboration partners presented the benefits of Tim and MAGNETOM Avanto.



Hands-on sessions were rated as very useful: they definitely increase the awareness of the customers to new applications. We will therefore offer more of these sessions in the future.

We hope to see MAGNETOM users worldwide gather together next year in Asia.





3rd MAGNETOM World Summit,
Group photo.



The latest news from Siemens in the area of “Ultra-High Field Imaging” was revealed to the select audience of the MAGNETOM World by Dr. Ioannis Panagiotellis, Market Segment Manager at Siemens MR. He also showed highly interesting and advanced clinical results from the Ultra High-Field community.

MAGNETOM Trio's 12 Local ¹H Coils



tx/rx Extremity



tx/rx Head



8ch. Head



tx/rx Wrist



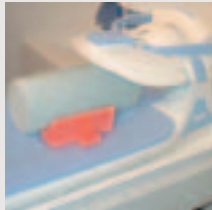8ch. Body



8ch. Cardiac




8ch. Knee



8ch. Spine



8ch. Neurovascular

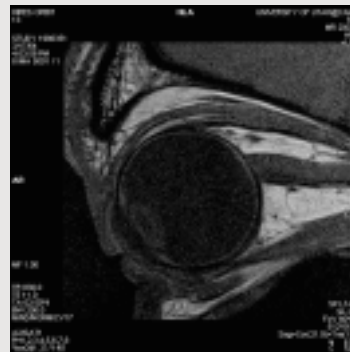

4ch. Shoulder



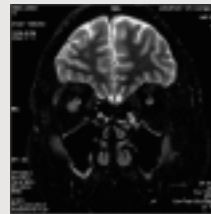
4ch. Breast

Available coils that are delivered with the MAGNETOM Trio in the year 2004.

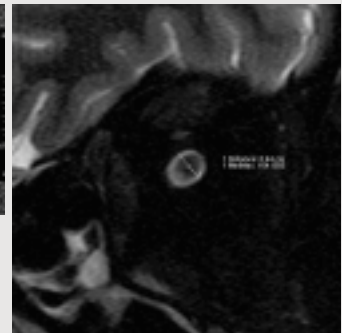


Orbit imaging.
2D TSE with
 $0.1 \times 0.1 \times 2$ mm
resolution.

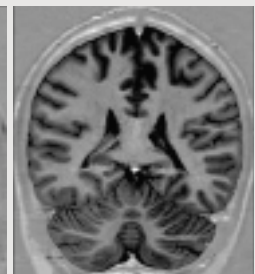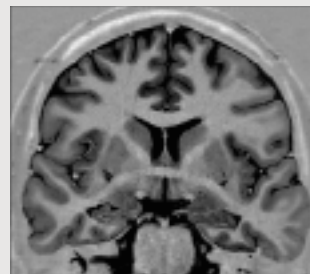
MAGNETOM Trio Quality in Brain MR



Courtesy of University
of Utah, USA

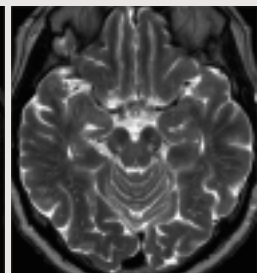
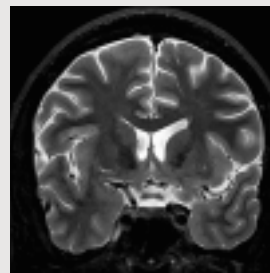


Optical nerve imaging with 2D TSE with
 $0.3 \times 0.4 \times 3$ mm resolution.



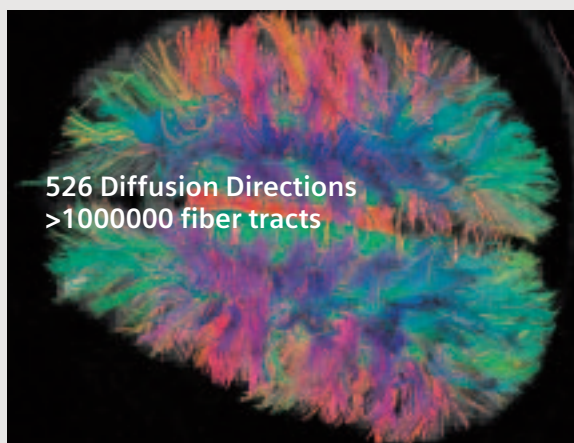
Courtesy FC Donders imaging Centre, Netherlands

Superb T1 contrast at 3T with 8-channel head-array coil.



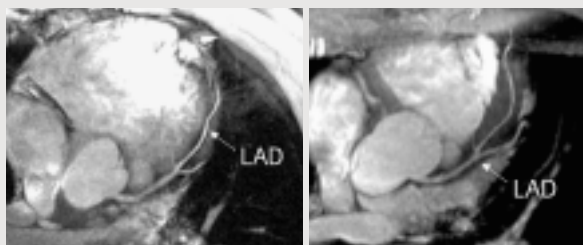
Courtesy of UCLA, USA and Universitätsklinik Frankfurt, Germany

High spatial resolution ($0.3 \times 0.4 \times 3$ mm³) T2-weighted
images within 4:16 min.



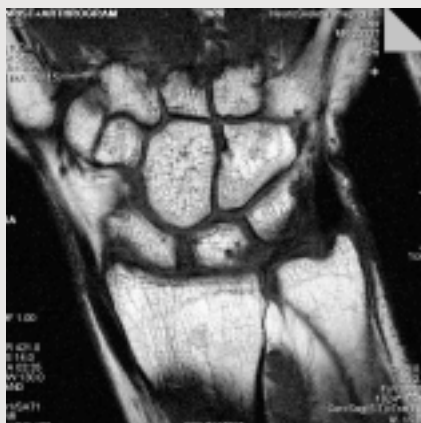Courtesy of V. Wedeen et al., MGH, USA

MR tractography* with MAGNETOM Trio...



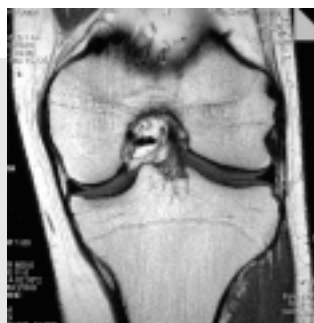Courtesy of UCLA, USA

3T TrueFISP coronary MR Angiography (breath-hold, 28 heart beats).

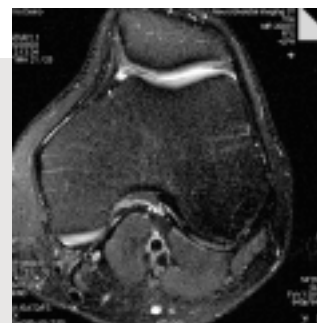


High resolution Wrist Imaging with MAGNETOM Trio.
T1_tse 0.08 x 0.08 x 2 mm³ resolution.

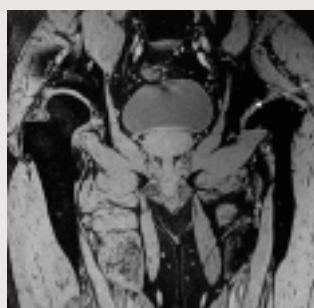*WIP: The information about this product is preliminary. The product is under development and is not commercially available in the U.S., and its future availability cannot be assured.



High resolution knee imaging with MAGNETOM Trio.
T1_TSE, Matrix = 512 interpolated to 1024;
0.3 x 0.3 x 3 mm³ resolution.

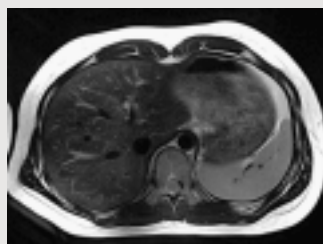


High resolution knee imaging with MAGNETOM Trio.
T2_TSE_fs, FoV = 130 mm,
0.2 x 0.2 x 3 mm³ resolution.

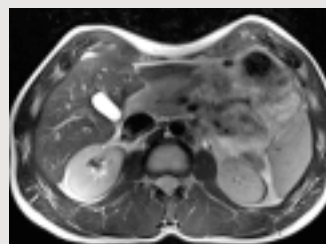


High-resolution hip joint imaging with MAGNETOM Trio. Hip dysplasia, isotropic resolution 0.6 mm³.

Courtesy of University of Erlangen, Germany

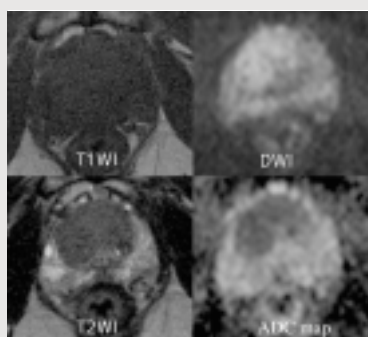


Abdominal imaging
2D TSE Hyperecho and PAT x 2
TR/TE 1900/109, 357 x 512
FoV 263 x 350, SL 6, 14 slices,
1:57 x 2 min.



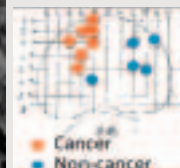
Abdominal Imaging
2D TSE Hyperecho TR/TE
1900/94, 200 x 384
FoV 270 x 350, SL 6, 20 slices,
1:04 x 2 min.

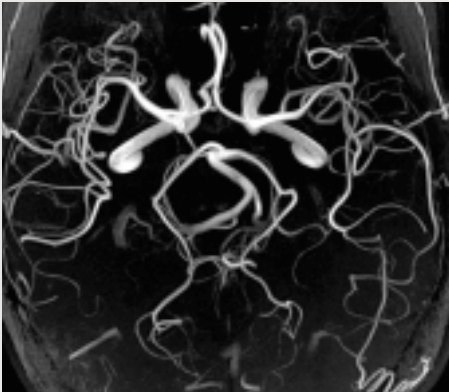
Courtesy of University of Nagoya, Japan



DWI for prostate cancer with MAGNETOM Trio. 67 year old male. PSA 8.9, Initial 6-point blind biopsy was negative.

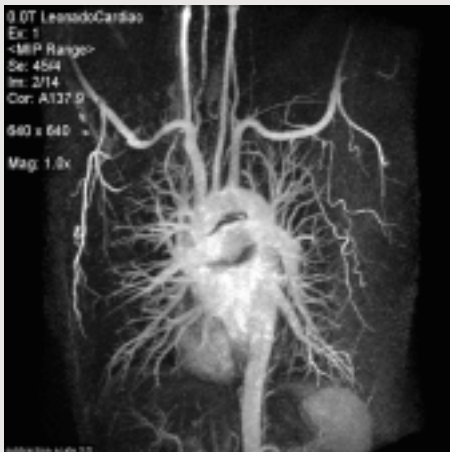Courtesy of Nagoya University Hospital, Japan





Courtesy University of Utah, USA

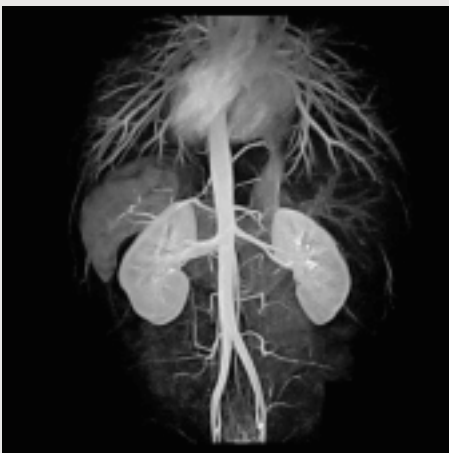High resolution ToF with MAGNETOM Trio.



Courtesy of UCLA, USA

Pulmonary ceMRA with MAGNETOM Trio

High resolution MRA $0.6 \times 0.6 \times 0.9 \text{ mm}^3$, 22 s.

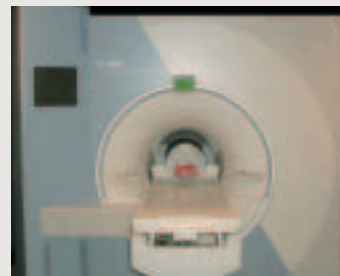

Courtesy of UCLA, USA

Abdominal ceMRA with MAGNETOM Trio

High resolution MRA $0.6 \times 0.6 \times 0.9 \text{ mm}^3$, 22 s.

MAGNETOM 7T* Community



MGH, USA

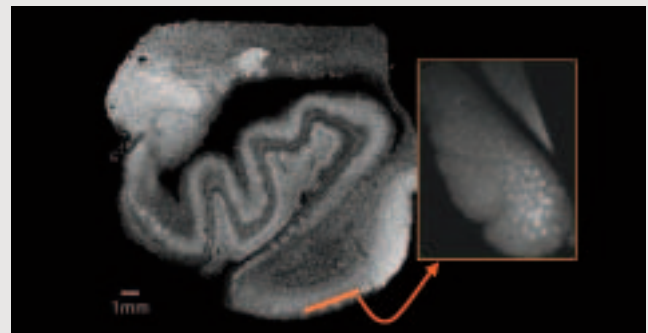


NYU, USA



Magdeburg, Germany

Entorhinal Cortex Islands



Courtesy of Fischl Martinos/MGH HST

MR image of the specimen with 7T showing information similar to histology.

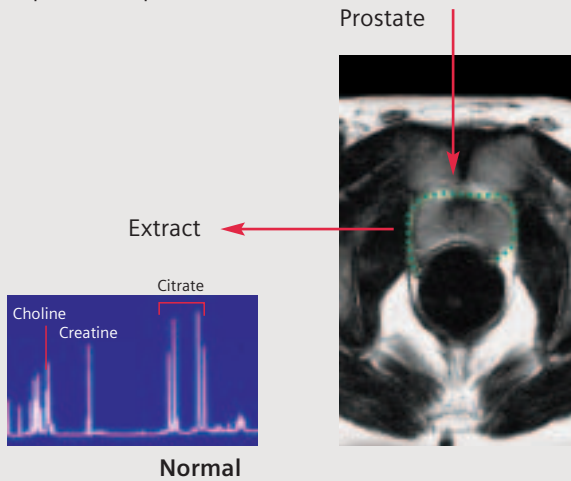
**WIP: The information about this product is preliminary. The product is under development and is not commercially available in the U.S., and its future availability cannot be assured.*



Prostate spectroscopy appears to be one of the hottest topics in the world of radiology. Prof. Dr. Heerschap from the University of Nijmegen, the Netherlands, a major collaboration partner of Siemens in the area of prostate MR spectroscopy, presented an overview of prostate MR imaging and spectroscopy ranging from current possibilities to future opportunities.

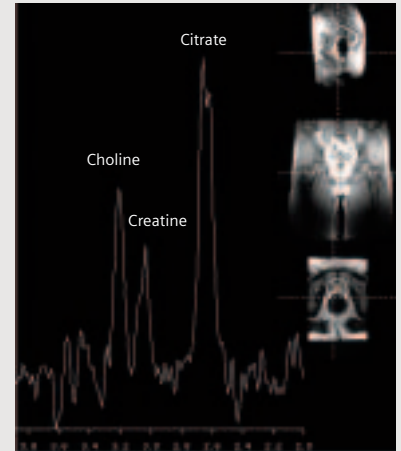
Possibilities MR spectroscopy: metabolism?

Liquid NMR spectrum

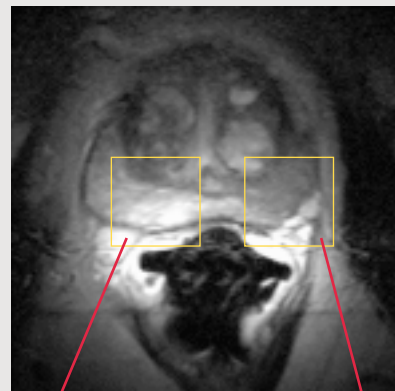


Localized ^1H MR spectroscopy of the prostate

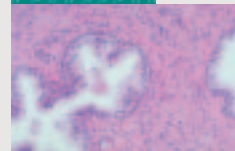- **Citrate**
produced by epithelial cells and secreted in luminal space
- **Creatine**
Cr + PCr: involved in energy-metabolism
- **Choline**
important precursor cell membrane synthesis



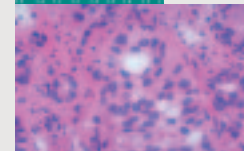
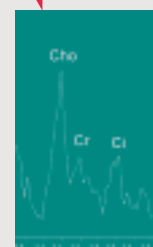T2-TSE



Prostate spectroscopy can provide metabolic information regarding the prostate tissue. Example single voxel MR spectroscopy.

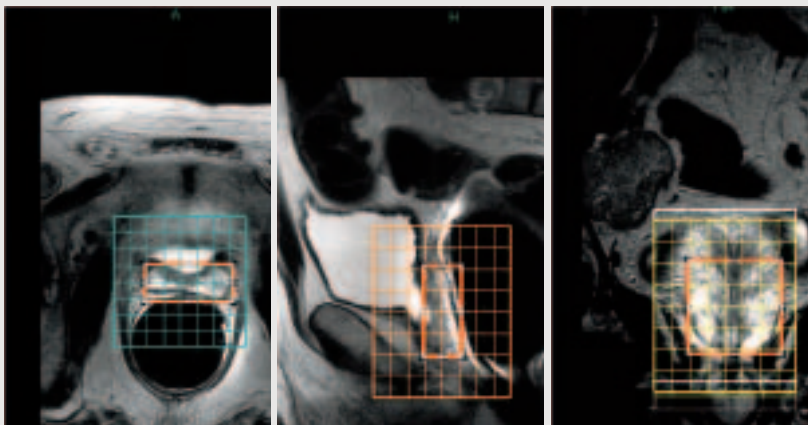
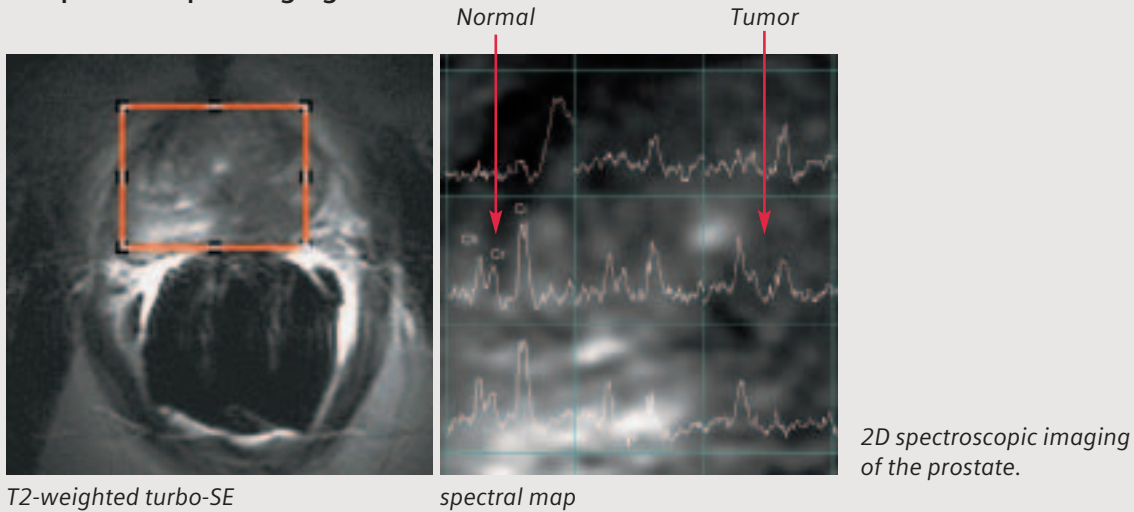


"normal"



tumor

2D spectroscopic imaging

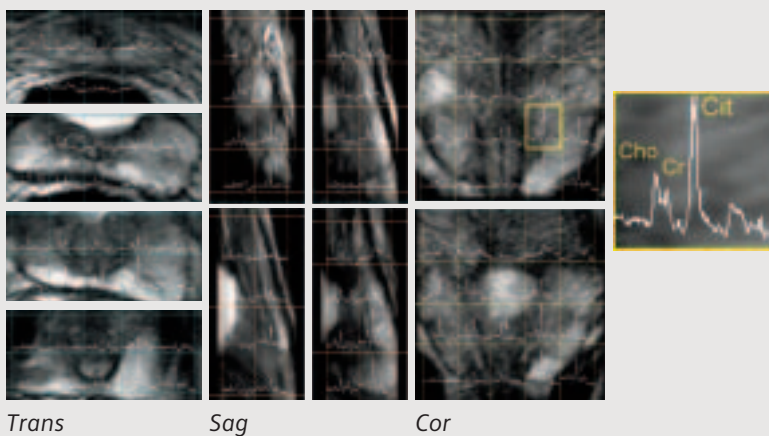



3D PRESS MRSI of the prostate.

Matrix size :
 $8 \times 8 \times 8$; FoV: $64 \times 64 \times 80$ mm,

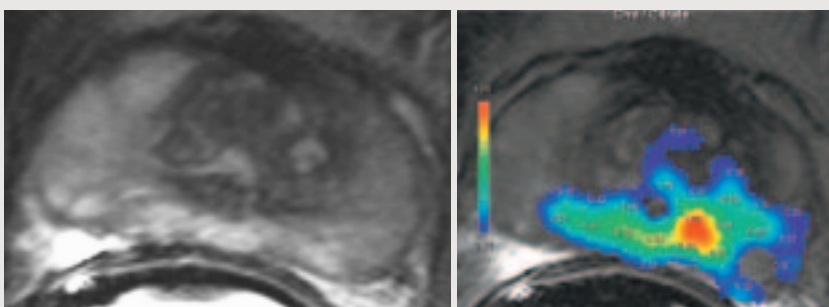

Nominal resolution:
 $8 \times 8 \times 10 \text{ mm}^3 = 0.64 \text{ cc}$,
 $TR = 1,2 \text{ s} \rightarrow$ Acquisition time
11 minutes.

3D-MRSI





Positioning of up to 8 OVS bands around the prostate helps to suppress signals from fat & extreme intensities near the coil.



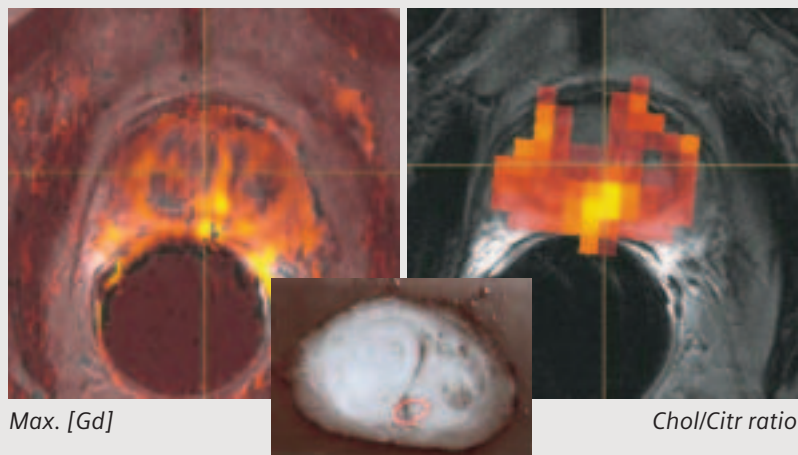
T2-w

MRSI

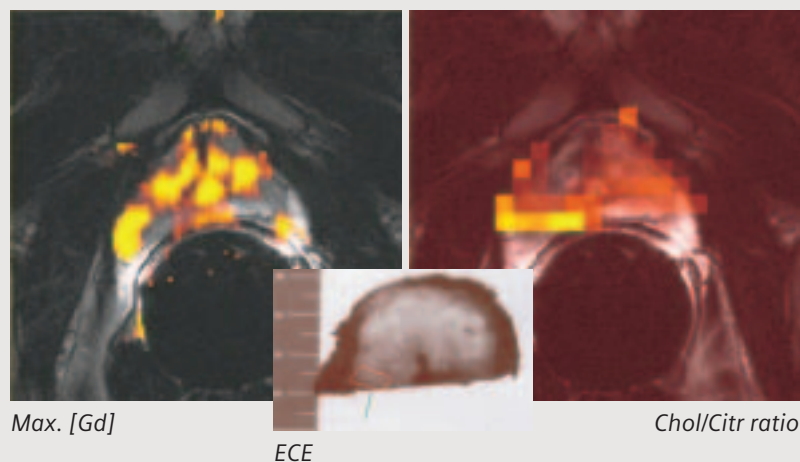
*Signal integration
→ Display of data in
metabolite maps or ratios,
Choline/citrate maps
with color overlay.*

Clinical applications of MRI/MRSI in prostate cancer

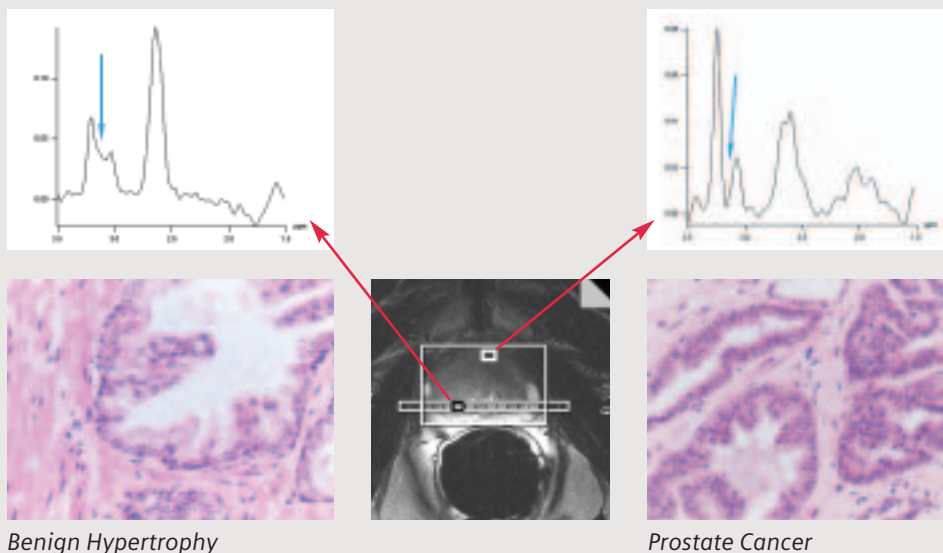
- Where is the tumor (location)?
- Stage of the tumor
- How aggressive
- Improved therapy selection
- Elevated/rising PSA, but negative TRUS biopsy
- Therapy assessment



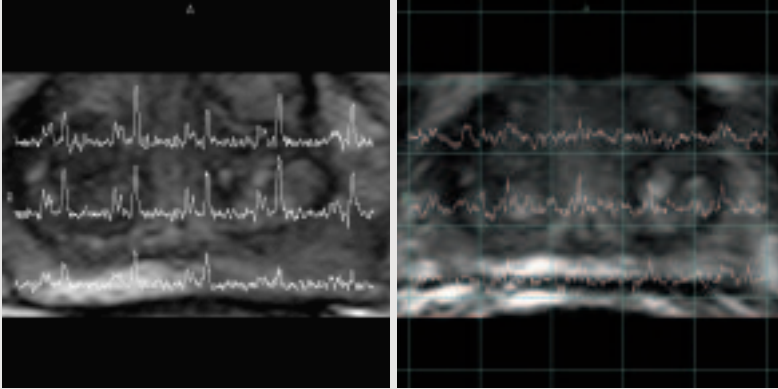
The combined MR perfusion studies and the chol/citr metabolite maps showing the location of the prostate tumor.



Elevated PSA/negative biopsy



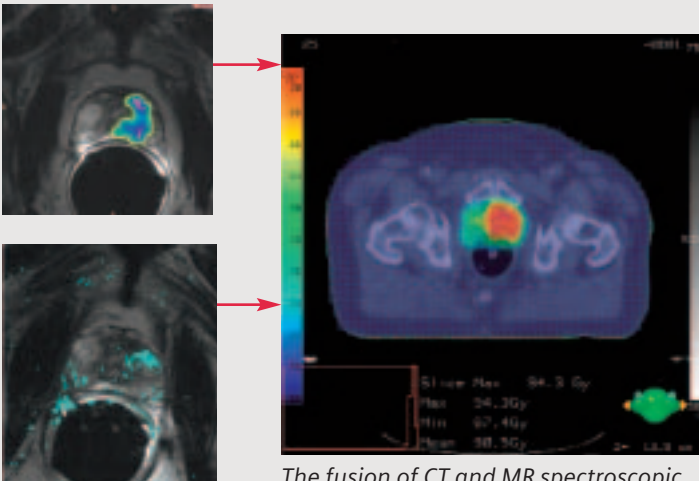
This patient with PSA 4.0 ng/ml had had a biopsy which was negative. The following MR spectroscopy showed a malignant lesion in the anterior part of the prostate which was difficult to reach by needle.



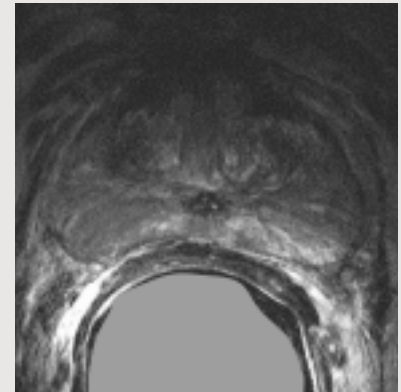
After therapy

Spectroscopy showed decreased metabolites and also decreased size of the prostate 5 months after hormone therapy.

More accurate IMRT-planning

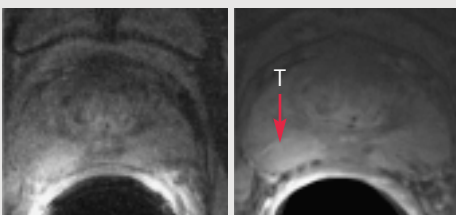


The fusion of CT and MR spectroscopic data provides more accurate information for therapy planning.



3T: 0.18 x 0.18 mm
3T: high resolution T2 TSE.

T1-w. post Gd-DTPA




1.5T

3T

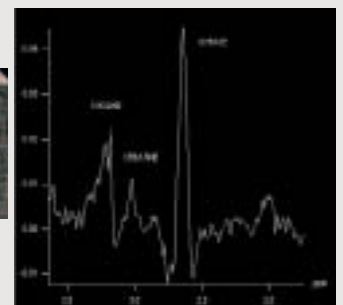

3T: improved tumor visualization.



3T Spectroscopy



1.5T

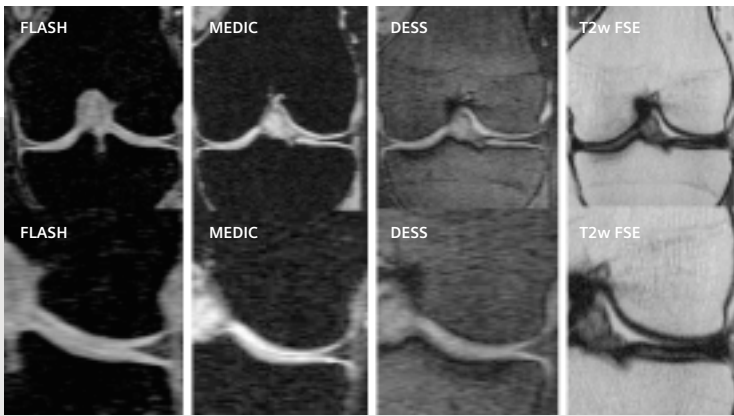


3T

3T vs 1.5T spectroscopy results in prostate.



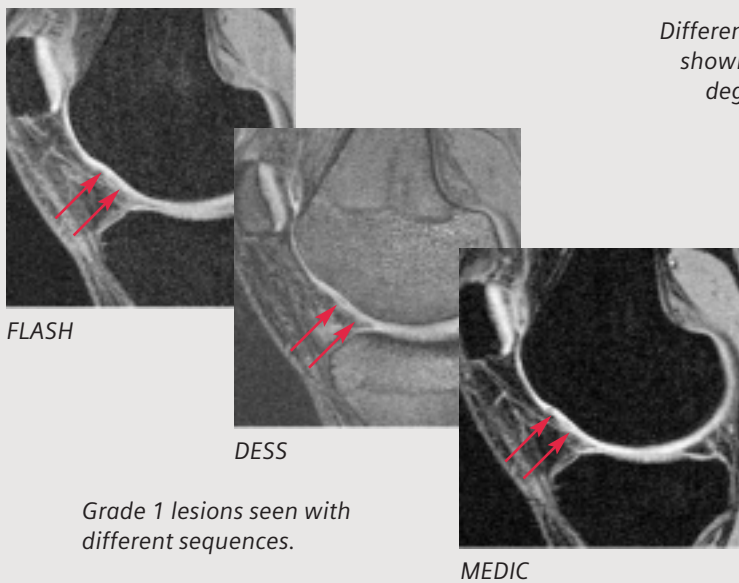
Osteoarthritis is the most prevalent chronic disease in the western world. Drs. Cavallaro and Mamisch from Erlangen University showed the use of MR in the early diagnosis of cartilage changes. The comparison of different sequences like Flash, medic, DESS and T2-weighted Spin Echo and also the comparison of findings at 3T and 1.5T were striking topics of their presentation.



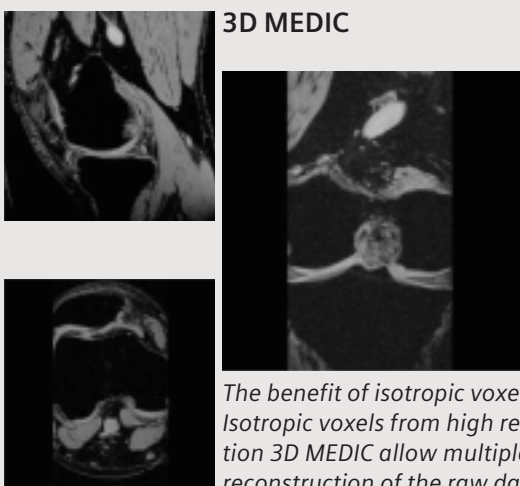
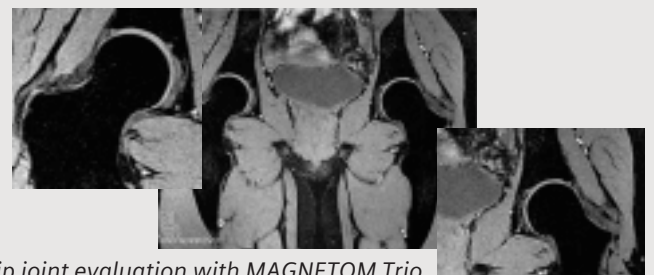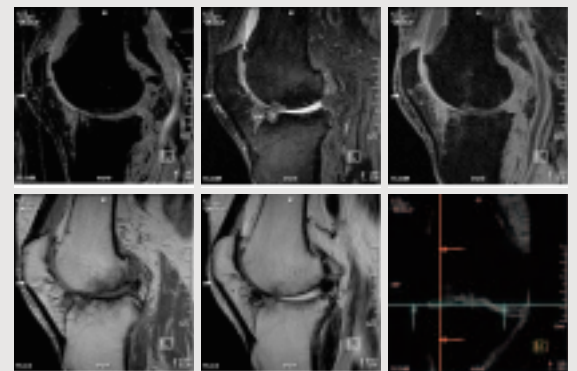
C/N between cartilage and synovial fluid was in the same order of magnitude in all GRE but as expected much worse than in T2-weighted SE images. Contrast between cartilage and bone was good in FLASH and MEDIC. However, due to the long TE cartilage thickness is underestimated in MEDIC images. DESS images more reliably depict the cartilage layer, but images generally suffer from insufficient fat suppression and low S/N.

$$C/N_{\text{cartilage - adj. tissue}} = \frac{\text{mean SI (ROI}_{\text{cartilage}} - \text{ROI}_{\text{adj. tissue}})}{\text{SD SI (ROI}_{\text{noise}})}$$

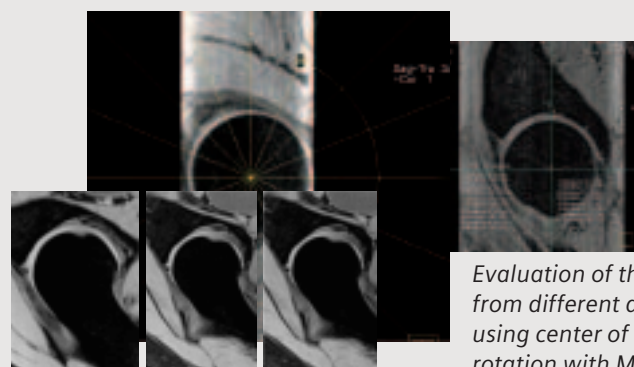
C/N	cartilage-synovial fluid	cartilage-meniscus	cartilage-bone
FLASH	10.10	10.17	17.14
MEDIC	5.07	16.24	21.13
DESS	7.49	6.57	6.71
T2w SE	35.47	2.84	-



Different sequences showing cartilage degeneration...



The benefit of isotropic voxels... Isotropic voxels from high resolution 3D MEDIC allow multiplanar reconstruction of the raw data.




Evaluation of the hip from different angles using center of hip rotation with MR.

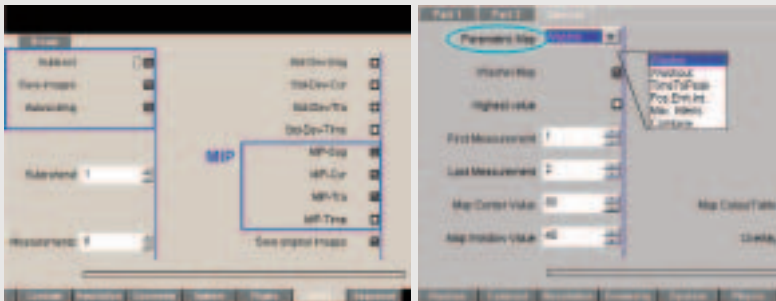


Breast MRI is increasingly being used by radiologists. Dr. Khoury, from the Institute Curie, Paris, France, demonstrated the use of latest iPAT technique in breast MR. He also showed very impressive results with the new post-processing breast-perfusion software available with syngo 2004A. The clinical results showed that this perfusion post-processing could improve the certainty in evaluating enhancement and wash-out patterns in contrast enhancement of breast pathologies.*

**WIP: The information about this product is preliminary. The product is under development and is not commercially available in the U.S., and its future availability cannot be assured.*

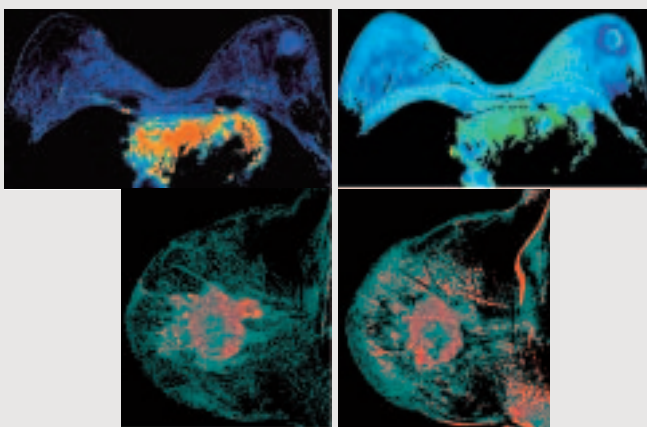


Bilateral transverse data acquisition with water excitation. The sequence is repeated up to 8 minutes after contrast media. FLASH 3D WE $0.7 \times 0.8 \times 3 \text{ mm}^3$, TA = 48 seconds GRAPPA with PAT 2 x, TR = 4.3, TE = 1.6.



With Siemens automatic breast perfusion post-processing, you choose the type of post processing images you need, the maps are automatically calculated after the study.*

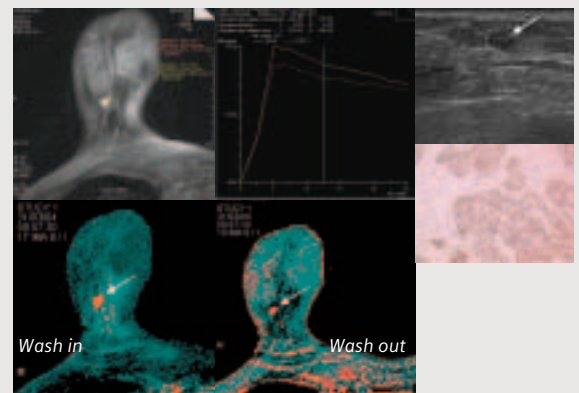
Invasive Carcinoma



Wash in Wash out

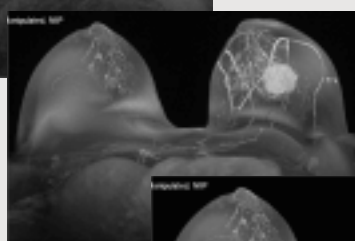
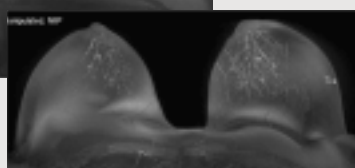
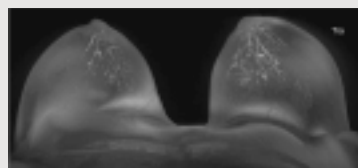
Invasive breast carcinoma with necrosis in the centre seen with breast perfusion post-processing.*

*WIP: The information about this product is preliminary. The product is under development and is not commercially available in the U.S., and its future availability cannot be assured.

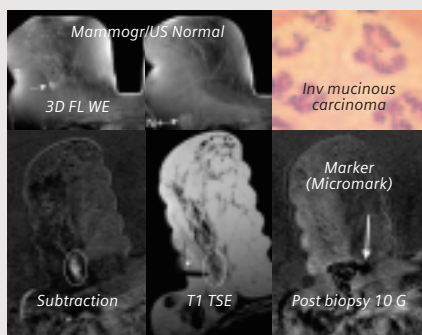


Invasive Recurrent Carcinoma

This is an example of a small enhancing lesion with benign morphology. When the parametric map was applied, it was observed that there was washout inside the lesion. Ultra-sonography showed a rather well delineated lesion which corresponded to an invasive recurrent carcinoma.*



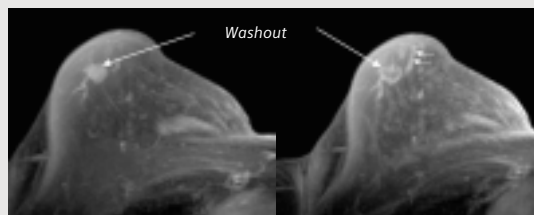
Dynamic MR images with MIP projections showing the enhancement of the lesion and in later phases the axillary lymph node.



An example of a patient who presented with a positive node in the axilla with normal mammography and ultrasoundography. The lesion was found by MRI and biopsy under MR guidance confirmed the invasive carcinoma.

WIP: The information about this product is preliminary. The product is under development and is not commercially available in the U.S., and its future availability cannot be assured.

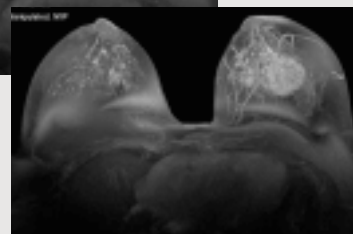
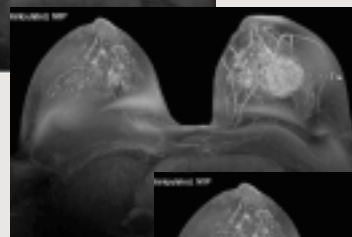
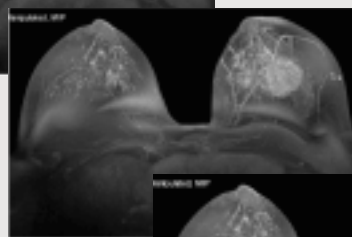
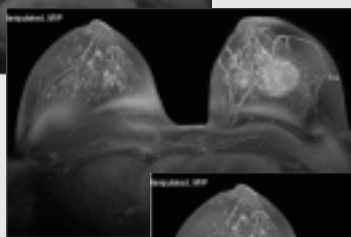
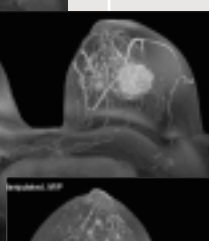
MIP WE 3D Transverse

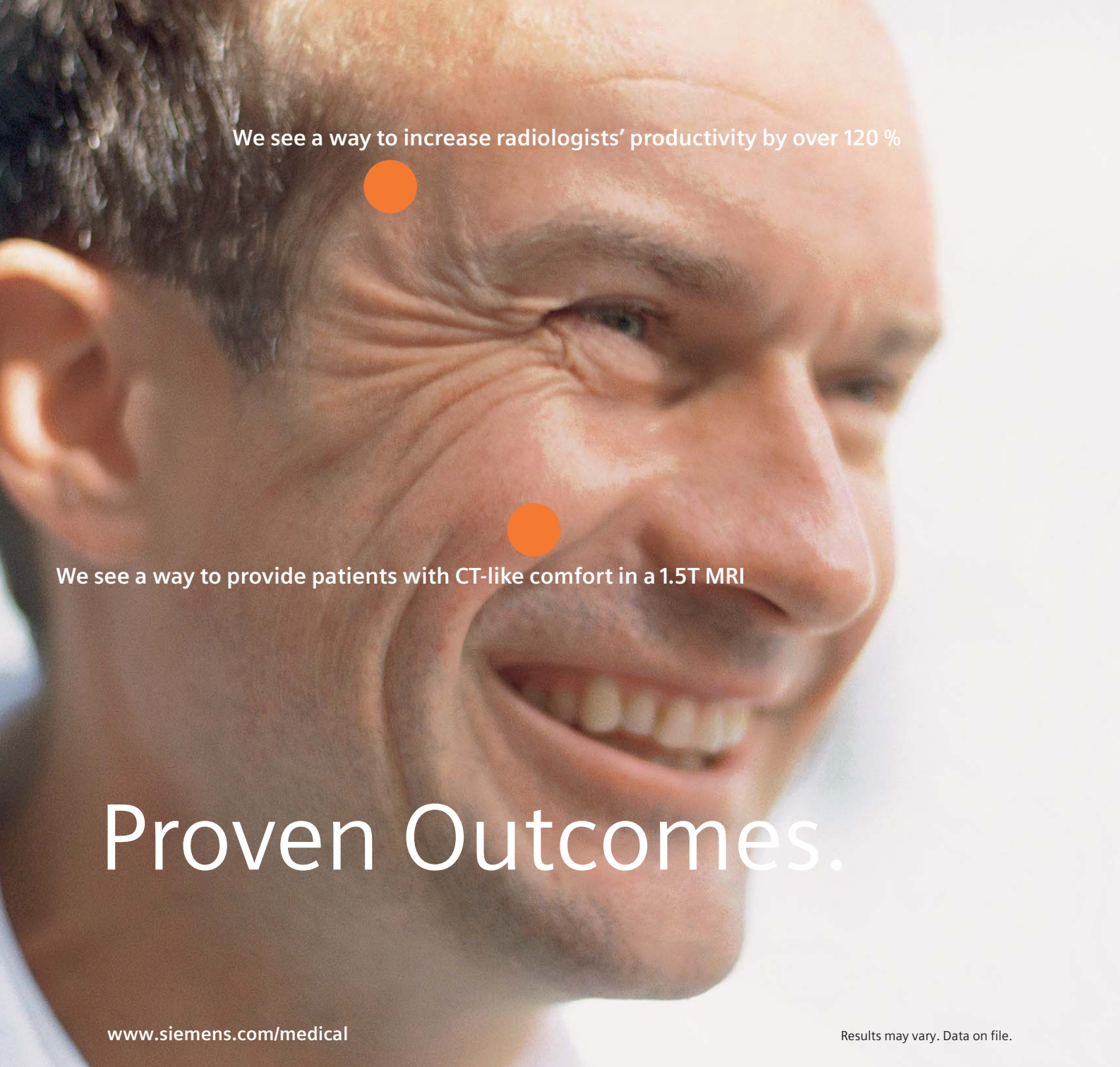


2 min 30 after CM

8 min 30 after CM

An example of the maximum intensity projection of a 2 cm invasive carcinoma with ductal enhancement corresponding to ductal insitu carcinoma.





We see a way to increase radiologists' productivity by over 120 %

We see a way to provide patients with CT-like comfort in a 1.5T MRI

Proven Outcomes.

www.siemens.com/medical

Results may vary. Data on file.

M-2879-1-7600

Proven Outcomes that help you go further.

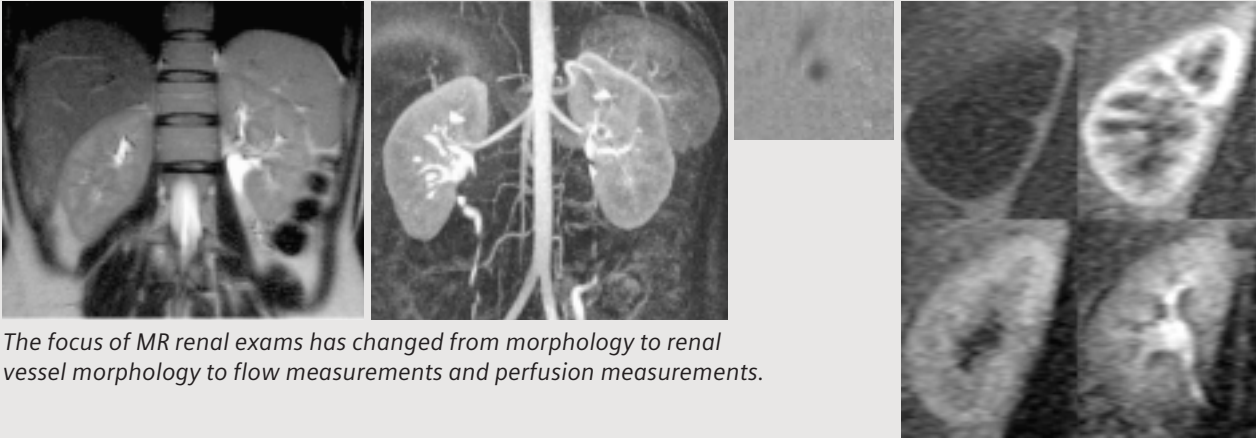
The most important question these days is: what can we do to improve the quality of care while reducing costs? For us, the answer is clear. By combining trendsetting medical equipment with innovative IT we will increase the efficiency of clinical processes. At Siemens, we see a way – lots of ways – to help you go further than ever before.

Siemens **Medical Solutions** that help

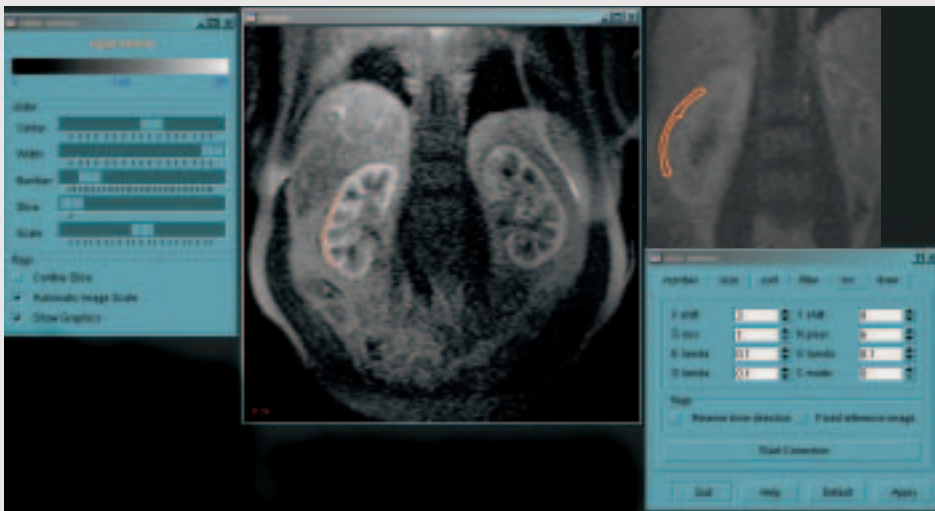
SIEMENS
medical



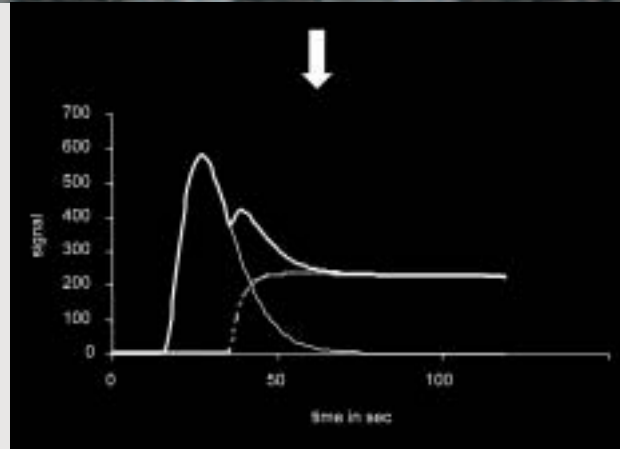
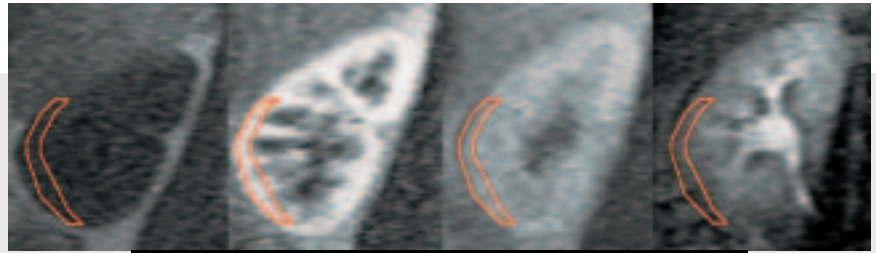
Will kidney perfusion be a routine clinical imaging technique for evaluation of renal and vascular diseases? Dr. Michaely (Ludwig-Maximilian-University, Munich), with experience of over 100 patients, showed clinically relevant MR perfusion results in the evaluation of renal artery stenosis, renal transplant assessment and ureteral obstruction. He also touched on the work-in-progress topic of absolute quantification.



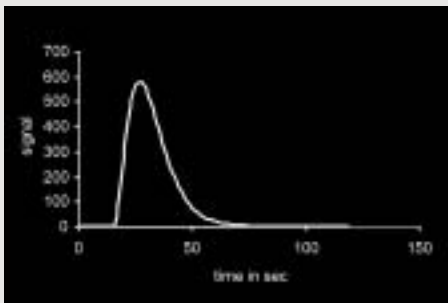
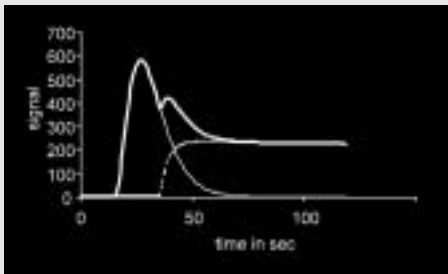
The focus of MR renal exams has changed from morphology to renal vessel morphology to flow measurements and perfusion measurements.



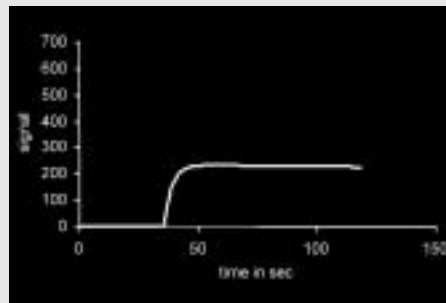
Motion correction is used in the post-processing to compensate for the motion of the kidneys due to breathing while performing the kidney perfusion studies.



Postprocessing



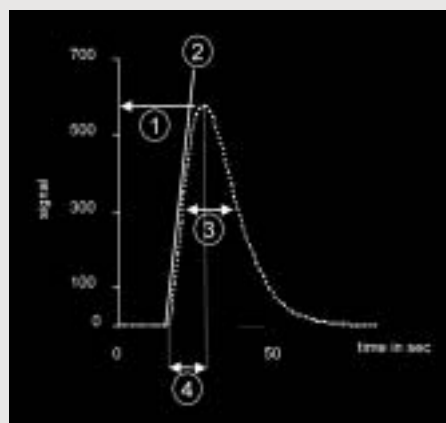
First Pass Perfusion



Filtration

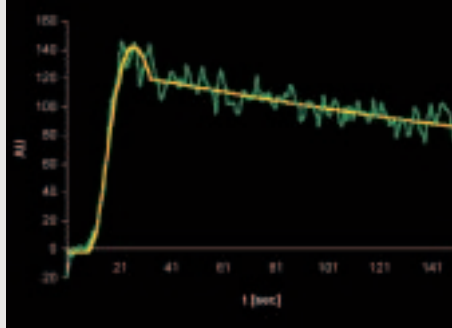
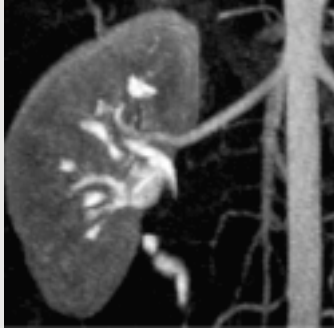Perfusion curve can be split up as first pass perfusion and filtration.

Various parameters obtained from the first pass perfusion curve.

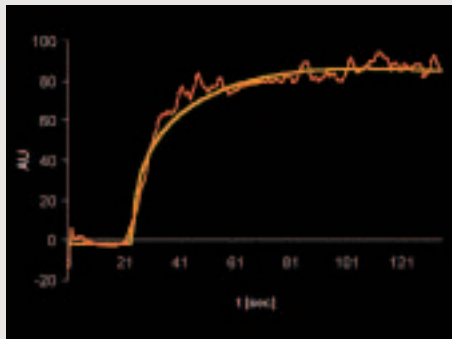
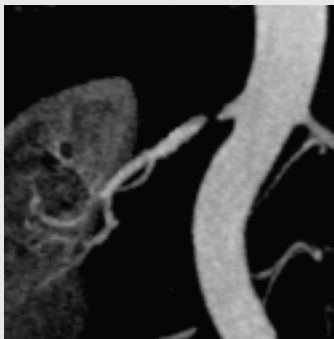


First Pass Perfusion

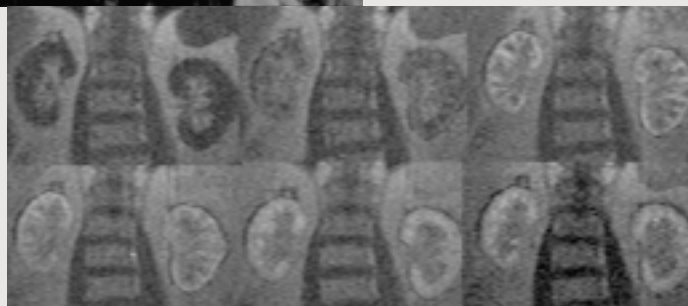
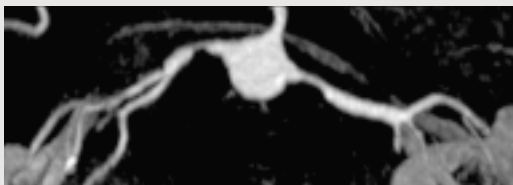1. maximal signal intensity (MSI)
2. maximal upslope (MUS)
3. mean transit time (MTT)
4. time to peak (TTP)



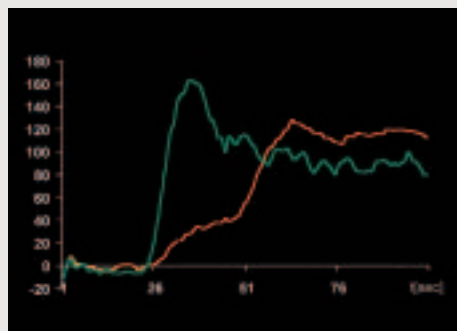
Healthy kidney:
normal perfusion curve.
MTT 14.7 s, MUS 30.0.



High grade renal artery
stenosis (>90%): slowed upslope
and delayed, lowered peak.
MTT 30.1, MUS 17.4.

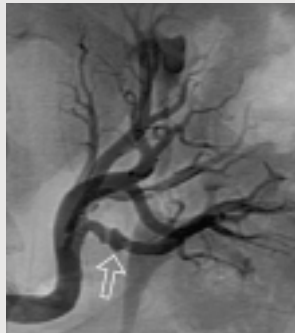

60 year old male with
hypertension. Visual assess-
ment shows slow contrast
agent arrival, inhomoge-
neous enhancement of the
renal cortex.

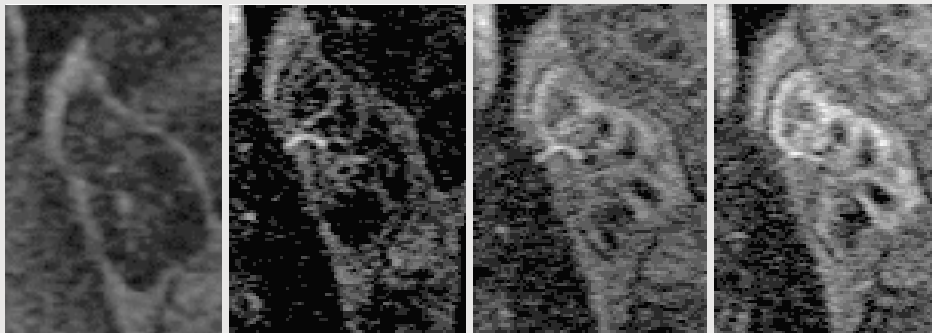


Semiquantitative analysis of the
same patient showed markedly
slowed upslope (MUS 6.5, MTT
88.1) and delayed peak (red
line). Green line demonstrates
healthy kidney for comparison.
The findings were compatible
with high grade renal artery
stenosis.

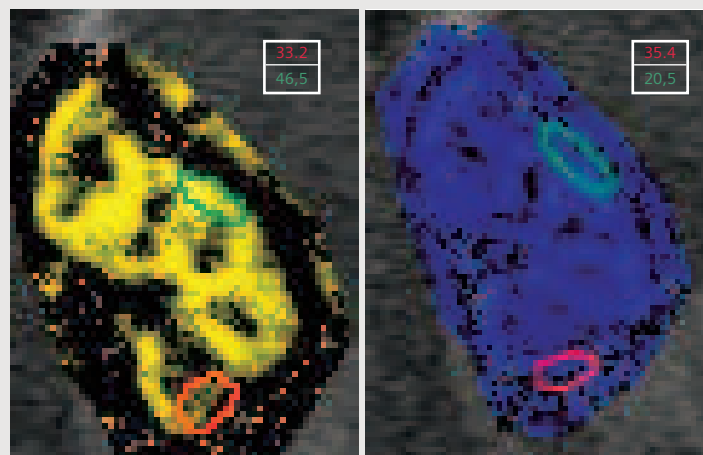
30 year old male with fibromuscular dysplasia



Segmental renal artery stenosis.
30 year old male with hypertension,
MRA was negative.



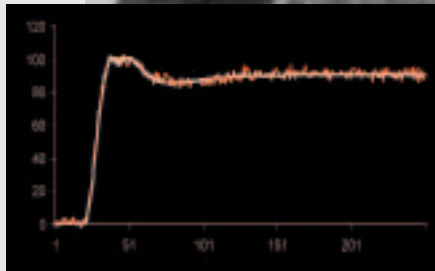
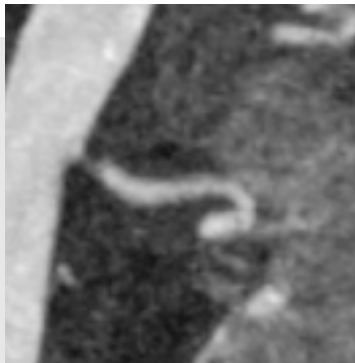
Perfusion MR in the
same patient showed
deficit at the lower
pole of the kidney.



Maximal signal intensity (A.U.) MTT (s)

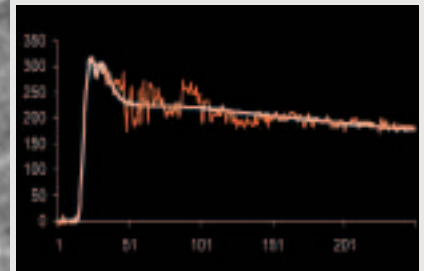
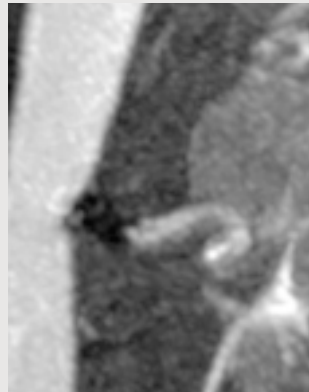
Color coded map showed the lower pole to have an increased mean transit time. The findings indicated segmental renal artery stenosis. The final diagnosis of the patient showed fibromuscular dysplasia.

High-Grade
RAS pre PTA



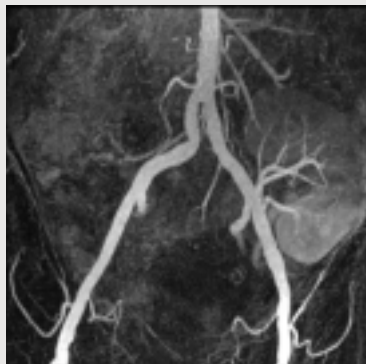
63 year old female patient with hyper-tension and bilateral renal artery stenosis. Pre PTA (Percutaneous angioplasty) showed a MTT 26 s, MUS 21.

High-Grade RAS post PTA

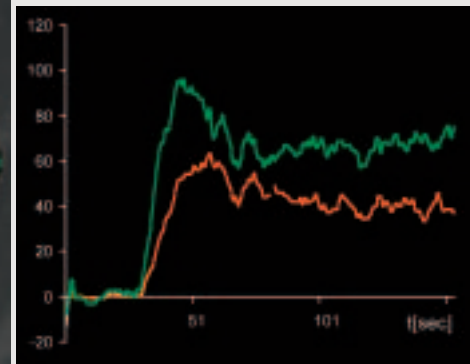
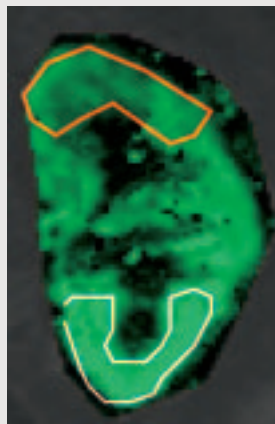


After treatment
Post PTA MTT 15 s, MUS 48.

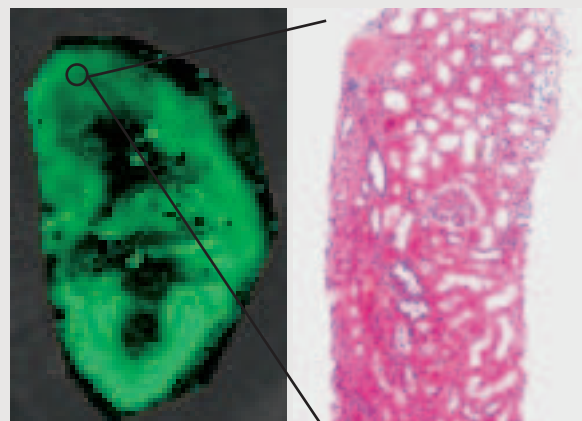
Renal Transplant Assessment



60 year old male patient, renal transplant 5 years ago, rise of serum creatinine, no renal artery stenosis.



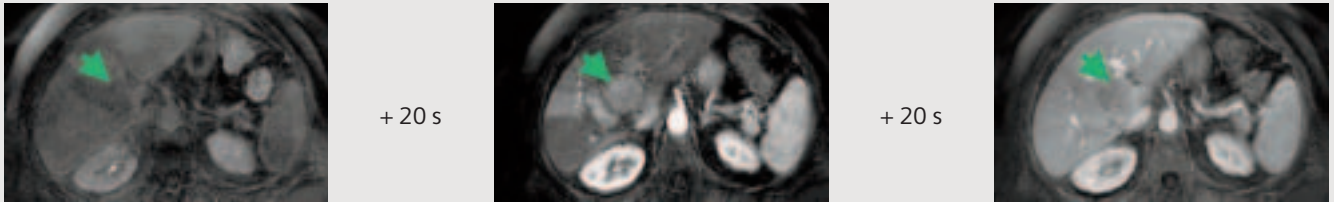
Upper pole (red line) shows decreased perfusion compared to lower pole (green line).



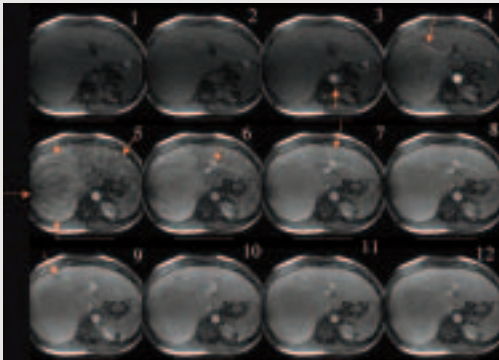
Biopsy at upper pole shows chronic ischemic changes...



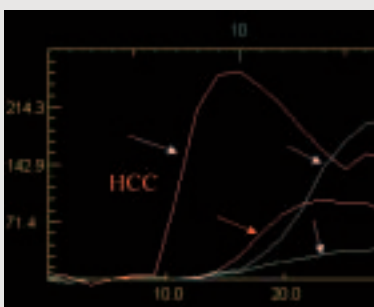
Dr. Goldman's (Mount Sinai School of Medicine) talk was dedicated to perfusion MR imaging of different organs. He showed the clinical potential of liver perfusion imaging and different techniques for performing this examination, as well as the challenges lying ahead for these techniques. He also touched on the topics of renal perfusion MRI and pulmonary perfusion MRI.



Traditional contrast enhanced MRI – 3 phase examination



Rapid imaging shows more detail compared to routine dynamic MR imaging.



Hepatic artery, HCC, portal vein, liver enhancement. With the perfusion pattern, it is possible to differentiate the hepatocellular carcinoma from the normal liver. Signal intensity versus time curves provide an enhancement profile which can be used to uniquely describe hepatic pathology.

Challenges of Functional Hepatic MRI Acquisition Technique

Need for High Temporal Resolution

Rapid uptake of hepatic artery and portal vein

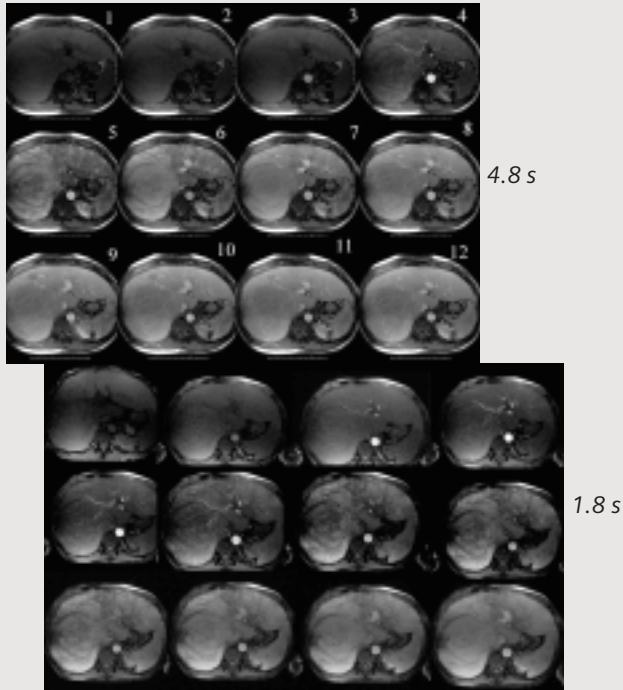
Need for High Spatial Resolution

Small size of many hepatic lesions

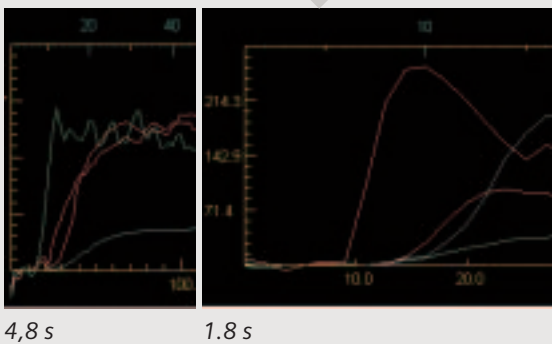
Need to Image Over Multiple Breath-holds

Limited S/N available to trade for Increased Spatial and Temporal Resolution

Low signal to noise of enhanced liver

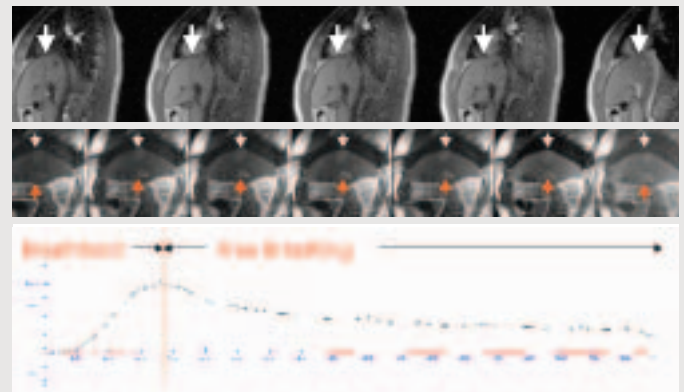
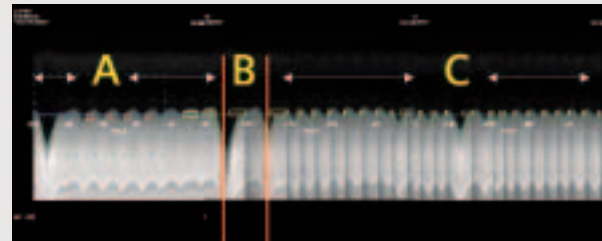


What is the necessary temporal resolution for liver perfusion studies?

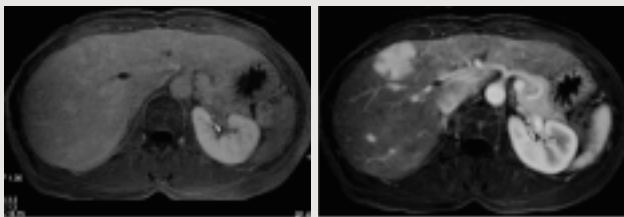



Faster scanning techniques as seen here with 1.2 s temporal resolution allow a better analysis and resolve the portal vein and the aorta better.

Development of Navigator Breath-hold/Free Breathing Technique

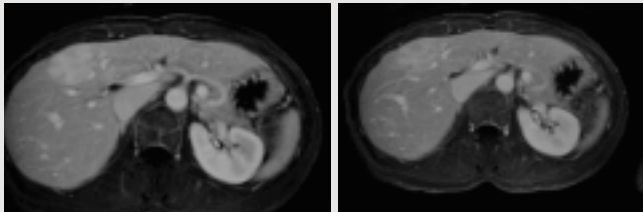


Showing the free breathing and navigator combination for analysis of perfusion. The intensity curve is much better than other curves where there is no navigator correction for breathing artefacts.



Pre contrast

Arterial Phase

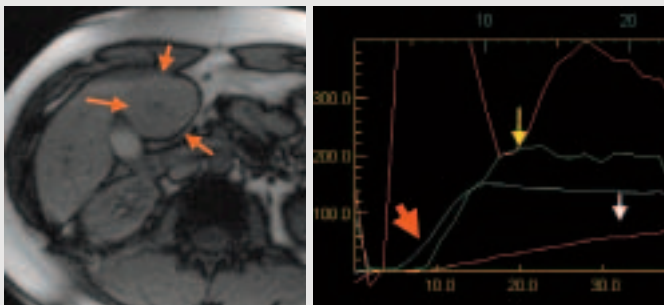


Portal venous phase

Delayed

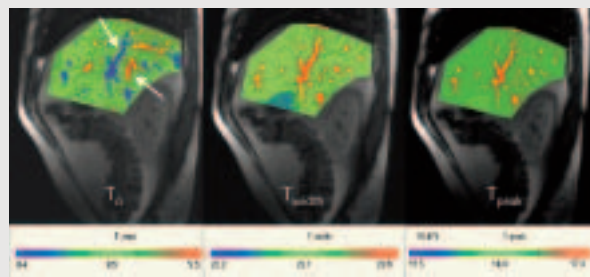
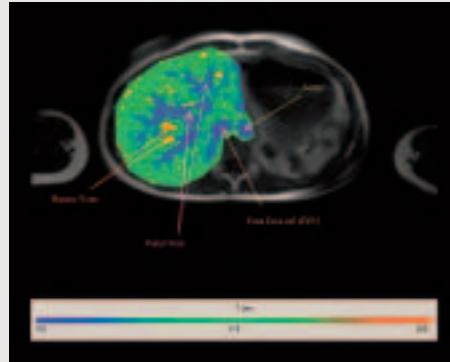
Functional-morphologic exam showing adenoma of the liver.

Focal Nodular Hyperplasia

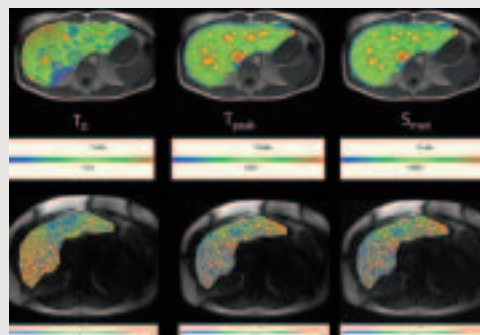


4 slices/second, 0.5 dose gad.

Enhancement pattern of focal nodular hyperplasia.

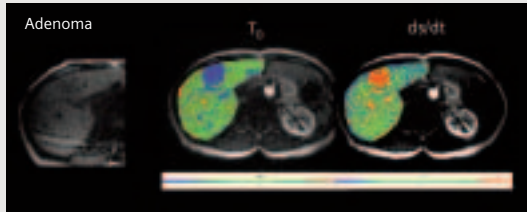


Parametric Mapping
Functional hepatic MRI, normal controls.



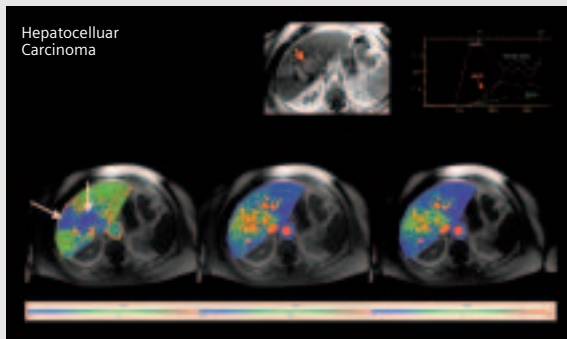
Functional hepatic MRI – Normal vs. Cirrhosis
showing heterogenous enhancement of
the liver in the cirrhosis patient. Parametric
analysis allows visualization of perfusion
without cumbersome ROI drawings.

Hepatic Masses



Parametric map showing adenoma perfusion.

Hepatocellular Carcinoma

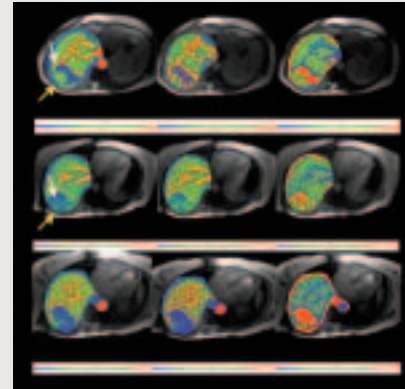


Parametric perfusion maps show increased perfusion of the hepatocellular carcinoma and the area posterior to it.

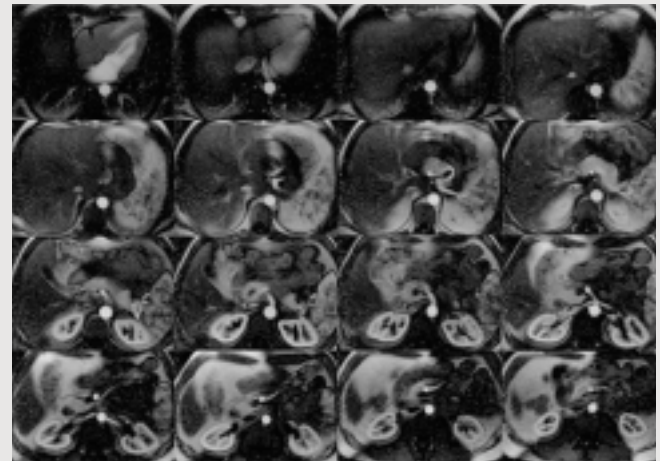
Pre tx

1 cycle tx

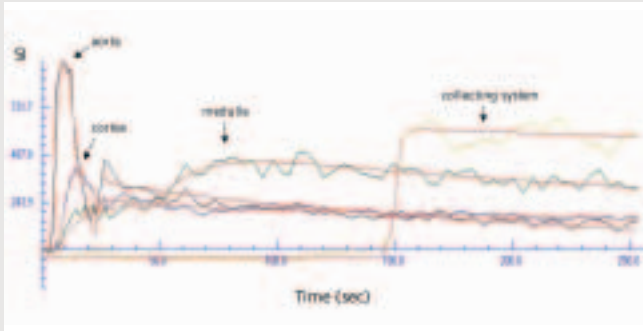
2 cycle tx



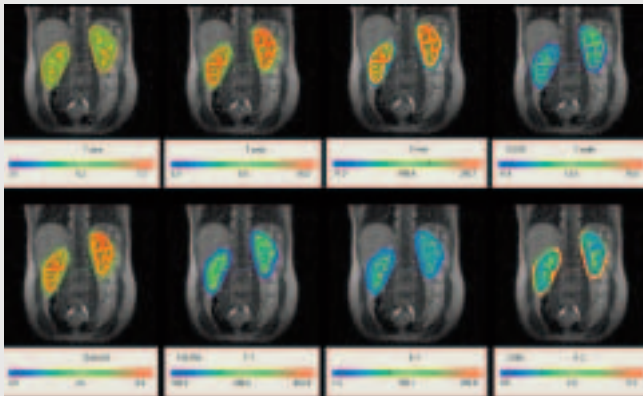
Monitoring anti-angiogenic therapy. Further decreased enhancement of the lesion during the therapy.



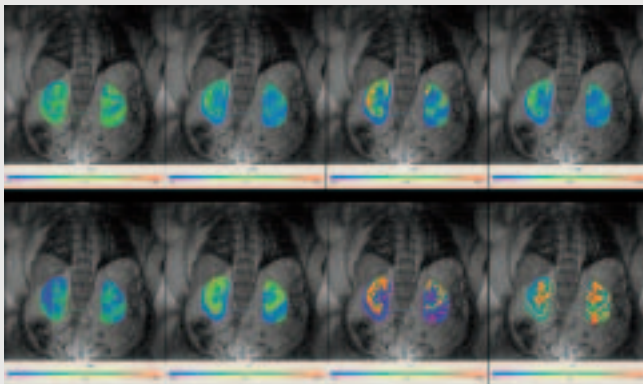
16 slices in 2 seconds with parallel imaging.



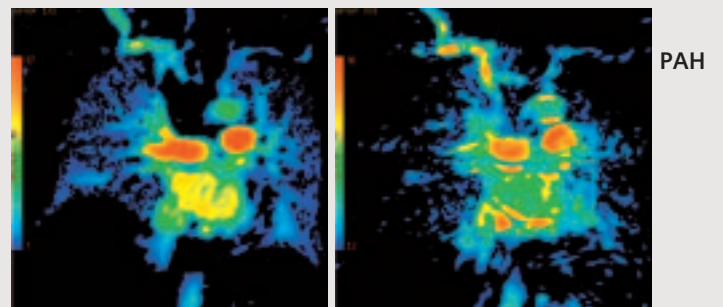
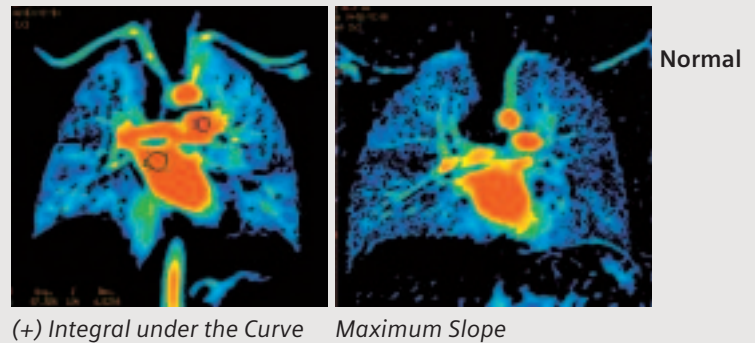
Renographic curves.



Parametric maps of normal kidneys.



Parametric Maps – chronic renal insufficiency.
Distribution of enhancement can tell different states of the renal insufficiency.



(+) Integral under the Curve Maximum Slope

Pulmonary artery hypertension. Marked decrease of perfusion in the periphery is seen with perfusion parametric maps.*

*WIP: The information about this product is preliminary. The product is under development and is not commercially available in the U.S., and its future availability cannot be assured.



Dr. Friebe introduced the first dedicated radiology center for animal disease diagnosis on a referral basis in Germany, located in Castrop-Rauxel. The institute is equipped with the MAGNETOM Open Viva. Dr. Friebe showed some clinical MR results and expressed the wish to Siemens that the cervical coils should be made larger to enable the scanning of neck pathologies in horses by creating a larger field of view.



*275 m² – dedicated office/imaging
(CT/MRI/US/X-ray)*

*1.750 m² – property, including area for horses.
First dedicated radiology center in Germany
exclusively for animal diagnosis on referral basis.*

*MRI → OPEN, CT → SPIRAL, US → Colordoppler,
X-Ray → digital PACS → DICOM Archiving + Tele-
radiology*

*Operational since 03/2004 in Castrop-Rauxel,
Germany*

Large Animal setup

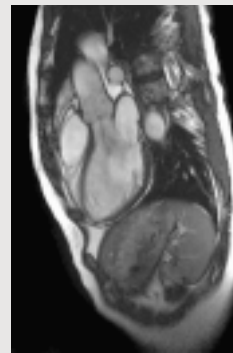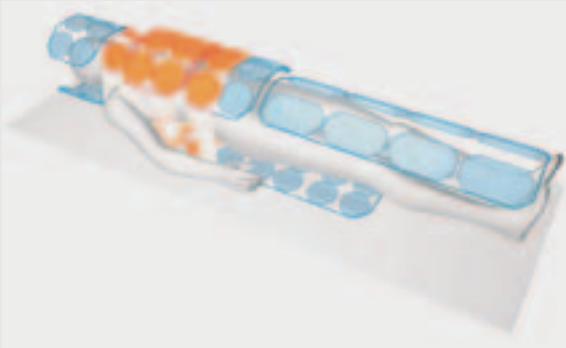


*MAGNETOM Open Viva and the cervical vertebrae of horses.
MAGNETOM Open Viva, even though perfectly suited for
most MR exams of the horses, is limited for cervical images
below C4.*


*One requirement from Dr. Fiebe was that of a larger bore
open system so that the shoulders of horses can approach
more to the magnet center and another requirement was
of larger and dedicated coils for horses.*



Few institutions in the world have as much experience as UCLA (University of California in Los Angeles) with both Siemens state of the art MR systems: MAGNETOM Avanto and MAGNETOM Trio. Dr. Paul Finn from UCLA demonstrated his prowess in cardiovascular MRI with both of these systems. He concluded that MAGNETOM Avanto with Tim has major advantages in FoV and iPAT capability, that Trio is extremely promising for high resolution MRA and that the combination of Trio and Tim would make a major difference in creating high resolution MR images.

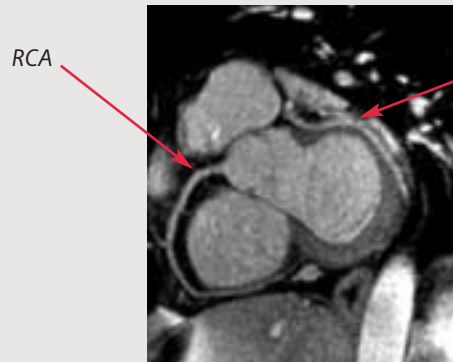



25 phases, 50 ms res.
1.3 x 1.3 x 6 mm³,
12 heart beats



20 phases, 60 ms res.
22 heart beats
VENC: 150 cm/s

Cardiac analysis
with MAGNETOM
Avanto. Flow and
Cine images
prove mild aortic
insufficiency.



RCA

LCx

MAGNETOM Avanto
coronary imaging.
3D TrueFISP, TR/TE/FA =
3.2 ms/1.4 ms/70°,
Resolution =
1.3 x 0.9 x 3 mm³,
41 segments, BW =
975 Hz/pixel,
24 HB breath-hold.

no iPAT
11 hb



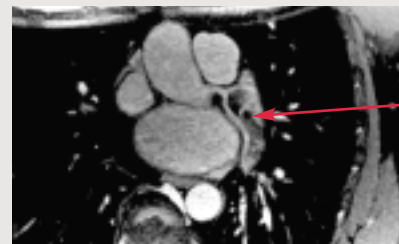iPAT = 3
5 hb

iPAT = 2
7 hb



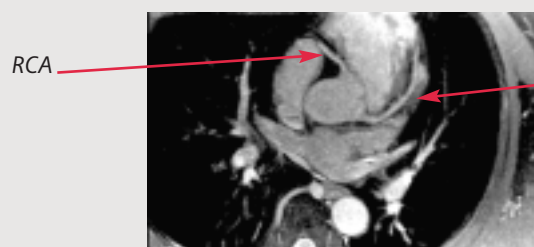
iPAT = 4
4 hb

Cardiac imaging with MAGNETOM
Avanto. TrueFISP Cine. 25 phases,
40 ms resolution, 1.9 x 1.7 x 6 mm³.



LCx

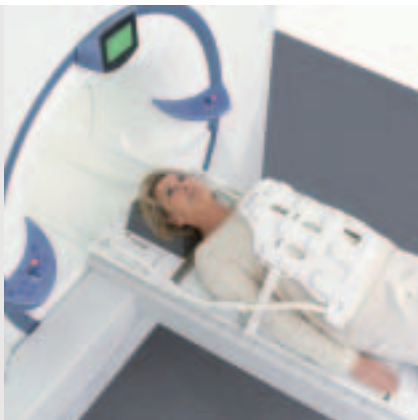Coronary MRA. 3D TrueFISP, TR/TE/FA = 3.2 ms/
1.4 ms/70°, Resolution = 1.3 x 0.9 x 3 mm³,
41 segments, BW = 975 Hz/pixel, 24 HB breath-hold.



RCA

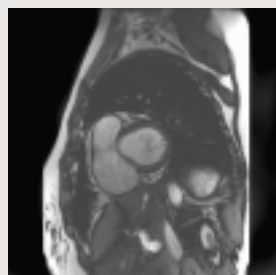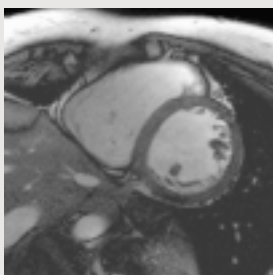
LAD

Coronary MRA, 3D TrueFISP, TR/TE/FA = 3.2 ms/
1.4 ms/70°, Resolution = 1.3 X 0.9 X 3 mm³,
41 segments, BW = 975 Hz/pixel, 24 HB breath-hold.

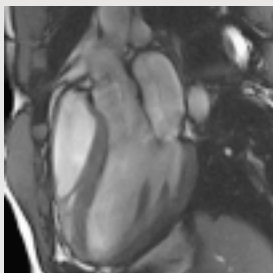

Cardiac MRI at 3.0T

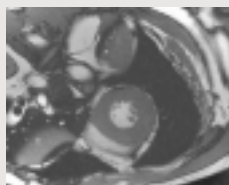
- 8 elements cardiac array coil
- Anterior (4) + posterior (4)
- Compatible with parallel imaging
- Active ECG-electrodes
- Protocols optimized for SAR



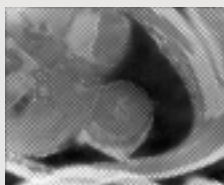
with PAT x2 TA 8 s



Cardiac cine imaging at 3T with 8-channel cardiac array coil (PAT x 2, TA 8 s).

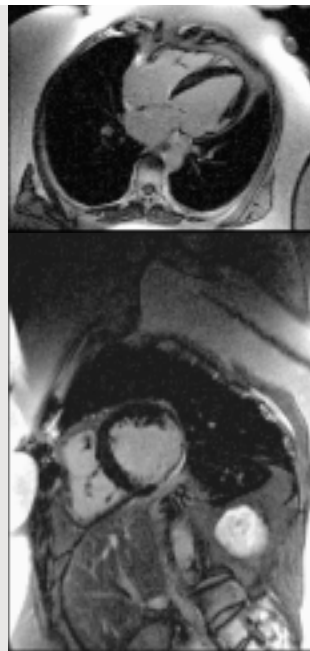

TrueFISP cine

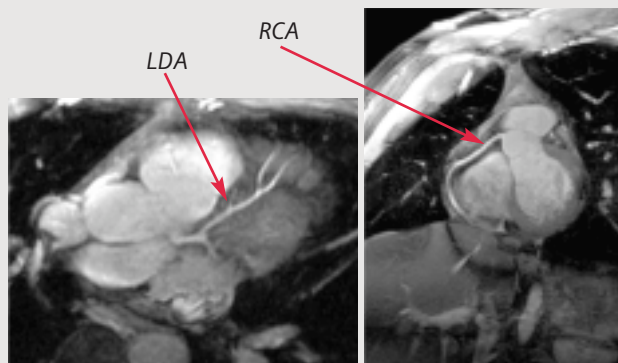


grid tagging

Functional MRI at 3T, left ventricular hypertrophy.

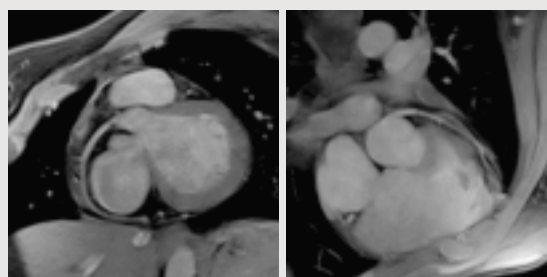


Lt Cx infarction:
viability* study with
MAGNETOM Trio.



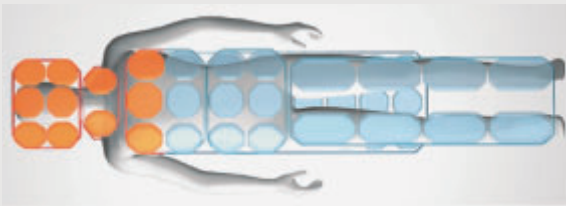
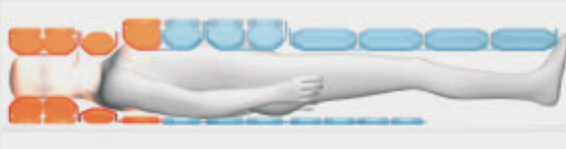
Courtesy Dr. Vibhas Deshpande, UCLA

Coronary MRA at 3T, breath-hold 3T TrueFISP images.

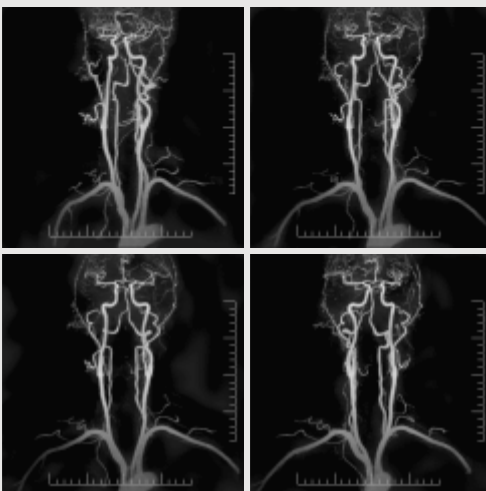
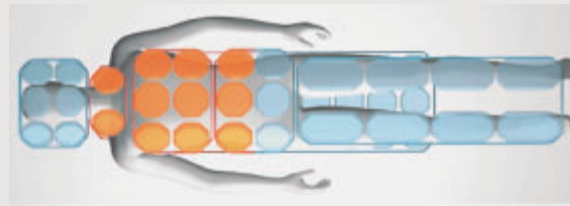



Coronary MRA with navigators at 3T. 8-channel cardiac array coil, active electrode ECG triggering, 1D PACE for motion correction. TA: 6:27 min, Pixelsize: 0.9 x 0.9 x 1.2 mm.

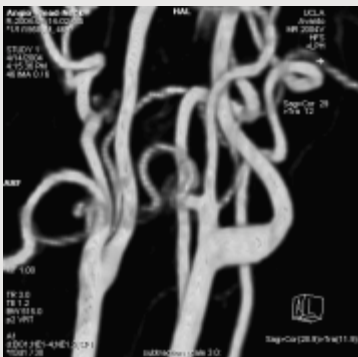*WIP: The information about this product is preliminary. The product is under development and is not commercially available in the U.S., and its future availability cannot be assured.



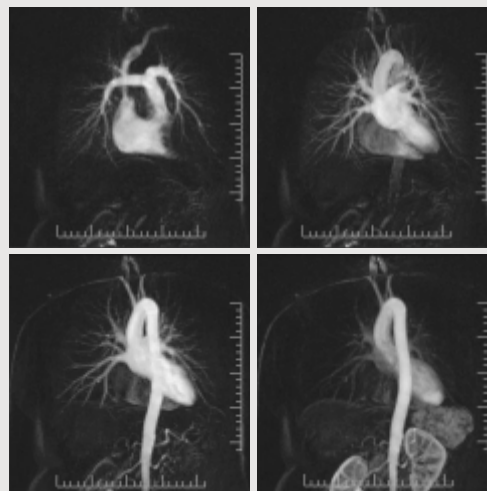
Head-Neck-Thorax coil combination.



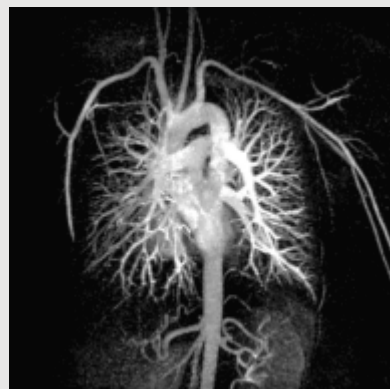Carotid MRA, MAGNETOM Avanto.



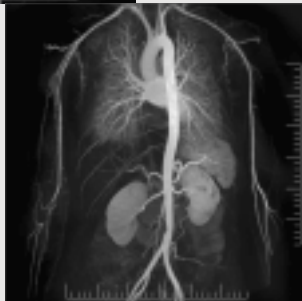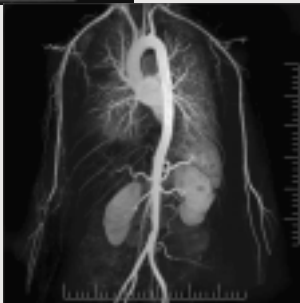
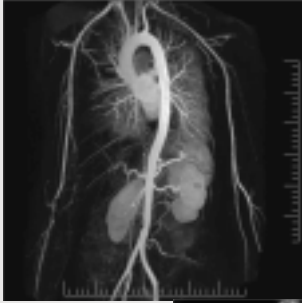
Carotid MRA,
3D FLASH,
21 s, TR/TE =
3.0/1.2 ms,
BW 515 Hz/pixel,
GRAPPA x 2,
coronal, 64 slices,
1.2 mm, matrix:
270 x 512,
FoV: 330 x 440.



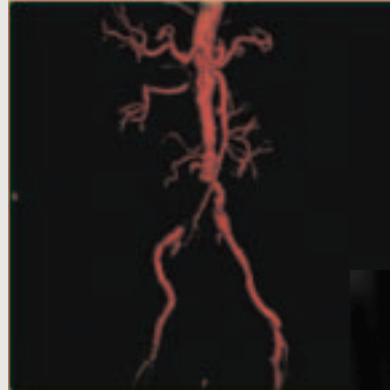Dynamic MRA,
3D FLASH,
2.2 s each,
GRAPPA x2,
coronal,
during contrast
injection,
6cc Gad + 20 cc
saline.



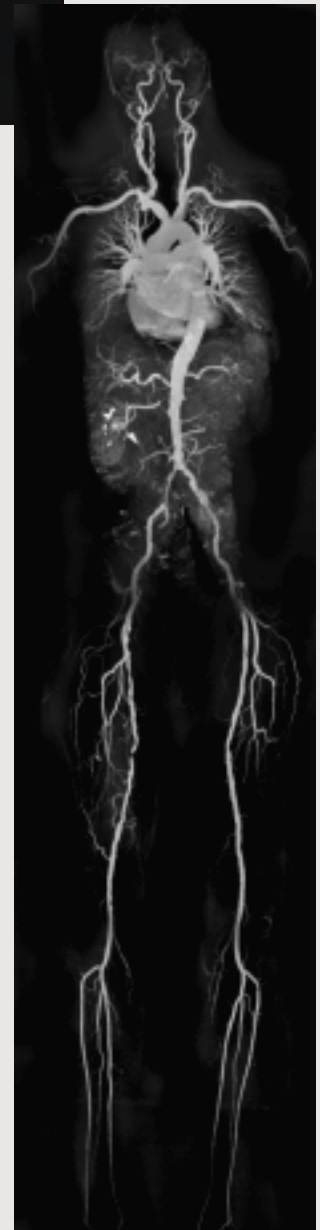
Pulmonary MRA with
MAGNETOM Avanto.
3D FLASH, scan time:
18 s, GRAPPA x 4, (2 x 2),
96 slices, 1.2 mm,
Matrix: 384 x 384,
FoV: 380 x 380,
TR/TE = 2.8 ms/1.0 ms.



*Large FoV MRA:
Claudication right arm,
512 matrix; PAT x 2;
20 s acquisition time
MAGNETOM Avanto.*

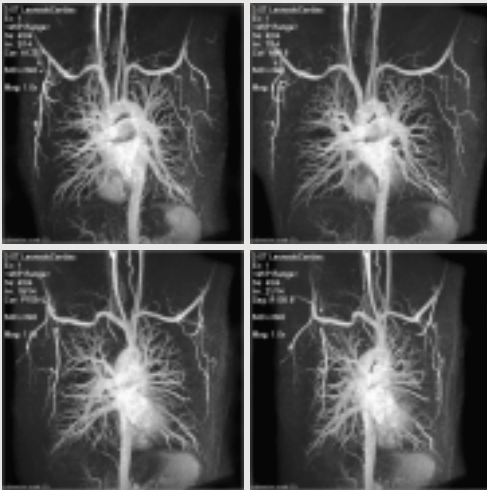


*Visualization of abdominal
and pelvic vessels.
89 year old male patient
(MAGNETOM Avanto).*

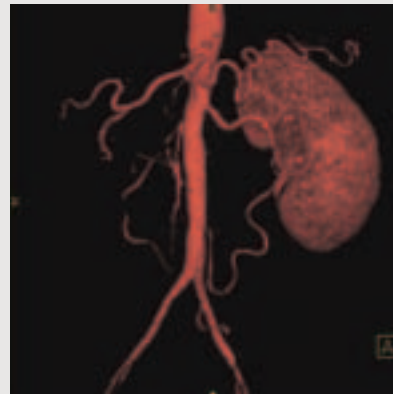


*Whole Body MRA with
MAGNETOM Avanto!*

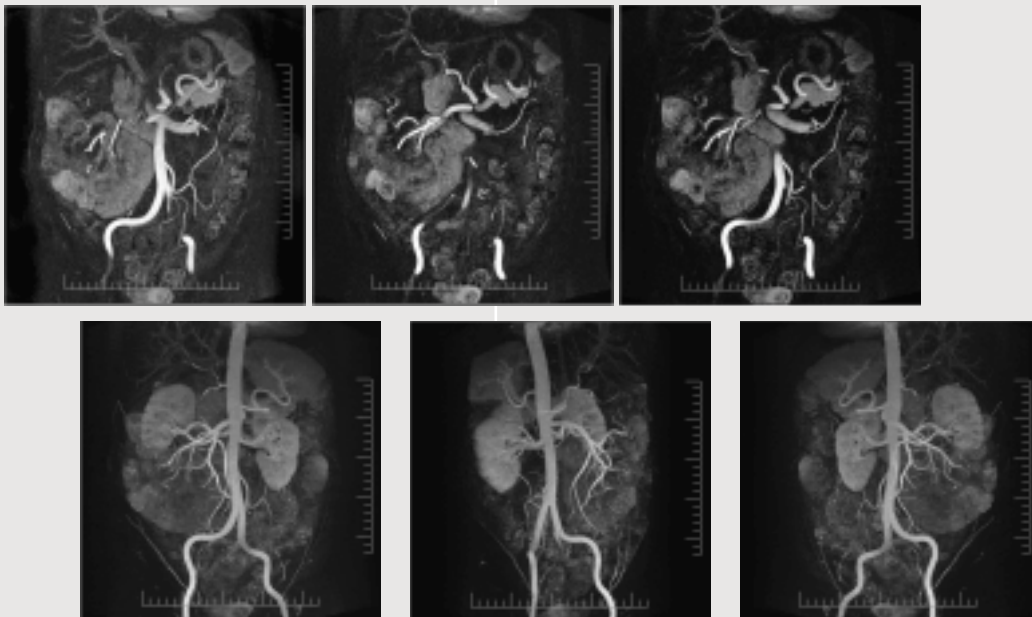
MR Angiography on the MAGNETOM Trio



High resolution thorax imaging with MAGNETOM Trio.
 $0.6 \times 0.6 \times 0.9 \text{ mm}^3$, TA 22 s.



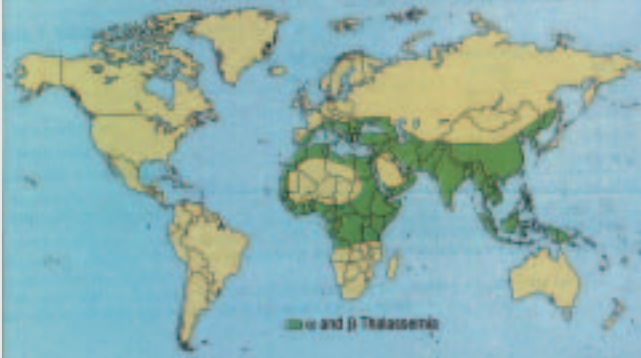High resolution renal MRA at 3T.



High resolution abdominal MRA at 3 Tesla.



Dr. Pennel's (Royal Brompton Hospital, London) talk focused on the diagnosis of cardiac diseases resulting from Thalassemia, a common gene disorder in certain areas of the world: the mortality rate is 70% through cardiac failure. He talked in detail about a multi-center clinical study which is evaluating the use of MR in the diagnosis of iron overload in the heart with T2* measurements.



Thalassemia


- Commonest single gene disorder
- 1.5% carrier rate worldwide
- 60,000 affected babies born/year
- 800 patients in UK

Thalassemia – Premature Death

- **Transfusions cause build up of iron**
Organ failure
- **Commonest cause of death**
Heart failure in 71%
- **In the UK in 2000**
50% die before age 35 in UK

Measuring Myocardial Iron

- MR uses magnets
- Iron disturbs magnetic fields
- CMR works in the heart

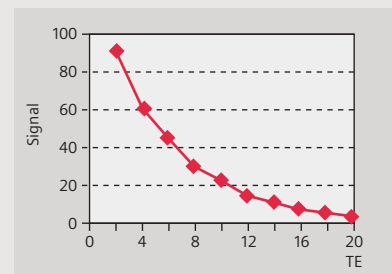


Previous MR Heart Techniques

- **Signal intensity ratios**
 - Based on relaxation of tissues
 - Subject to noise
 - Poor reproducibility and sequence sensitive
- **T2 relaxation**
 - Based on spin echo technique
 - Low iron = long echo times with poor imaging
 - High iron = short echo times, difficult
 - Motion sensitive

T2* CMR

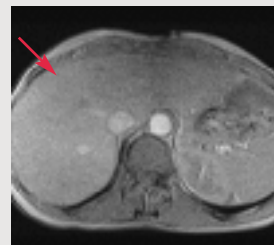- **T2* relaxation**
 - Based on gradient echo technique
 - Sensitive
 - Widely used in CMR
 - Echo times shorter than T2 but
 - Easier to obtain
 - Fast to acquire
 - Robust to cardiac motion
 - Good quality images at all echo times



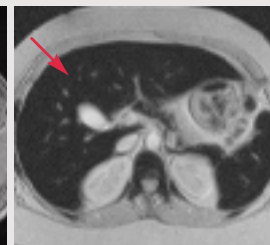$$\text{Signal} = K e^{-TE/T2^*}$$

TR constant and stretch the TE up to 17 ms and measure the signal at the level of the septum.

Tissue Appearances in Iron Overload

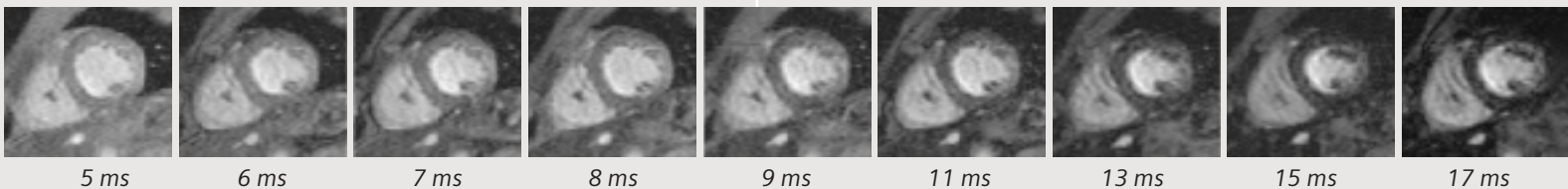


Normal Volunteer



Severe Iron Overload

Deriving Myocardial T2*





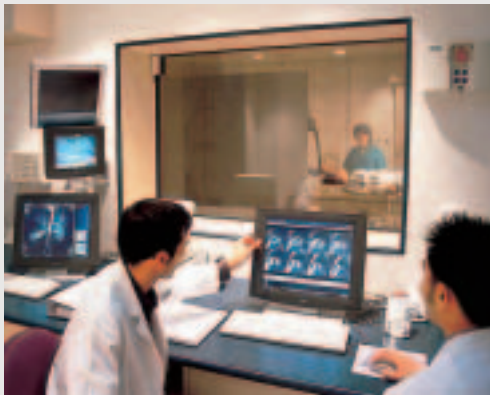Dr. Ching Hon Luk, from the Sir Run Run Shaw Heart Center, presented information about his clinic in Hong Kong where more than 20 cardiologists work together. He explained the interesting development of the center as a successful private Cardiac MRI Center in Hong Kong. He observed that Cardiac MRI was already a very robust diagnostic tool which could be used in a private practice such as his. He said that examination time would not exceed 45-60 minutes – an acceptable range for private practice.



St. Teresa's Hospital



The Heart Center



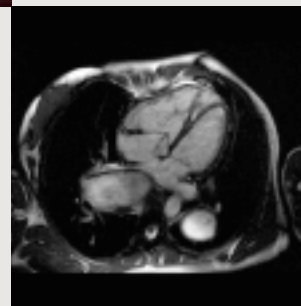
The Sir Run Run Shaw Center is affiliated with 20 cardiologists from St. Teresa's Hospital, a private center with 600 beds. The center is open ~55 hrs (6 days) per week.

The number of MRI exams with state of the art MAGNETOM Sonata system in 19 months (Nov 02 – May 04) is 3056 in total. 61% of the exams (1875) are cardiac MR. Cardiologists and radiologists work together in the clinic.

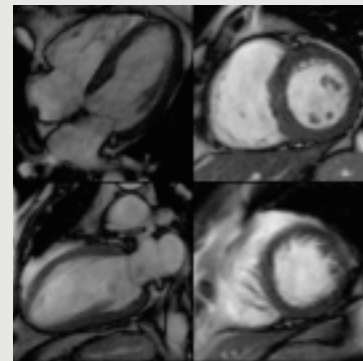
Cardiac MR – the “One-Stop Shop”

- Anatomy – tumors, mass, congenital diseases, ...
- Function – wall motion: global and regional
- Perfusion* – ischemic heart diseases, ...
- Viability* – ischemic heart diseases, cardiomyopathy, ...
- Great Vessels – dissection, stenosis, ...
- Coronary arteries – anomalous coronaries, ...

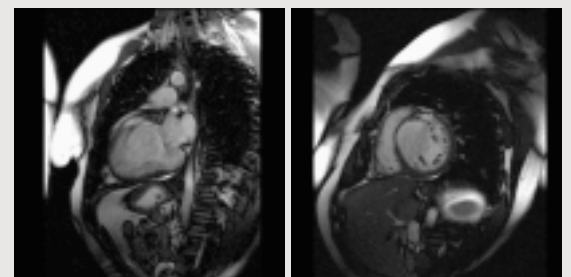
Dr. Ching Hon Luk sees cardiac MR as a one stop shop for cardiac diseases.



Anatomy – Cardiac Structure: Dilated right atrium (RA) and right ventricle (RV) due to atrial septal defect of secundum type. RV hypertrophy and impaired RV function with paradoxical septum movement as sign of RV impairment.



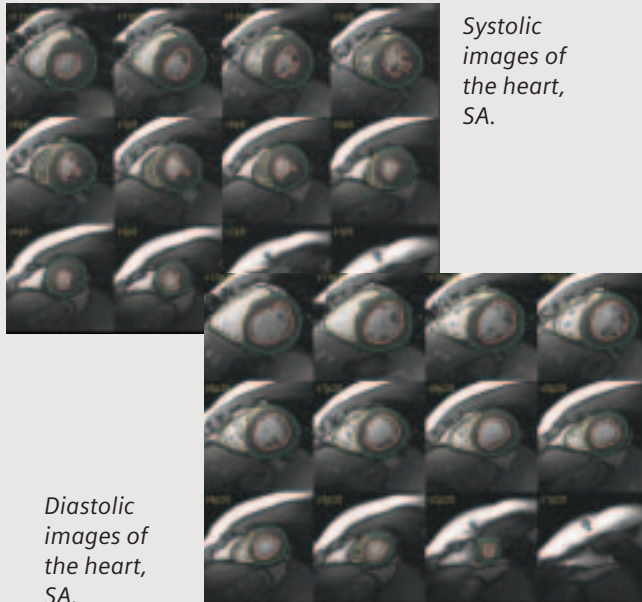
Hypertrophy, normal wall motion.



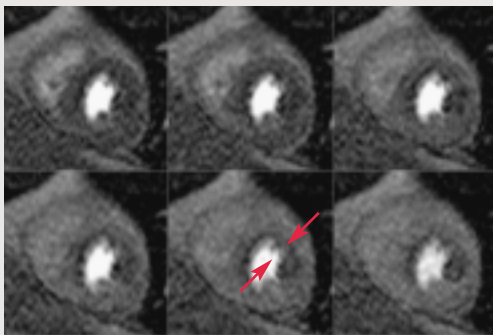
Heart failure with severe mitral regurgitation.

*WIP: The information about this product is preliminary. The product is under development and is not commercially available in the U.S., and its future availability cannot be assured.

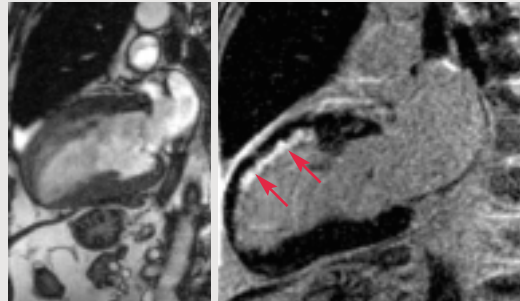
Cardiac Function – Quantification



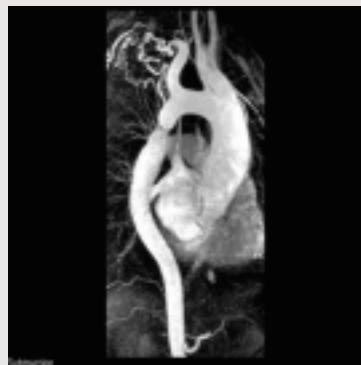Midventricular slice at stress



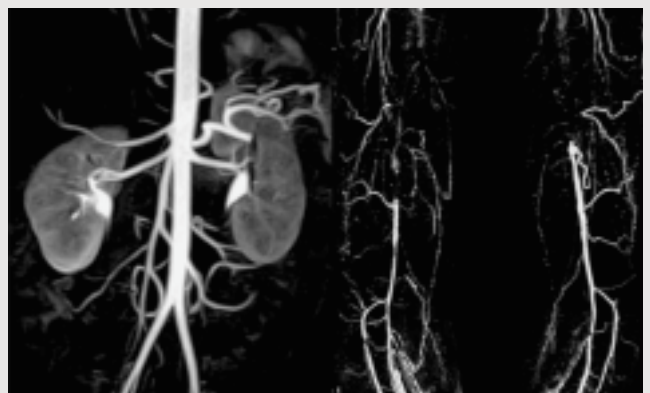
Subendocardial ischemia



Viability* imaging – infarcts: hypokinetic wall motion caused by subendocardial anterior infarct.



Vascular imaging: aortic coarctation.

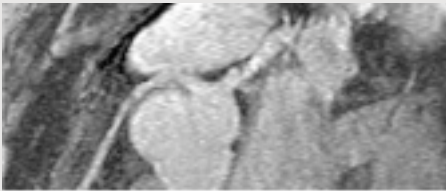


512 matrix high resolution MRA.

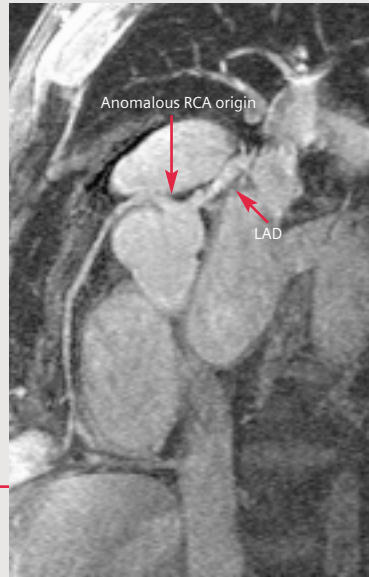Vascular imaging – renal and peripheral MRA.

*WIP: The information about this product is preliminary. The product is under development and is not commercially available in the U.S., and its future availability cannot be assured.

Coronary artery imaging –
screening anomalous coronaries.



Relevant anatomy
Courtesy of Northwestern University



RCA in full length
Courtesy of Northwestern University

A Typical Ischemic Heart Disease Exam Protocol in Sir Run Run Shaw Heart Center

Steps	Imaging protocol
1	Localizers + chest scout (multi-breathhold T2W HASTE)
2	4-chamber cine
3	First pass perfusion imaging* (stress / rest)
4	Multislice cine imaging (SAs, LA, LVOT, RVOT)
5	First pass perfusion imaging* (rest/stress)
6	Breathhold coronary MRA to scout origins of RCA and LM
7	TI scouting
8	Multislice infarct imaging (SAs, LA, LVOT, RVOT, 4-chamber)

**WIP: The information about this product is preliminary. The product is under development and is not commercially available in the U.S., and its future availability cannot be assured.*

The information in this document contains general descriptions of the technical options available, which do not always have to be present in individual cases.

The required features should therefore be specified in each individual case at the time of closing the contract.

Siemens reserves the right to modify the design and specifications contained herein without prior notice. Please contact your local Siemens sales representative for the most current information.

Original images always lose a certain amount of detail when reproduced.

This brochure refers to both standard and optional features. Availability and packaging of options varies by country and is subject to change without notice. Some of the features described are not available for commercial distribution in the US.

Siemens AG
Wittelsbacherplatz 2
D-80333 Muenchen
Germany

Headquarters

Siemens AG, Medical Solutions
Henkestr. 127, D-91052 Erlangen
Germany
Telephone: +49 9131 84-0
www.siemens.com/medical

Contact Addresses

In the USA

Siemens Medical Solutions USA, Inc.
51 Valley Stream Parkway
Malvern, PA 19355
Telephone: +1 888-826-9702
Telephone: +1 610-448-4500
Telefax: +1 610-448-2254

In Japan

Siemens-Asahi
Medical Technologies Ltd.
Takanawa Park Tower 14F
20-14, Higashi-Gotanda 3-chome
Shinagawa-ku
Tokyo 141-8644
Telephone: +81 3 5423 8411

In Asia

Siemens Medical Solutions
Asia Pacific Headquarters
The Siemens Center
60 MacPherson Road
Singapore 348615
Telephone: +65 6490-6000
Telefax: +65 6490-6001

In Germany

Siemens AG, Medical Solutions
Magnetic Resonance
Henkestr. 127, D-91052 Erlangen
Germany
Telephone: +49 9131 84-0

Siemens **Medical**
Solutions that help