3D Navigator-Gated, Inversion Recovery FLASH (Nav_IR_Flash) with Blood Pool Contrast Agent

Marci Messina, RT(R)(MR)[1]; Cynthia Rigsby, M.D.[1]; Jie Deng, Ph.D.[1]; Xiaoming Bi, Ph.D.[2]; Gary McNeal, MSBME[2]

[1] Medical Imaging, Ann & Robert H. Lurie Children's Hospital of Chicago, Chicago, IL, USA
[2] Siemens Healthcare, Cardiovascular MR R&D

Objectives

The purpose of this article is to explain how we have maximized image quality for our contrast-enhanced 3D acquisitions for MR angiography (MRA) applications in pediatric* patients using a blood pool contrast agent.

Materials and methods

Pediatric MRA requires high spatial resolution due to small patient size. Coronary imaging presents a significant challenge in young children due to small vessel size and high heart rate. Quick pediatric circulation times also present a challenge in performing MRA examinations in children with extracellular contrast agent as there is only one chance to obtain images prior to the contrast moving out of the vasculature.

TWIST images provide time-resolved, dynamic information of 3D vascular structures. Nav_IR_Flash can supplement it by providing 3D images at much higher spatial resolution acquired with navigator-gating and ECG-triggering. The utilization of a blood pool agent facilitates dynamic TWIST imaging during the first pass and Nav_IR_Flash imaging during the equilibrium state of contrast kinetics without compromising each other. Compared to TrueFISP readout, FLASH readout is not sensitive to signal drop out from off-resonance and/or fast flow, particularly in the setting of pediatric imaging. Overall, in combination with high relaxativity contrast media and inversion preparation, Nav_IR_Flash provides reliable image quality with excellent imaging contrast between blood signals and background tissues.

Coronary imaging is the most challenging exam in small children and it is difficult to obtain reliable images using the standard T2-prepared TrueFISP sequence. We therefore chose to pursue Nav_IR_Flash technique by administering a blood pool contrast agent, gadofosveset trisodium (Ablavar®, Lantheus Medical

1 Coil selection and setup for different size of patient.

*MR scanning has not been established as safe for imaging fetuses and infants under two years of age. The responsible physician must evaluate the benefit of the MRI examination in comparison to other imaging procedures.

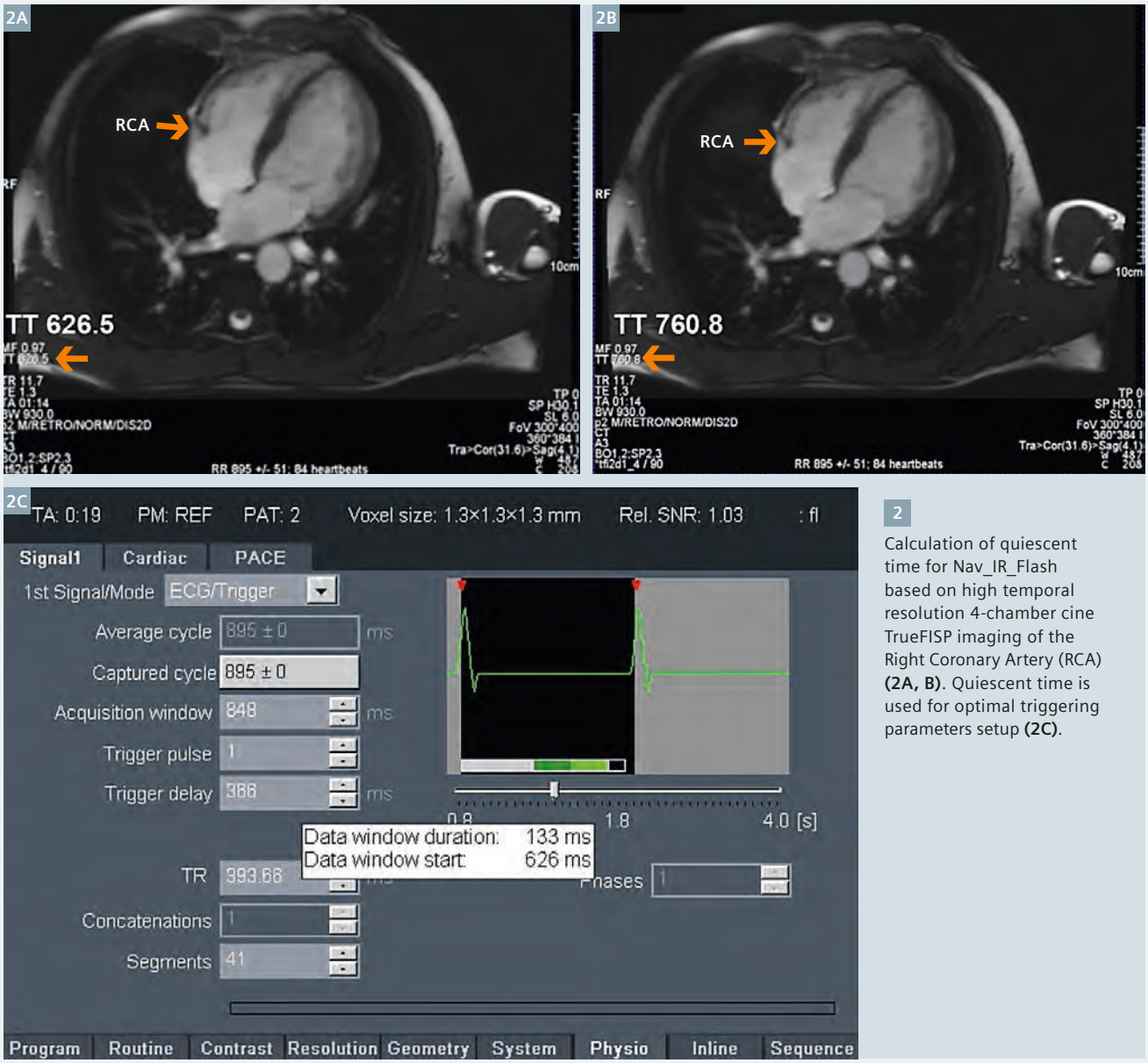

2

Calculation of quiescent time for Nav_IR_Flash based on high temporal resolution 4-chamber cine TrueFISP imaging of the Right Coronary Artery (RCA) **(2A, B)**. Quiescent time is used for optimal triggering parameters setup **(2C)**.

Imaging, Inc. MA, USA). This contrast agent remains within the blood pool for several hours after administration. The prolonged presence of the blood pool agent facilitates repeated imaging if there is patient motion, allows for higher resolution imaging in coronary imaging, and makes it possible to image multiple body parts after injection. These benefits are all ideal for scanning pediatric patients. We acquire the IR FLASH sequence with near isotropic voxels, allowing for reconstructions in any plane making this MR sequence much like CT, but without the radiation penalty.

Methods and procedures

Patient preparation

Communication between the technologist and patient are vital to achieving a successful pediatric imaging study. When imaging a young patient without the use of sedation, it is best to keep the instructions simple, but direct. Assure the patient with positive encouragement, for example "I know you can do this. We will work through this together". Make the patient comfortable by adding swaddling materials and knee cushions when possible. Offer music or a movie for entertainment during the exam if available.

Steady respiratory and heart rates and limited body movement are key to high quality images, especially for coronary imaging. When imaging a patient under general anesthesia, the patient should fast for up to 8 hours. More specifically, two hours for water, four hours for breast milk, six hours for formula and eight hours for solid food per anesthesia protocol. Communication between the MRI and anesthesiology teams is vital. If apnea (breath-hold) is needed, the patient will need to be intubated and paralyzed. If apnea is not necessary,

other methods of sedation can be utilized.

Coil selection
Selection of the coil that closely matches the patient size and predicted imaging field-of-view is important for maximizing MR signal. For imaging the pediatric cardiovascular system, we select from four available coils. We have dedicated protocols for each of these coils, with isotropic resolution optimized to the patient size. Higher resolution protocols were also built for coronary origin imaging (Table 1).

Special purpose (4-channel array) coil works best with neonates and infants under 10 kg weight (Fig. 1A), and two such coils may be applied in a clamshell configuration (Fig. 1B).

Small Flex (4-channel array) coil works best for infants over 10 kg weight.

Large Flex (4-channel array) coils work best for toddlers and small children, and these may be combined with a posterior spine array coil (Fig. 1D).

Another option for toddler size is to use two special purpose coils, both anterior in combination with the posterior spine array coil (Fig. 1C).

Body Matrix (18-channel array) coils work best for large children through adult-sized patients and this may be combined with a posterior spine array coil (Fig. 1E).

Contrast administration
Using a power injector with right antecubital 22 gauge or larger IV, we administer a single dose of Ablavar (0.03 mmol/kg or 0.12 ml/kg) at a rate of 2.5–3.0 ml/s, followed by a sterile saline flush of 1 ml/kg (up to max 10 ml). We perform TWIST dynamic imaging during the contrast injection, followed by the 3D Nav_IR_Flash imaging within 15 minutes (up to an hour) [1] for optimal vascular contrast enhancement.

Exam protocol
All imaging is performed on a 1.5T MAGNETOM Aera scanner (Siemens Healthcare, Erlangen, Germany).

Workflow for cardiovascular MRA exam:

1. 3 plane TrueFISP breath-hold localizers
2. Interactive real-time TrueFISP to locate and save a clear 4-chamber view
3. Single slice 4-chamber high temporal resolution cine TrueFISP imaging for calculation of quiescent time. It is acquired during free breathing with 3–4 averages (60 true cardiac phases per heart beat). Scroll through the cine images in the viewer card to find the optimal trigger time in the cardiac cycle when the coronaries are most stationary (located in the atrioventricular grooves). Often the quiescent period is found in diastole for lower heart rates (50–80 bpm) and systole for higher heart rates (80+ bpm). The trigger time (TT) of each frame is located on the lower left corner of the image text. Mark the two specific TT's at the start and end times of the quiescent period in the cardiac cycle. These two specific TT's will be used to set up the timing parameters for the Nav_IR_Flash. Figures 2A and 2B show one example of setting up the quiescent time for Nav_IR_Flash.
4. Ablavar administration
5. Coronal dynamic TWIST imaging (temporal resolution 2.5 s/frame)
6. 3D Nav_IR_Flash_TI_260_Coronal/Axial Oblique. This sequence is scanned after the single dose injection on TWIST sequence. Figure 2C shows the optimal trigger parameter adjustments to acquire data during the quiescent period.

Imaging can be performed at 3T. Alteration in the protocol for 3T imaging includes changing the inversion-recovery time (TI) to 350 ms and flip angle to 15 degrees.

Setting up the Nav_IR_Flash sequence:

A. Plan from all 3 plane breath-hold localizers

B. The Nav_IR_Flash sequence can be converted from the T2-prepared TrueFISP sequence by following the parameters in Table 1.

C. In the Physio tab begin with clicking on capture cycle, then adjust the number of segments to reach the desired data window duration time, and then adjust the trigger delay to reach the desired data window start time. Hover over the trigger delay with cursor to see the changes in the tooltips popup. For example, if the quiet period of the cardiac cycle (from the high resolution free breathing 4-chamber cine image) is from TT 626 to TT 759, then the data window start time should be set to 626 and the data window duration should be set to 133 (Fig. 2C).

D. Place the intersection of the cross-pair navigators in the middle of the dome of the liver as viewed from the axial localizer (Fig. 3A). Then right-click, perpendicular from the axial image to find the navigator on the corresponding sagittal and coronal planes to verify its optimal location centered at the level of the diaphragm (Figs. 3B, C). Working on the axial plane, one can slightly rotate the oblique navigator away from the heart if it crosses anatomy; however must not rotate the orthogonal navigator (aligned in anterior-posterior direction). 'Couple graphics' should be 'off' for the dual navigator set up.

E. Before starting the scan, first run the sequence in scout mode, check the 'Scout mode' box in Physio-PACE card (Fig. 3G). Open the Inline Display window during the scout mode to get the position histogram, 'mode number' (Figs. 3D, E). Next, apply the mode number into the 'search position (red)' and uncheck the scout mode to run the full scan. When viewing the navigator signal within the Inline Display window, the green bar (Accept

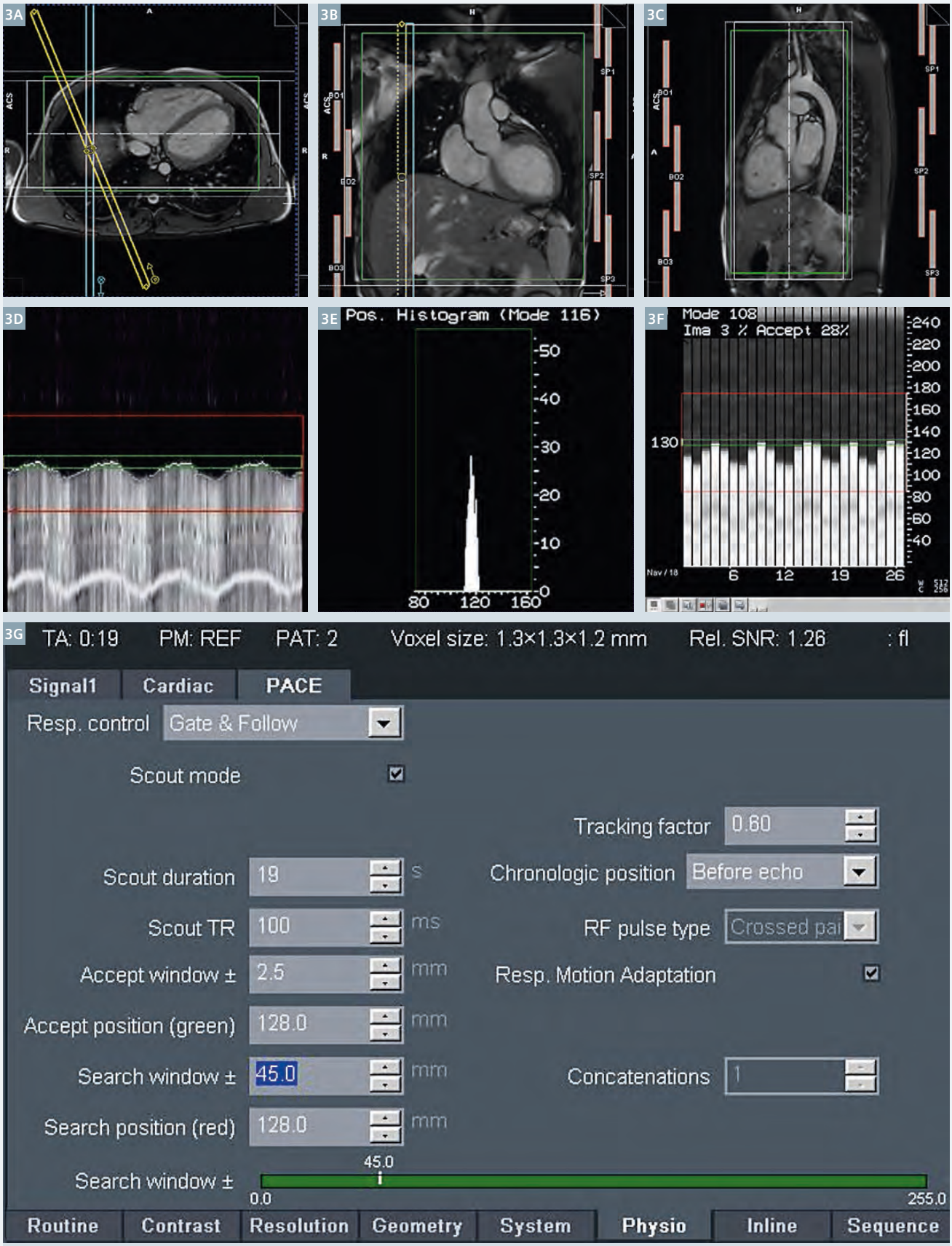

3 Cross-pair navigator positioning **(3A–C)**. Navigator scout **(3D)** gives position histogram for 'Mode number' **(3E)** calculation, to determine the 'search postion (red)' for optimal navigator waveform during Nav_IR_Flash acquistion **(3F)**.

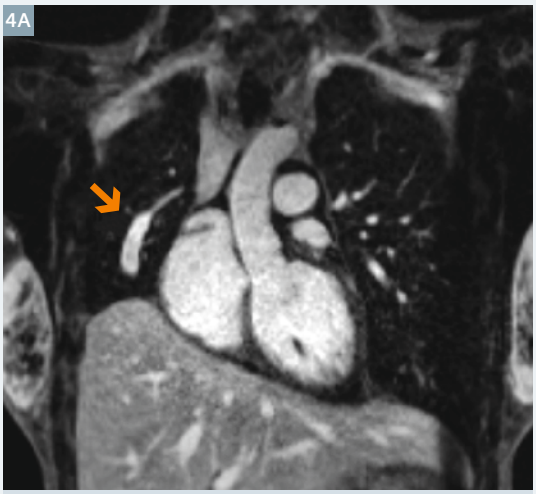

4 Coronal Nav_IR_Flash image **(4A)** and 3D reformat **(4B)** of the scimitar vein (arrow) in a teen patient.

5 Coronal MIP of Nav_IR_Flash cardiovascular image in a neonatal patient with moderately hypoplastic RPA (arrow).

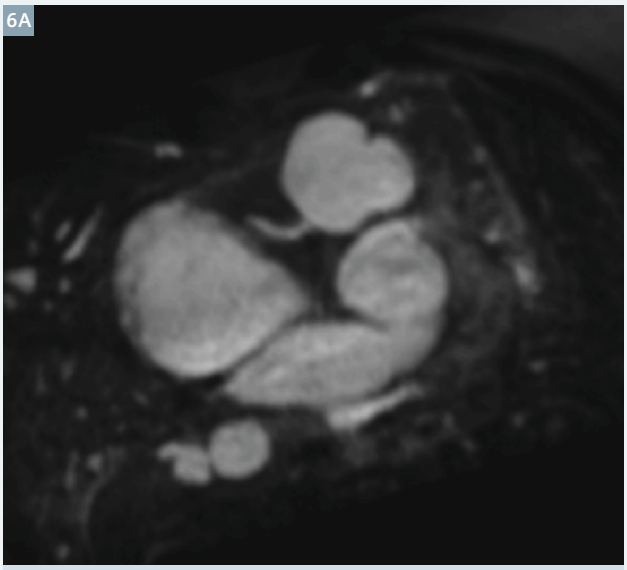

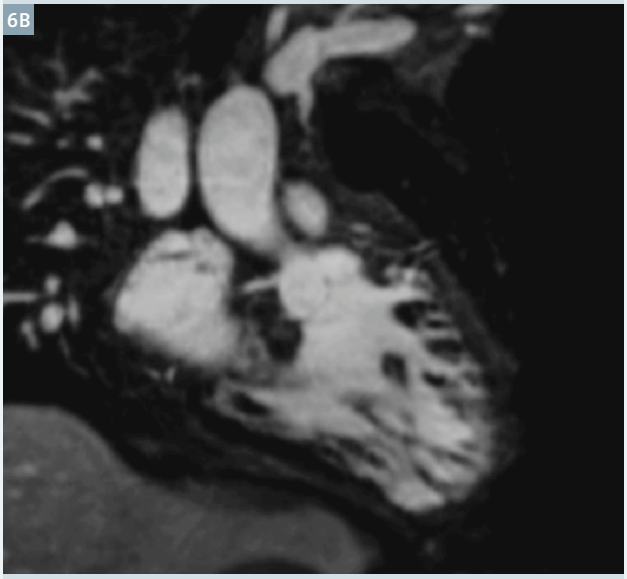

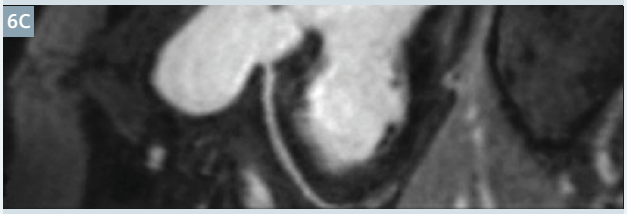

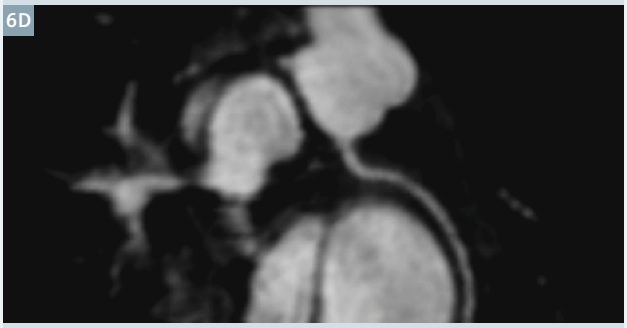

6 Oblique thin-MIP's **(6A, B)** and curved thin-MIP's **(6C, D)** of the coronary vessels acquired by Nav_IR_Flash sequence in a 24-month-old toddler.

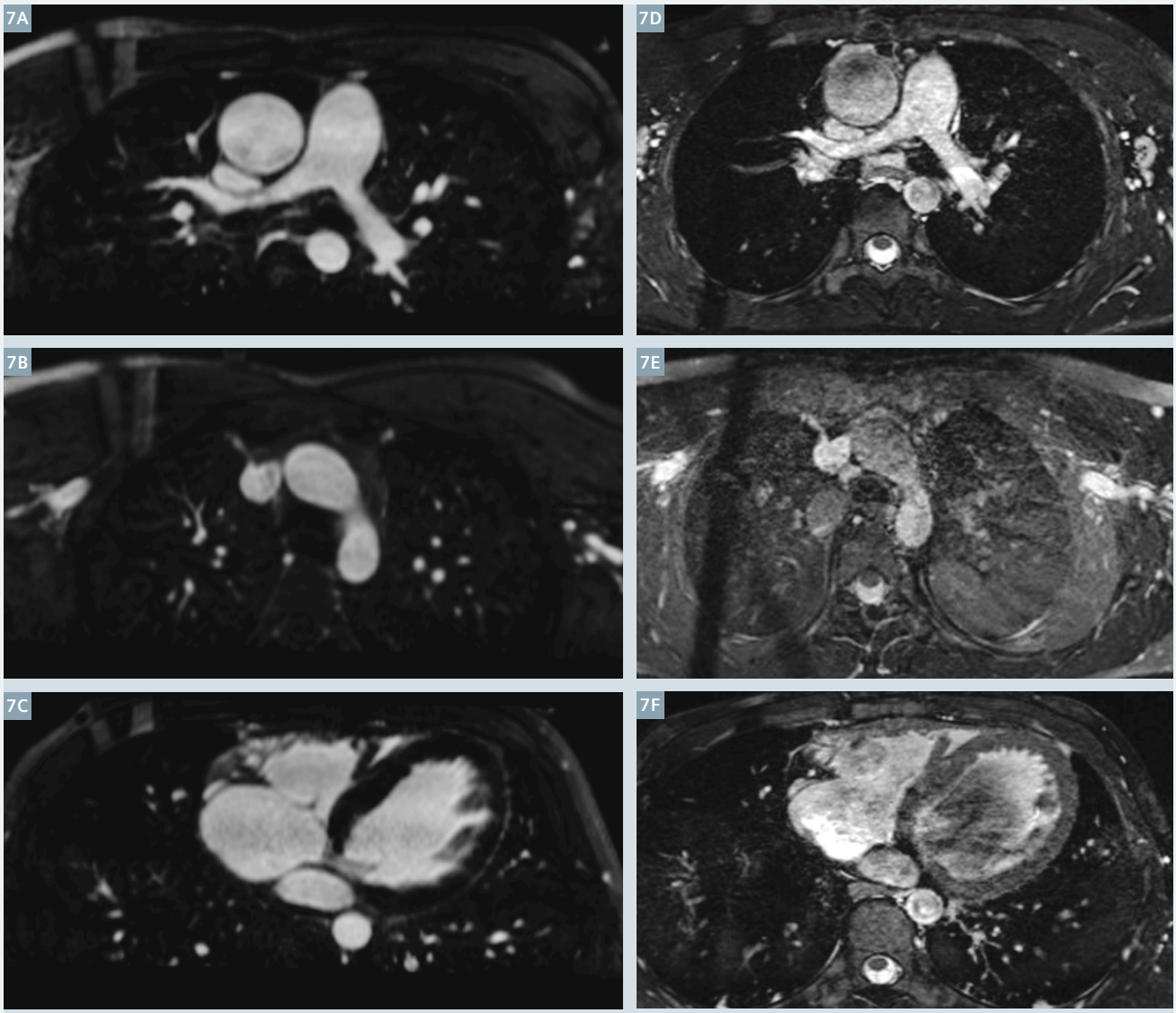

7 Comparison of 3D Nav_IR_Flash post Ablavar **(7A–C)** and Nav_T2-prepared SSFP post Magnevist **(7D–F)** in the same patient on two exam dates.

Window) should be centered at the end-expiratory peaks of the respiratory waveform (Fig. 3F). An acceptance window of ±2.5 mm is typically used with 'Respiratory Motion Adaption' selected to ensure that the scan completes even if the patient's respirations are inconsistent.

Results

Figure 4 shows a coronal Nav_IR_Flash image in a teen patient using body matrix and spine coils. This patient has relative mesocardia, apex leftward, related to right lung hypoplasia. Hypoplastic right lung associated with elevation of the right hemidiaphragm and right shift of the mediastinum are consistent with scimitar syndrome.

Figure 5 shows coronal MIP of Nav_IR_Flash cardiovascular image in a neonatal patient using special purpose coil. This patient has moderately hypoplastic RPA with proximal RPA stenosis.

Figure 6 shows oblique coronal MIP and 3D reformat images of the coronary vessels acquired by Nav_IR_Flash sequence in a 24-month-old toddler, using small flex phased array and spine coil. Post Senning atrial switch repair of D-looped TGA are seen. Mild dilatation and moderate hypertrophy of the systemic morphologic right ventricle.

Figure 7 demonstrates the comparison of image quality of 3D Nav_IR_Flash post Ablavar (7A–C) and Nav_T2-prepared SSFP post Magnevist (7D–F) in the same patient on two exam dates. Nav_IR_Flash provided superior image quality with better SNR and reduced susceptibility artifacts compared to TrueFISP.

Table 1: Resolution parameters for Nav_IR_Flash for large vessels (upper section), for coronary vessels (middle section), and for coil/sequence parameters for all vessels (lower section).

Acquisition parameters	Patient size			
Large Vessel (Coronal plane)	**Neonate/Infant**	**Toddler**	**Pediatric/ Small Teen**	**Large Teen/Adult**
FOV (mm × mm × mm)	220 × 165 × 70	280 × 151 × 93	300 × 177 × 123	340 × 204 × 132
Acquired Resolution (mm × mm × mm)	1.1 × 1.1 × 1.5	1.3 × 1.3 × 2.4	1.4 × 1.4 × 2.4	1.5 × 1.5 × 2.5
Reconstructed Resolution (mm × mm × mm)	1.1 × 1.1 × 1.1	1.3 × 1.3 × 1.3	1.4 × 1.4 × 1.4	1.5 × 1.5 × 1.5
Matrix	192 × 192	224 × 224	208 × 208	224 × 208
Coronary (Axial Oblique Plane)	**Neonate/Infant**	**Toddler**	**Pediatric/ Small Teen**	**Large Teen/Adult**
FOV (mm × mm × mm)	190 × 190 × 30	250 × 206 × 30	300 × 243 × 40	300 × 243 × 40
Acquired Resolution (mm × mm × mm)	0.9 × 0.9 × 1.32	0.9 × 0.9 × 1.32	0.9 × 0.9 × 1.41	0.9 × 0.9 × 1.67
Reconstructed Resolution (mm × mm × mm)	0.9 × 0.9 × 1.0	0.9 × 0.9 × 1.0	0.9 × 0.9 × 1.0	0.9 × 0.9 × 1.0
Matrix	192 × 192	256 × 256	320 × 320	320 × 320
Coil	Special or Small Flex	Small or Large Flex	Large Flex or Body Matrix	Body Matrix
TI (Inversion Time)	260	260	260	260
FA (Flip Angle)	18	18	18	18
TE (ms)	1.45	1.39	1.41	1.28
TR (ms)	405	405	405	405
Echo Spacing (ms)	3.45	3.38	3.42	3.18

Summary

The desire for high quality imaging and the goal to minimize radiation doses continues to bring cardiovascular imaging referrals to MRI. The 3D Nav_IR_Flash sequence paired with blood pool contrast agent – gadofosveset trisodium (Ablavar) are beneficial imaging options to evaluate complex cardiac indications in pediatric patients.

Acknowledgments

We would like to thank the cardiovascular MRI team at Ann & Robert H. Lurie Children's Hospital, for their advanced practice and knowledge in implementing this protocol. We would also like to thank Shivraman Giri, Ph.D., Senior Scientist, Cardiovascular MR R&D Siemens Healthcare, for his help with this article.

Reference

1 http://www.ablavar.com/mra-agent.html

Contact

Marci Messina, RT(R)(MR)
Medical Imaging
Ann & Robert H. Lurie Children's Hospital of Chicago
225 E. Chicago Avenue
Chicago, Illinois 60611
USA
MMessina@luriechildrens.org