Combined ^{18}F-FDG PET and MRI Evaluation of a case of Hypertrophic Cardiomyopathy Using Simultaneous MR-PET

Ihn-ho Cho, M.D.; Eun-jung Kong, M.D.

Department of Nuclear Medicine, Yeungnam University Hospital, Daegu, South Korea

Introduction

Hypertrophic cardiomyopathy (HCM) is a common condition causing left ventricular outflow obstruction, as well as cardiac arrhythmias. Cardiac MRI is a key modality for evaluation of HCM. Apart from estimating left ventricular (LV) wall thickness, LV function and aortic flow, MRI is capable of estimating the late gadolinium enhancement in affected myocardium, which has been shown to have a direct correlation with incidence and severity of arrhythmias in HCM [1]. In patients with HCM, late gadolinium enhancement (LGE) on CE-MRI is presumed to represent intramyocardial fibrosis. PET myocardial perfusion studies have shown slight impairment of myocardial blood flow with pharmacological stress in hypertrophic myocardium in HCM, presumably related to microvascular disease [2]. ^{18}F-FDG PET has been sporadically studied in HCM, mostly for evaluation of the metabolic status of the hypertrophic myocardial segment, especially after interventions such as transcoronary ablation of septal hypertrophy (TASH) [3] or to demonstrate partial myocardial fibrosis [4]. This clinical example illustrates the value of integrated simultaneous ^{18}F-FDG PET and MRI acquisition performed on the Biograph mMR system.

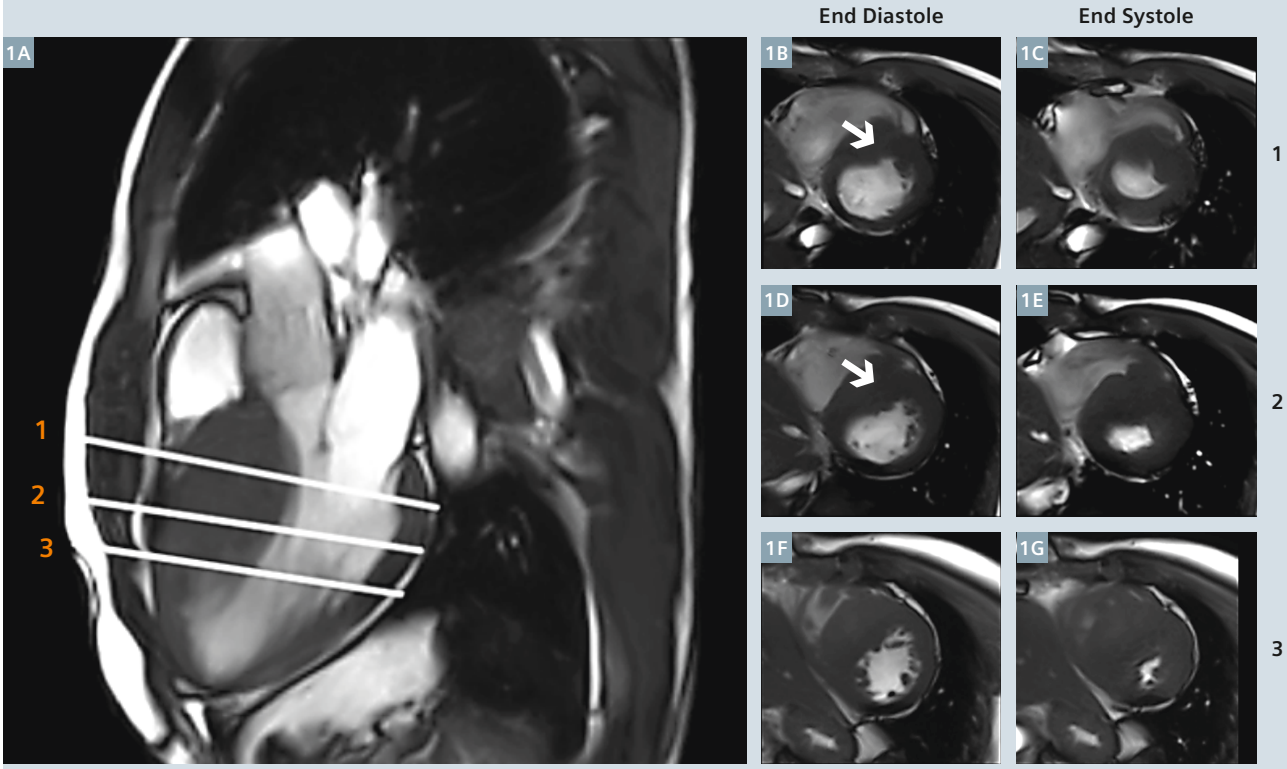

1 Short-axis views of end diastole and end systole at 3 different sections in the left ventricle obtained from gated TrueFISP cine MRI acquisitions performed on Biograph mMR. Note the thick hypertrophic septum (white arrow), which demonstrates the degree of asymmetric septal hypertrophy.

Patient history

A 25-year-old man presented to the cardiology department with incidental ECG abnormality after fractures to his left 2nd and 4th fingers. Although he had not consulted a doctor, he had been suffering from mild dyspnea with chest discomfort at rest and exacerbation at exercise since May 2012. Echocardiography revealed non-obstructive hypertrophic cardiomyopathy (Maron III) with trivial MR. The patient was referred for a simultaneous MR-PET study for ^{18}F-FDG PET and cardiac MRI with Gadolinium (Gd) contrast for evaluation of the morphological and metabolic status of the hypertrophic myocardium.

The patient was injected with 10 mCi ^{18}F-FDG following glucose loading. Simultaneous MR-PET study performed on a Biograph mMR was started one hour following tracer injection. Following standard Dixon sequence acquisition for attenuation correction, the comprehensive cardiac MRI sequences were acquired including MR perfusion after Gd contrast infusion, as well as post contrast late Gd enhancement studies. Static ^{18}F-FDG PET was acquired simultaneously during the MRI acquisition.

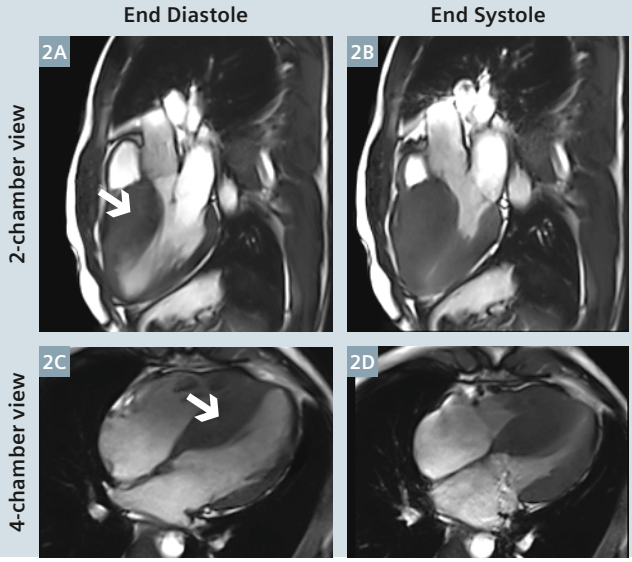

2

End diastolic and end systolic views of 2-chamber and 4-chamber views obtained from gated cine TrueFISP acquisitions showing thickness of the asymmetric septal hypertrophy (white arrow).

Discussion

The late Gd enhancement within the hypertrophic septum along with the non-uniform glucose metabolism demonstrated by the patchy ^{18}F-FDG uptake within the hypertrophic septum exactly corresponding to the area of Gd enhancement reflect myocardial fibrosis within the asymmetric septal hypertrophy. Myocardial fibrosis and the presence of late Gd enhancement on MRI has been shown to be associated with increased risk of cardiac arrhythmia [1] as evident from the symptoms of this patient.

Simultaneous MR-PET acquisition provides combined acquisition of both modalities, thereby ensuring accurate fusion between morphological and functional images due to simultaneous PET acquisition for every MR sequence. The exact coregistration of the patchy ^{18}F-FDG uptake in the area of Gd enhancement within the hypertrophic upper septum reflects the advantage of simultaneous acquisition.

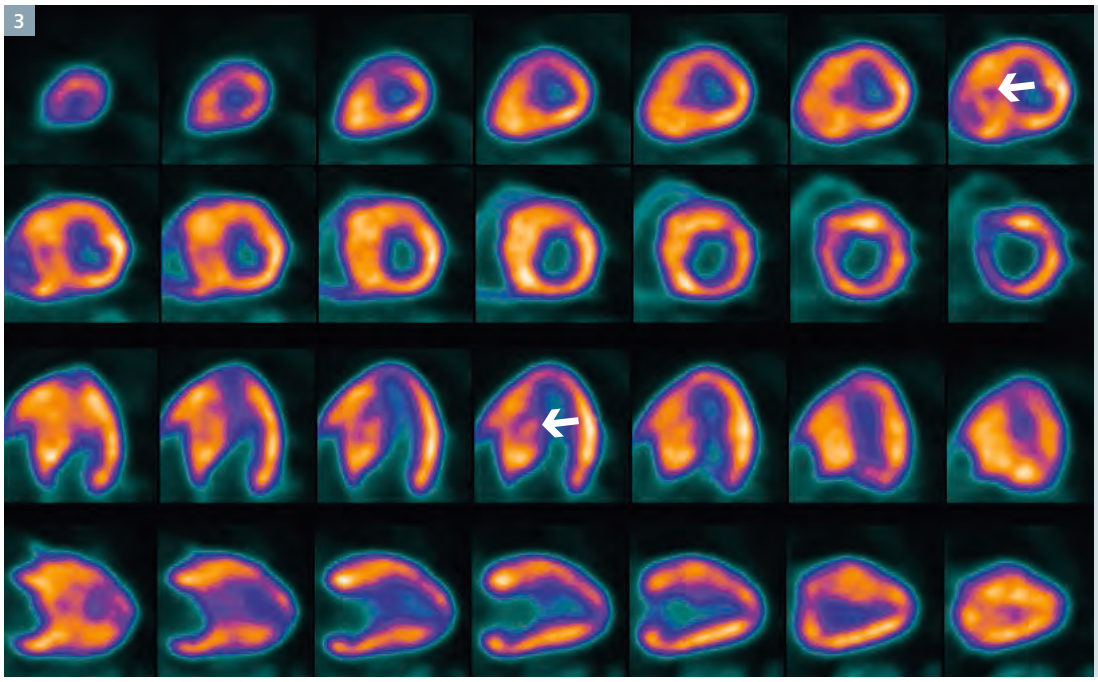

3

Static ^{18}F-FDG PET images in short-axis, horizontal long-axis and vertical long-axis views demonstrating normal uptake in the LV myocardium except the non-uniform uptake pattern in the hypertrophied septum (white arrows). LV cavity size appears normal.

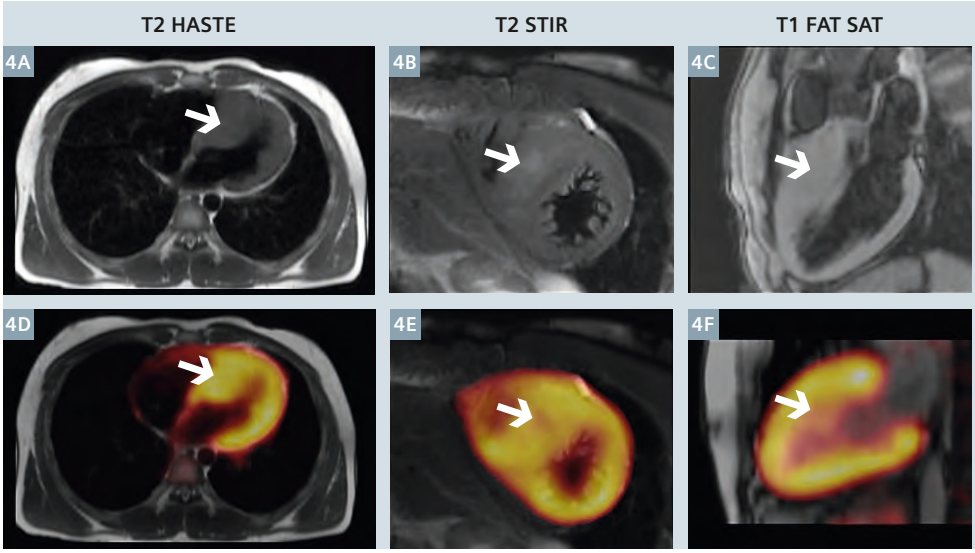

4

Transverse, short-axis and vertical long-axis MR and fused MR-PET images show hypertrophied septum (white arrows) and normal thickness of rest of left ventricular myocardium with corresponding normal ^{18}F-FDG uptake. The T2-weighted STIR (fat suppression) image shows slight hyperintensity in the middle of the hypertrophied septum which shows corresponding non-uniformity in ^{18}F-FDG uptake.

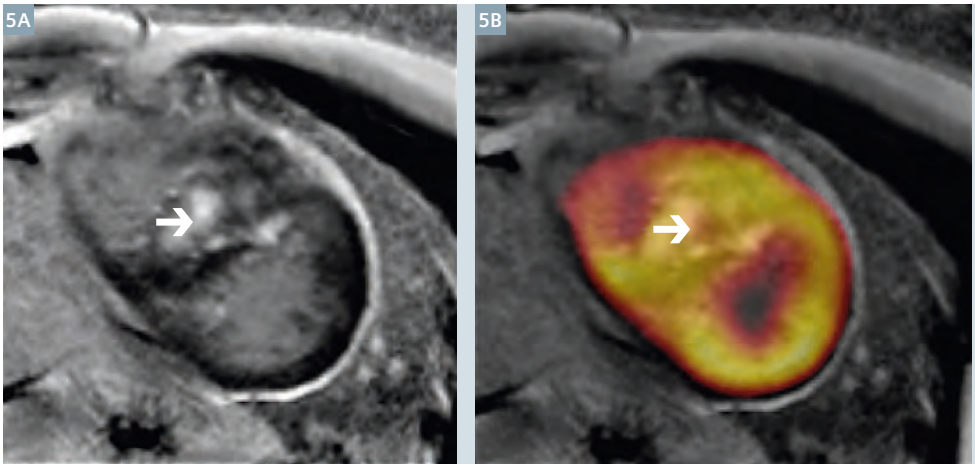

5

Post-contrast MR short-axis images demonstrate late Gd enhancement within the hypertrophied septum (white arrow), which shows corresponding non-uniform patchy uptake of ^{18}F-FDG.

References

1 Rubinstein et al. Characteristics and Clinical Significance of Late Gadolinium Enhancement by Contrast-Enhanced Magnetic Resonance Imaging in Patients With Hypertrophic Cardiomyopathy. Circ Heart Fail. 2010;3:51-58.

2 Bravo et al. PET/CT Assessment of Symptomatic Individuals with Obstructive and Nonobstructive Hypertrophic Cardiomyopathy. J Nucl Med 2012; 53:407–414.

3 Kuhn et al. Changes in the left ventricular outflow tract after transcoronary ablation of septal hypertrophy (TASH) for hypertrophic obstructive cardiomyopathy as assessed by transoesophageal echocardiography and by measuring myocardial glucose utilization and. perfusion. European Heart Journal (1999) 20, 1808–1817.

4 Funabashi N et al. Partial myocardial fibrosis in hypertrophic cardiomyopathy demonstrated by ^{18}F-fluoro-deoxy-glucose positron emission tomography and multislice computed tomography. Int J Cardiol. 2006 Feb 15;107(2):284-6.

Contact

Ihn-ho Cho, M.D.
Department of Nuclear Medicine
Yeungnam University
College of Medicine
Daegu Hyunchungro 170
South Korea
nuclear126@ynu.ac.kr