Experience with the 3 Tesla MAGNETOM Verio system in Spine Imaging: Benefit of 3D Sequences and Reduction of Metal-Related Artifacts with the *syngo* WARP WIP-package

Marcel Wolf, M.D.[1]; Marc-André Weber, M.D., M.Sc.[2]

[1]*Department of Neuroradiology, University Hospital Heidelberg, Germany*
[2]*Department of Diagnostic and Interventional Radiology, University Hospital Heidelberg, Germany*

Spine imaging in posttraumatic and paraplegic patients has great demands on the MRI scanner and pulse sequences. At our institution, the Department of Diagnostic and Interventional Radiology within the Department of Orthopedics, Traumatology and Spinal Cord Injury Center, MR imaging of the spine is paramount in daily routine. We use the 3 Tesla MAGNETOM Verio system, offering several advantages for patient comfort and radiological requirements.
The advantages of 3 Tesla especially for orthopedic imaging are well known: increase in signal-to-noise ratio (SNR) and less prominent effect of B_1 inhomogeneity on image quality results in clearly improved image quality and/or faster scan times. Visualizing the whole spine in a single examination requires relatively fast protocols, facilitated by the short acquisition times.
The relatively wide 70 cm open-bore of the 3 Tesla MAGNETOM Verio system enables a very flexible positioning of patients, being crucial for those suffering from hemi- or paraplegia, scoliosis, contractions and/or obesity (Fig. 1).
3D sequences like *syngo* SPACE (Sampling Perfection with Application

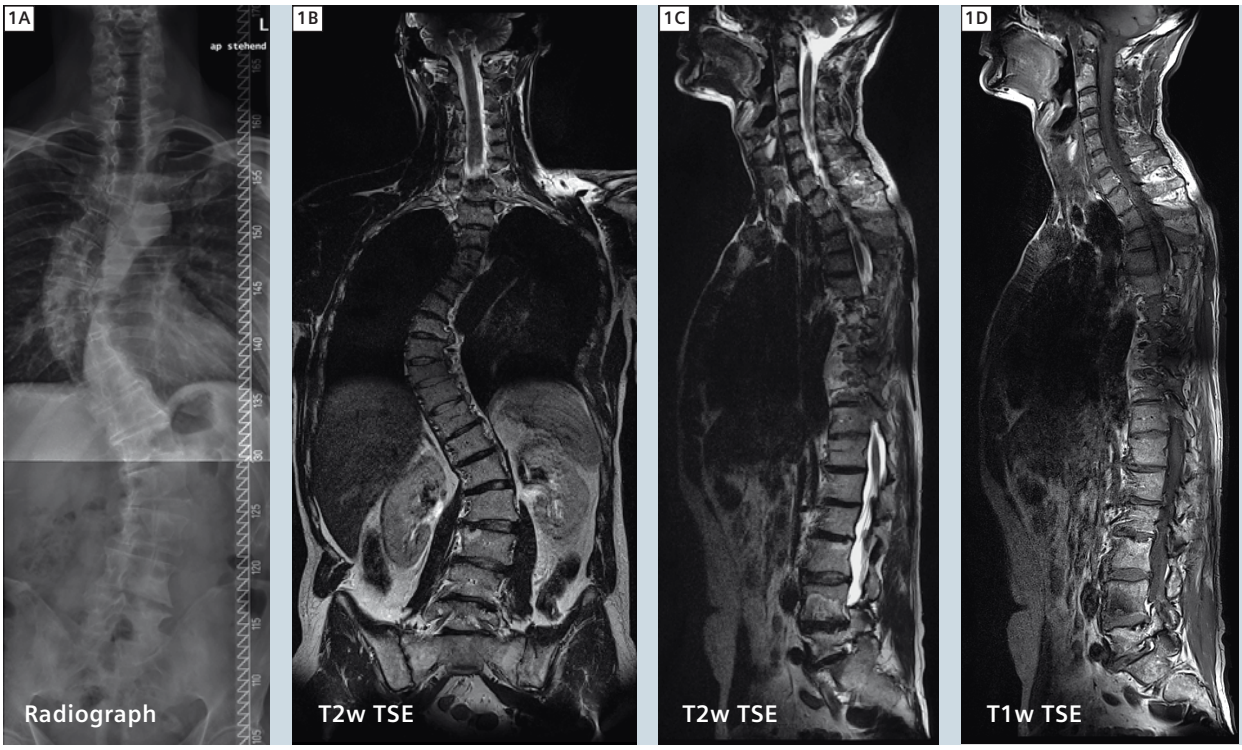

1 Severe scoliosis.

optimized Contrasts using different flip angle Evolution) (Figs. 2 and 3) or CISS (Constructive Interference in Steady State (Fig. 4) allow for depiction of delicate anatomic structures and reconstruction in all directions. A high percentage of our patients underwent surgery with spinal fusion. As orthopedic hardware causes metal-related artifacts in MRI, adjacent structures may be difficult to evaluate. Thus special pulse sequences that are insensitive, or at least less sensitive to susceptibility changes are important in these cases. In our experience, the use of *syngo* WARP* WIP-package reduced susceptibility artifacts in the presence of orthopedic hardware (Fig. 5). In this article we report on our experience in spine imaging using 3D sequences, and demonstrated reduction of metal-related susceptibility by using the *syngo* WARP* WIP-package.

3D-sequences

3D-sequences like *syngo* SPACE (Figs. 2 and 3) or CISS (Fig. 4) allow for 3-dimensional reconstruction with high resolution in every direction and curved reconstructions. We find the later especially helpful in cases of severe scoliosis to fully assess the spinal cord for cleft formations and tethering, because the myelon can be 'flattened out' as shown in the example of figure 3. The SPACE-sequence is based on, but faster than turbo spin echo and acquires more echoes after excitation. *syngo* SPACE helps reduce SAR (Specific Absorption Rate). Compared to turbo spin echo (TSE) the soft tissue contrast of SPACE is less sensitive, and SPACE is more vulnerable to susceptibility artifacts.
The *syngo* SPACE sequence is, however, less vulnerable to pulsation artifacts than a T2-weighted TSE (Fig. 2). Pulsation artifacts especially occur in the cervical subarachnoid space due to CSF motion. Even delicate anatomical structures like the ventral and dorsal nerve root can be delineated by the *syngo* SPACE- and CISS sequence (Figs. 2 and 4).

Reduction of susceptibility artifacts

In the presence of metallic implants, for instance after spinal fusion surgery, adjacent structures may not be assessable due to metal-related artifacts. The extent of the artifacts is determined by several factors, such as size and composition of the implant, orientation of the implant within the main magnetic field, the strength of the magnetic field, the type and parameters of the pulse sequence, and other imaging parameters like echo train length, slice thickness, and voxel size. The metallic composition of the implant has a major influence on the extent of the susceptibility artifact, with e.g. non-ferromagnetic titanium alloy producing significantly less artifacts than stainless steel. Of course, the size of the implant affects the extent of the artifacts, with small implants producing fewer artifacts than large ones. The position of the patient and thus of the implant within the main magnetic field (B_0) should be considered as the long axis of the implant and the direction of the main magnetic field should be parallel. The choice of an adequate pulse sequence is important. Instead of gradient echo (GRE) sequences, spin echo (SE) sequences should be used. The 180° refocusing pulse applied in SE sequences corrects for large magnetic field inhomogene-

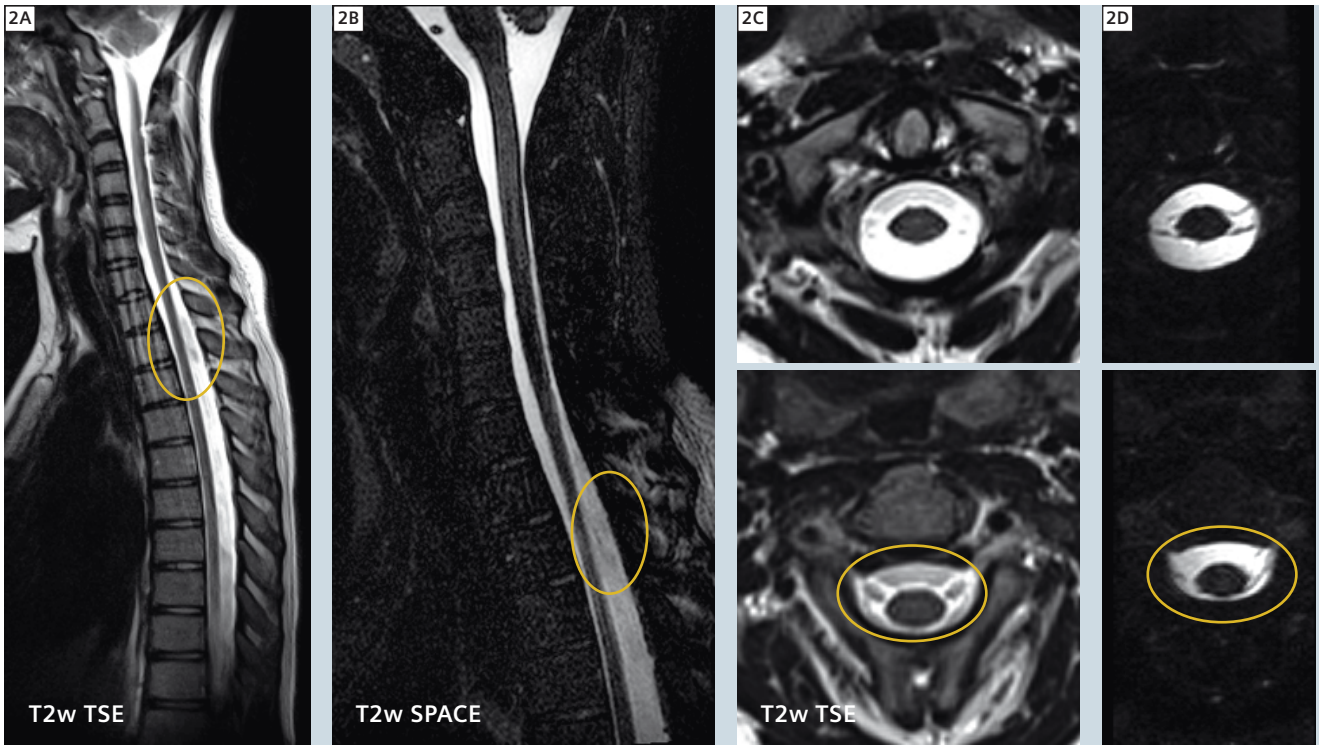

2 Pulsation artifacts: T2w TSE vs. T2w *syngo* SPACE.

*510(k) pending. Not for sale in the U.S.

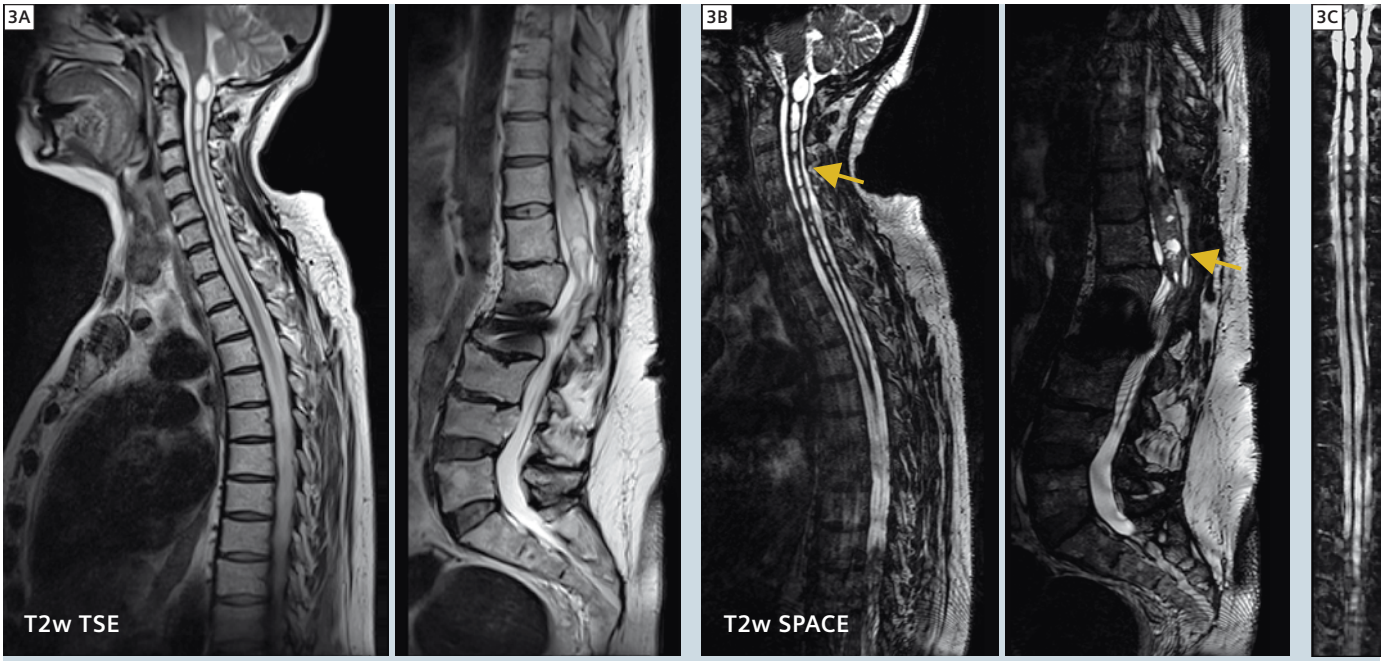

3 Posttraumatic syringomyelia: T2w TSE vs. T2w *syngo* SPACE.

ities. Higher magnetic field strengths produce larger susceptibility artifacts. But with consequently higher gradient pulses used in high-field MRI, the increased distortion effects of higher main magnetic fields can be reduced. Field-of-view (FOV), image matrix, and section thickness determine the voxel size. Small voxel sizes increase the spatial resolution. Thus using a small FOV, a high resolution matrix, thin sections, and high gradient strengths reduce susceptibility artifacts.

Case 1

For an MRI examination of patients with severe scoliosis, a flexible positioning is mandatory, facilitated by the great 70 cm bore of the MAGNETOM Verio scanner. In Figure 1, radiographic (1A), T2-weighted (1B, C) and T1-weighted images (1D) of a 51-year-old man with severe scoliosis are shown.

Case 2

17-year-old woman with unspecific non-radicular pain of the middle thoracic spine for 3 years. MRI did not reveal any pathologic finding. Compared to TSE sequences, *syngo* SPACE produces lesser pulsation artifacts in the subarachnoid space, and allows for a more defined delineation of delicate structures like the ventral and dorsal nerve roots. In Figure 2 the pulsation artifacts in the subarachnoid space using a T2-weighted TSE (2A) and a *syngo* SPACE sequence (2B) are compared. For delineation of nerve roots, a T2-weighted TSE sequence (2C) is opposed to a *syngo* SPACE sequence (2D).

Case 3

51-year-old woman, who had a traumatic fracture of the second lumbar vertebral body 25 years ago. Since the accident, she suffered from paraplegia, but in the meantime neurologic status further deteriorated resulting in tetraplegia.

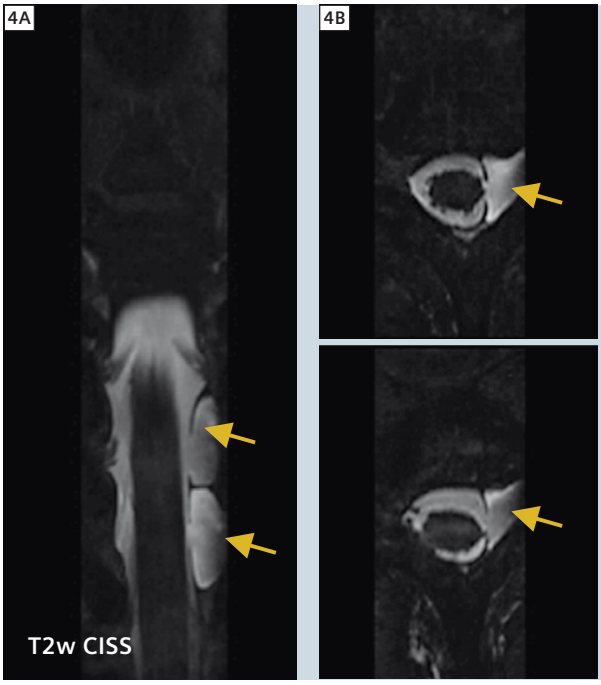

4 Avulsion of nerve roots and avulsion pseudo-meningoceles: Multiplanar reconstruction of T2w CISS.

Image 3 shows the posttraumatic syringomyelia ascending from the medullary conus to the medulla oblongata causative for the patient's increasing symptoms. Contrary to T2-weighted TSE (3A), the arachnopathic adhesions (arrows) are clearly visible using a *syngo* SPACE sequence (3B). Another advantage of 3D-sequence is the potential of multiplanar and curved reconstructions (3C).

Case 4

24-year-old man with a posttraumatic plegia of his left arm. The MRI performed 3 months after the accident demonstrates avulsion of the nerve roots C8 and T1 and consecutive avulsion pseudomeningoceles (arrows). In Figure 4, coronal (4A) and transversal (4B) reconstruction of the CISS sequence are shown.

Case 5

55-year-old female suffering from pseudoradicular pain of both legs. The patient underwent surgical implantation of a cage in the lumbosacral transition and spinal fusion from the fourth lumbar to the first sacral vertebral body. As MRI is compromised in the presence of metallic hardware due to metal-related artifacts, we observed a reduction of metal-related susceptibility artifacts when using the *syngo* WARP* WIP-package. The *syngo* WARP* WIP-package provides a set of modified sequences, which are designed to reduce imaging artifacts when scanning patients with metal implants. Main source of artifacts are susceptibility induced changes of the main magnetic field B_0 near metallic objects, leading to severe geometric distortions, contrast changes, signal pile-ups, as well as signal voids. In Figure 5, the potential of the *syngo* WARP sequences (5B) in reducing metal-related susceptibility artifacts is shown in comparison to a standard TSE sequence (5A).

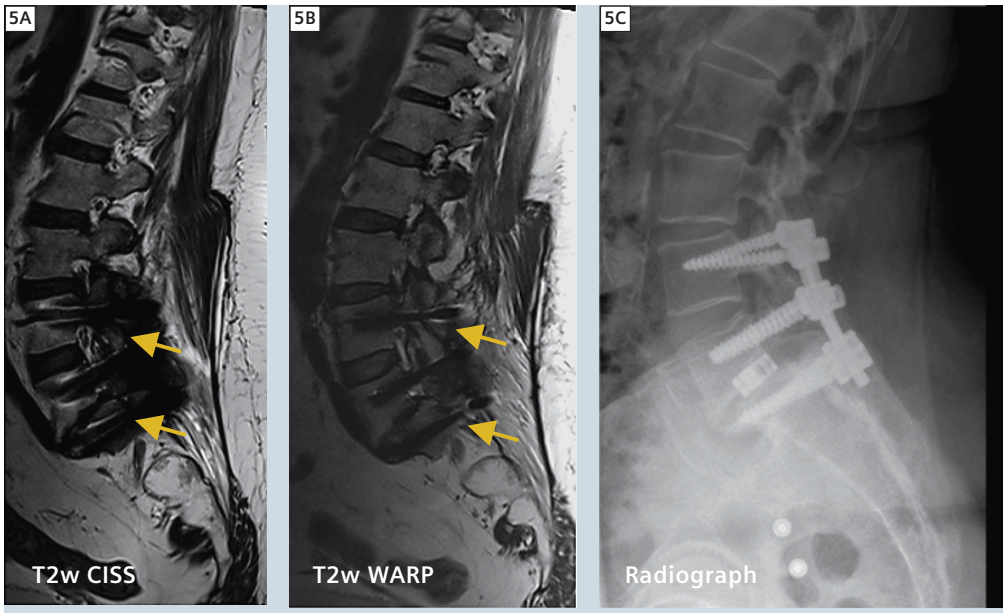

5 Metal implant imaging using *syngo* WARP*.

Acknowledgements

The excellent cooperation regarding brain and spine imaging with Prof. Dr. Stefan Hähnel from the Department of Neuroradiology at the University Hospital Heidelberg (Head: Prof. Dr. Martin Bendszus) is gratefully acknowledged.

Disclaimer:
MR imaging of patients with metallic implants brings specific risks. However, certain implants are approved by the governing regulatory bodies to be MR conditionally safe. For such implants, the previously mentioned warning may not be applicable. Please contact the implant manufacturer for the specific conditional information. The conditions for MR safety are the responsibility of the implant manufacturer, not of Siemens.

*510(k) pending. Not for sale in the U.S. and in other countries.

References
1 Gasparotti R, Ferraresi S, Pinelli L, Crispino M, Pavia M, Bonetti M, Garozzo D, Manara O, Chiesa A. Three-dimensional MR myelography of traumatic injuries of the brachial plexus. AJNR Am J Neuroradiol. 1997, 18(9):1733-42.
2 Lee MJ, Kim S, Lee SA, Song HT, Huh YM, Kim DH, Han SH, Suh JS: Overcoming artifacts from metallic orthopedic implants at high-field-strength MR imaging and multi-detector CT. Radiographics 2007, 27:791-803.
3 Lichy MP, Wietek BM, Mugler JP 3rd, Horger W, Menzel MI, Anastasiadis A, Siegmann K, Niemeyer T, Königsrainer A, Kiefer B, Schick F, Claussen CD, Schlemmer HP. Magnetic resonance imaging of the body trunk using a single-slab, 3-dimensional, T2-weighted turbo-spin-echo sequence with high sampling efficiency (SPACE) for high spatial resolution imaging: initial clinical experiences. Invest Radiol. 2005, 40(12):754-60.

Marc-André Weber, M.D., M.Sc.

Marcel Wolf, M.D.

Contact
Marc-André Weber, M.D., M.Sc.
Professor of Radiology
Heidelberg University
Diagnostic and Interventional Radiology
Im Neuenheimer Feld 110
69120 Heidelberg
Germany
MarcAndre.Weber@med.uni-heidelberg.de

Marcel Wolf, M.D.
Radiology Resident
Heidelberg University
Department of Neuroradiology
Im Neuenheimer Feld 400
69120 Heidelberg
Germany
Marcel.Wolf@med.uni-heidelberg.de