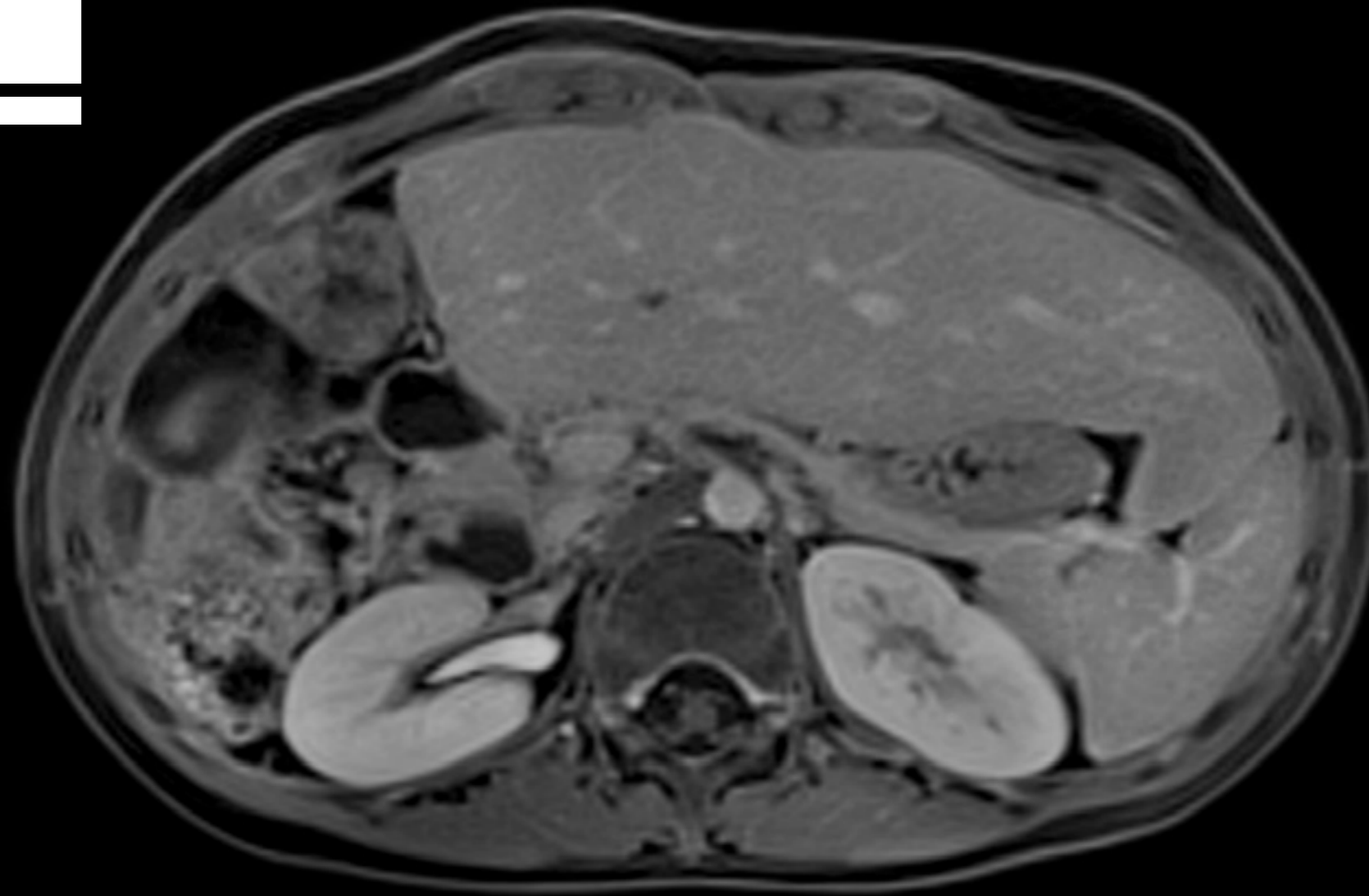

Body MRI Case
with FREEZEit¹

Hepatoblastoma – Post right Hepatectomy

Follow-up exam with StarVIBE¹

www.siemens.com/body-mri-cases

Background

Patient data



Male

3

Years

Patient history

Diagnosis of hepatoblastoma. Condition after resection of the majority of the right lobe of the liver.

Hepatoblastoma –
Post right Hepatectomy
Follow-up exam with StarVIBE

→ **Background**

→ Prehistory

→ Examination

→ Clinical Images

→ Consequences

Prehistory

Differential diagnosis

There are **other malignant** liver tumors, including hepatocellular carcinoma, and **benign** tumors, such as mesenchymal hamartoma. Diagnosis is made by biopsy.

Hepatoblastoma –
Post right Hepatectomy
Follow-up exam with StarVIBE

→ Background

→ **Prehistory**

→ Examination

→ Clinical Images

→ Consequences

Examination

MR imaging findings

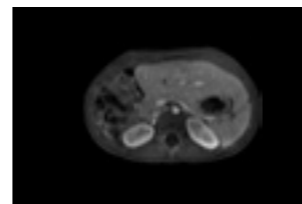
Findings:

The majority of the right lobe of the liver has previously been resected and there is compensatory hypertrophy of the remaining left and caudate lobes, not significantly changed from prior. The remaining portal and hepatic veins are patent. No evidence of recurrent or residual tumor or other new focal hepatic lesions. No intrahepatic biliary ductal dilatation. The gallbladder is absent.

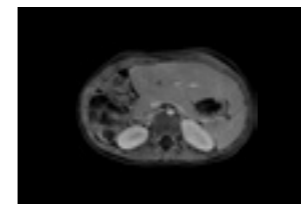
No additional adenopathy. No osseous abnormality.

Summary:

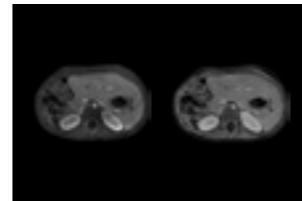
Stable post partial liver resection with no evidence of recurrent tumor or metastatic disease. Slight increase in mesenteric lymph nodes, non-specific.



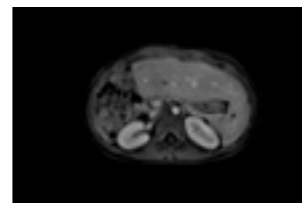
→ 3D VIBE



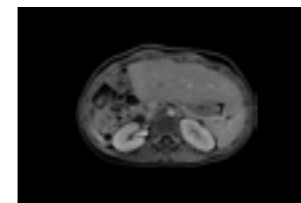
→ StarVIBE



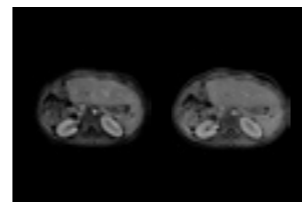
→ Comparison



→ 3D VIBE



→ StarVIBE



→ Comparison

Hepatoblastoma –
Post right Hepatectomy
Follow-up exam with StarVIBE

→ Background

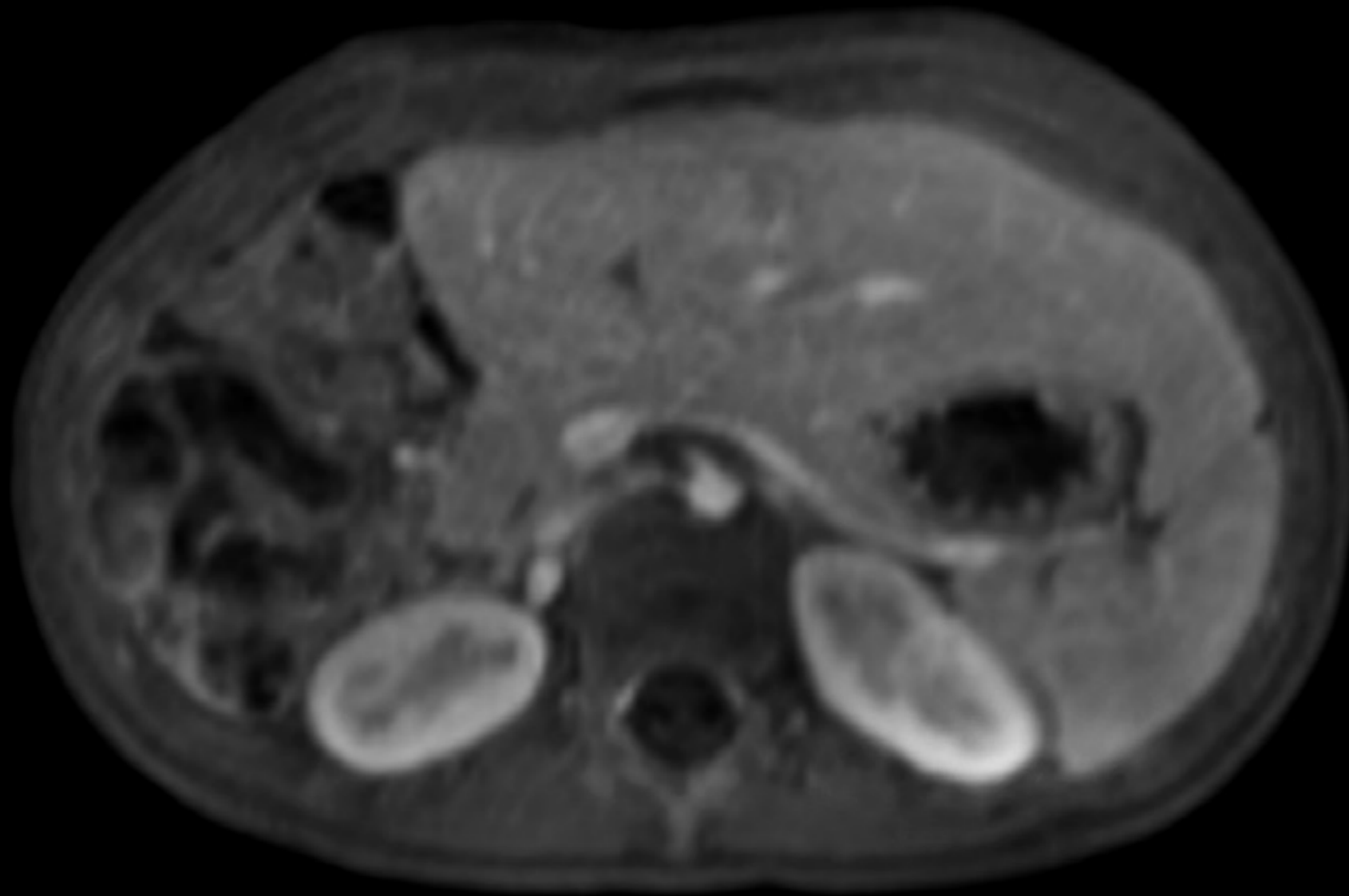
→ Prehistory

→ Examination

→ Clinical Images

→ Consequences

3D VIBE



Hepatoblastoma –
Post right Hepatectomy
Follow-up exam with StarVIBE

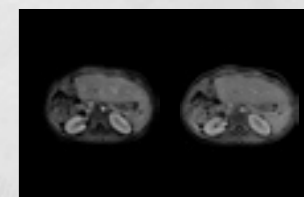
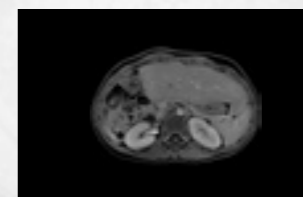
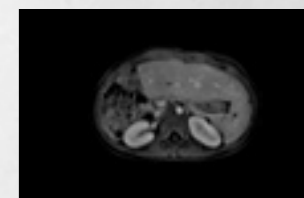
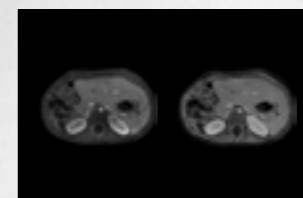
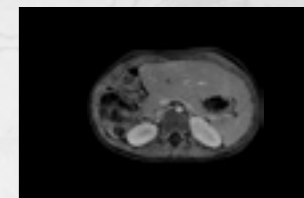
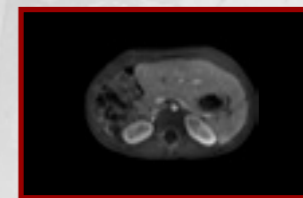
→ Background

→ Prehistory

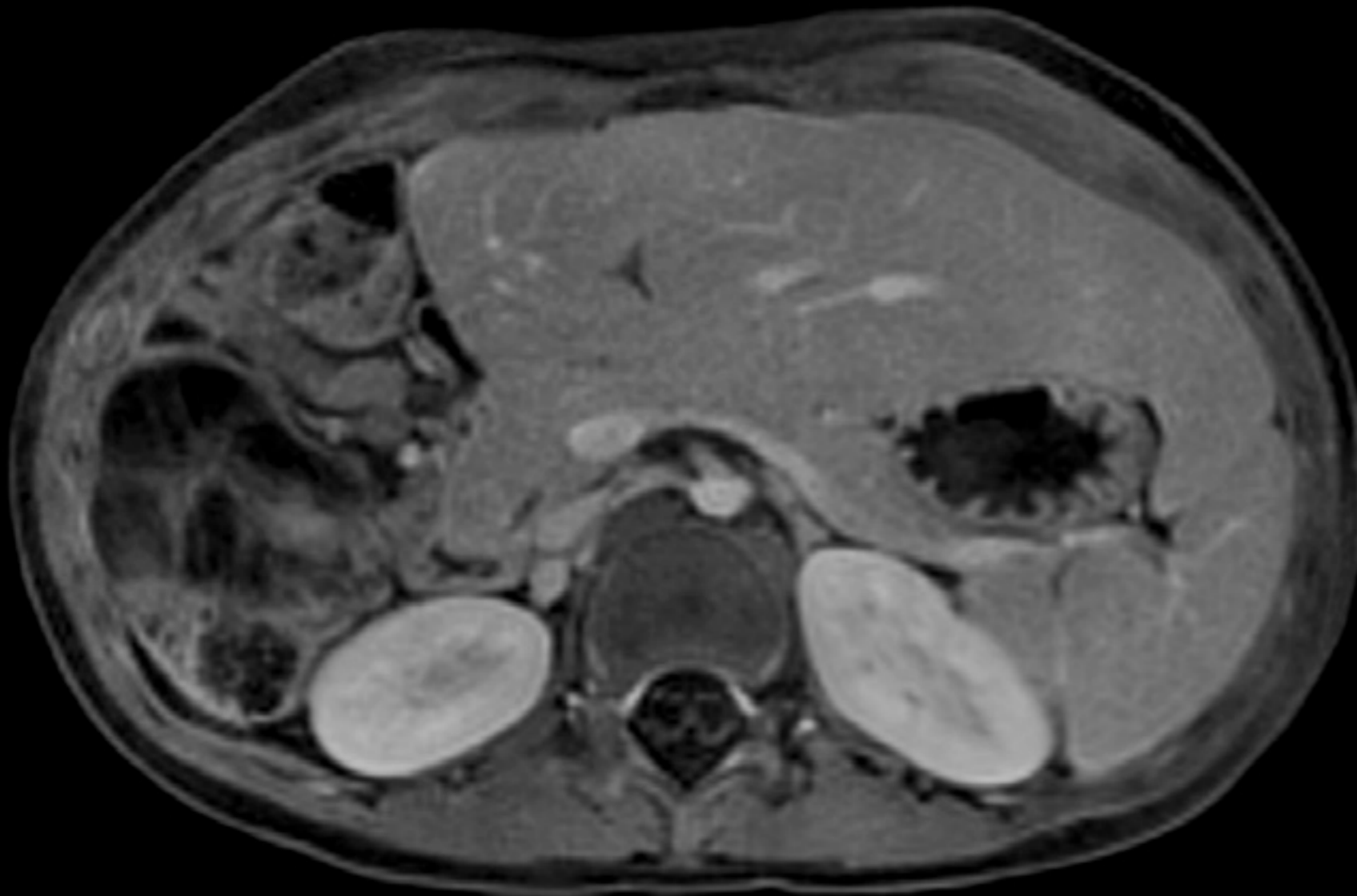
→ Examination

→ **Clinical Images**

→ Consequences



StarVIBE



Hepatoblastoma –
Post right Hepatectomy
Follow-up exam with StarVIBE

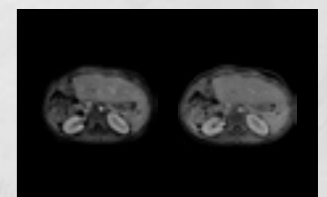
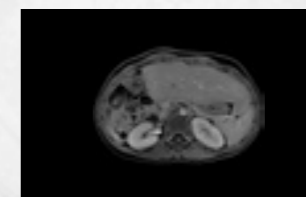
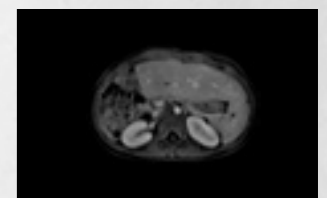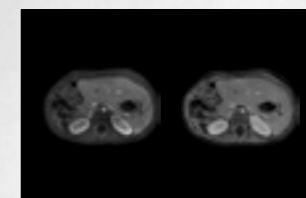
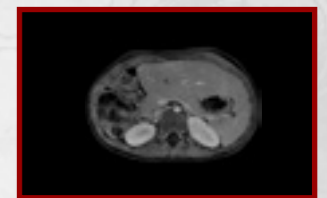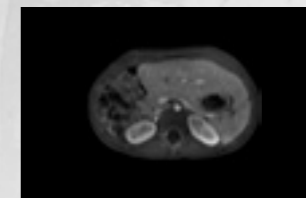
→ Background

→ Prehistory

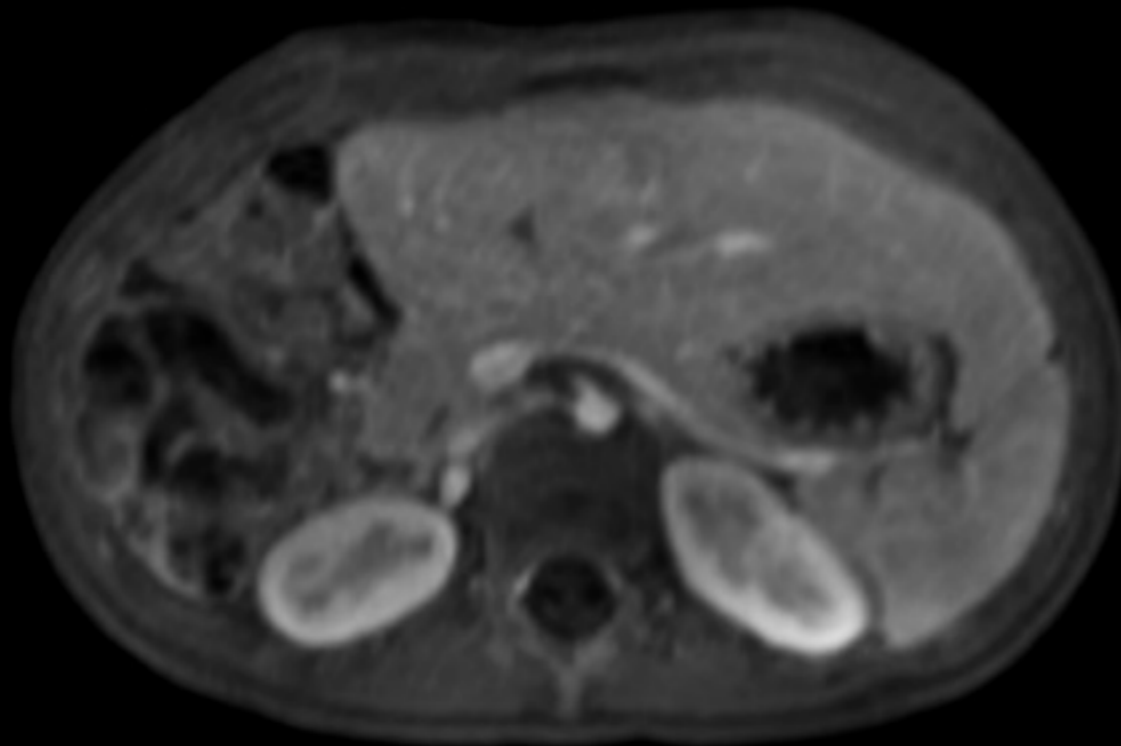
→ Examination

→ **Clinical Images**

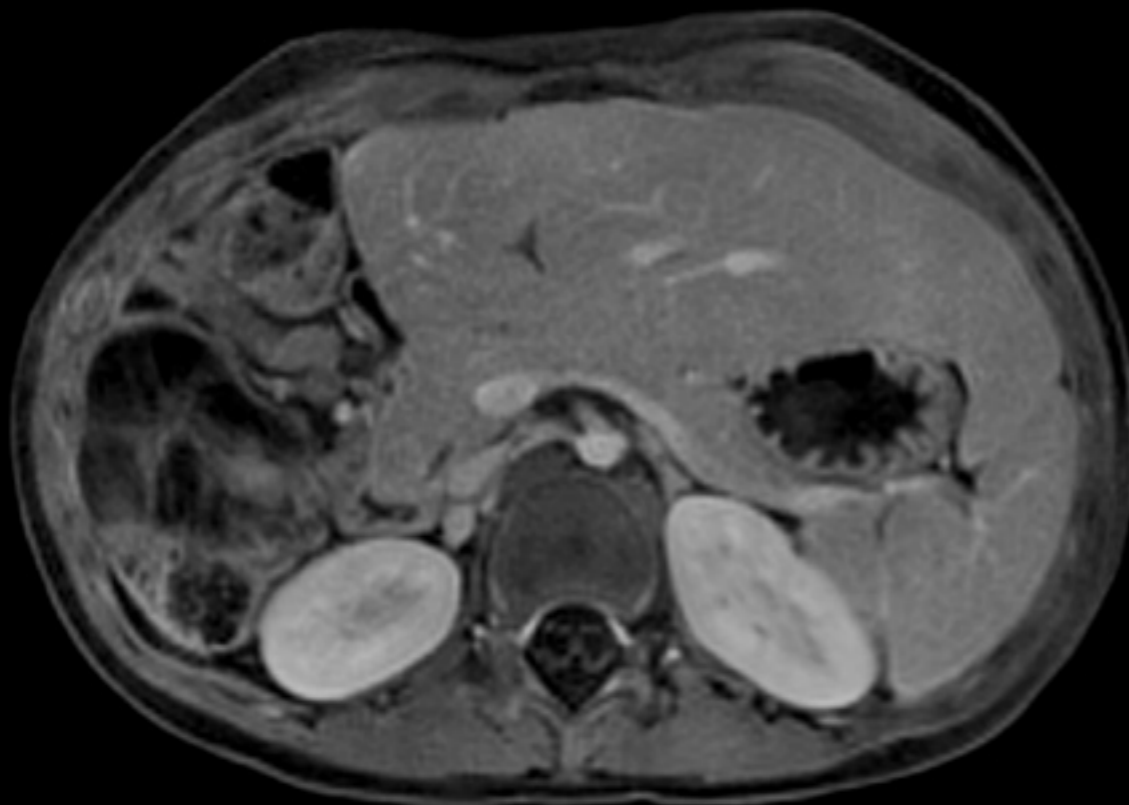
→ Consequences



3D VIBE



StarVIBE



Hepatoblastoma –
Post right Hepatectomy
Follow-up exam with StarVIBE

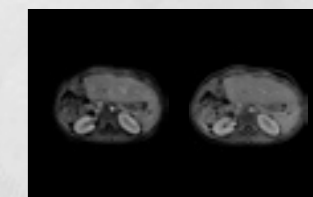
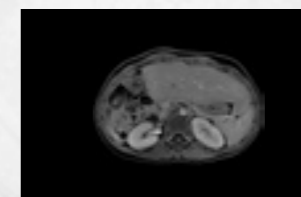
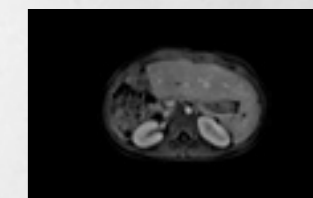
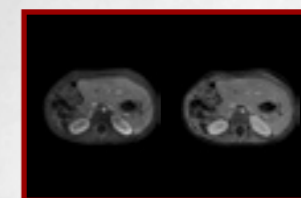
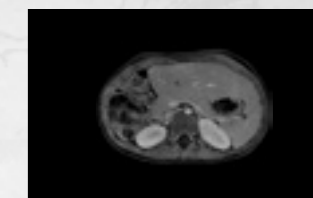
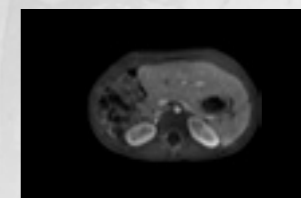
→ Background

→ Prehistory

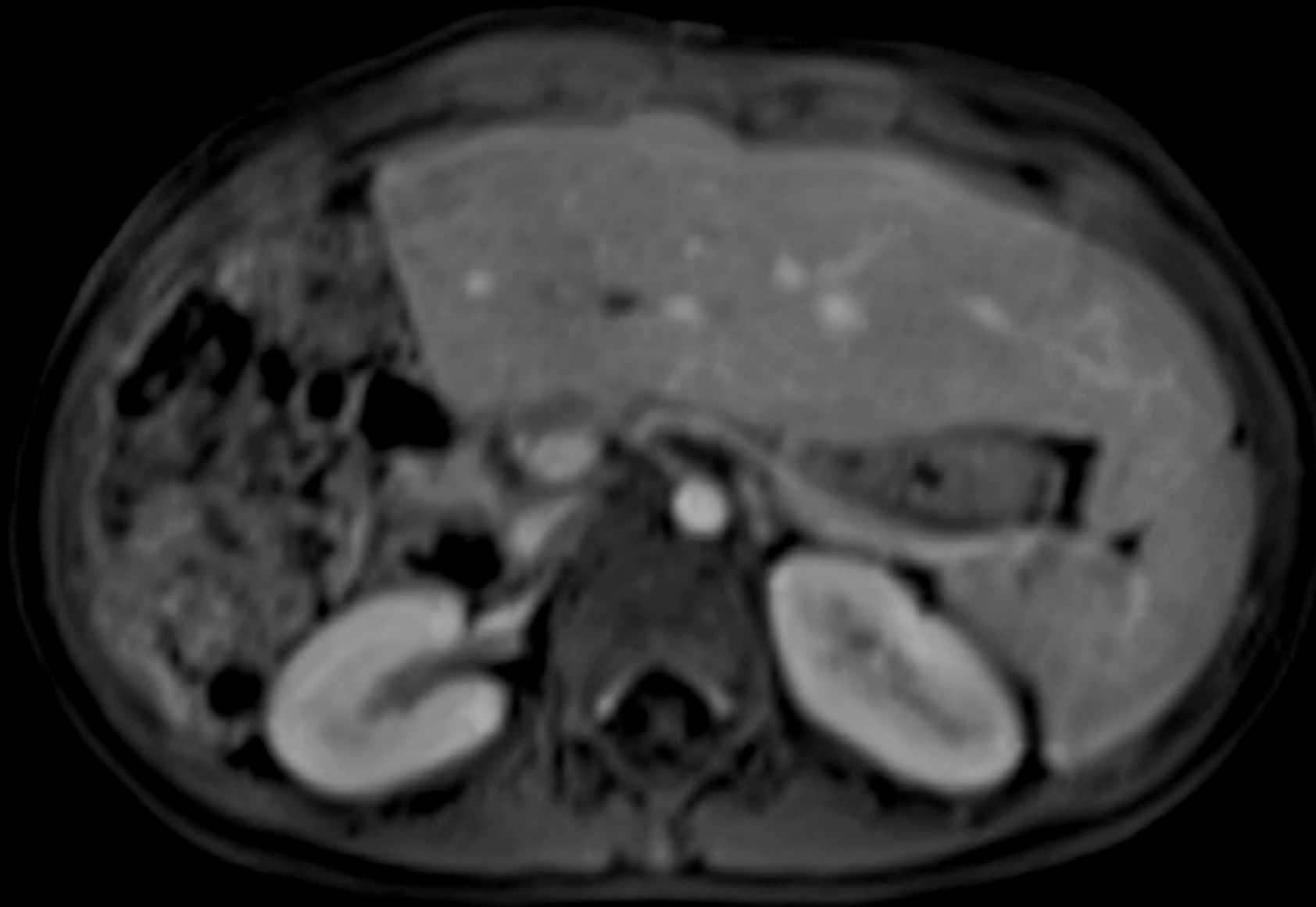
→ Examination

→ **Clinical Images**

→ Consequences



3D VIBE



Hepatoblastoma –
Post right Hepatectomy
Follow-up exam with StarVIBE

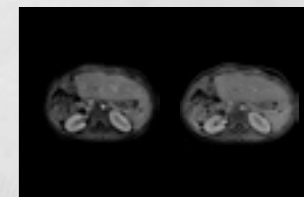
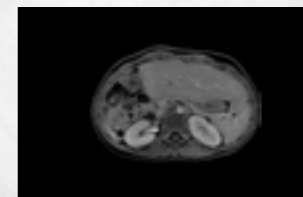
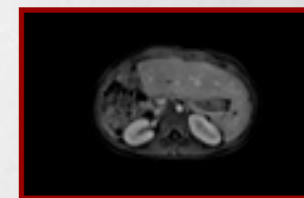
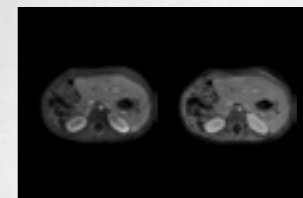
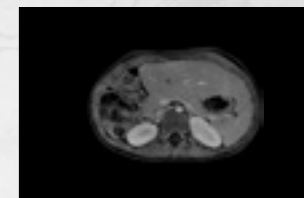
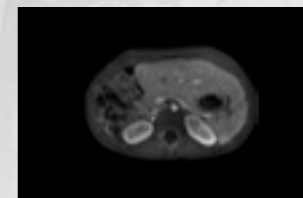
→ Background

→ Prehistory

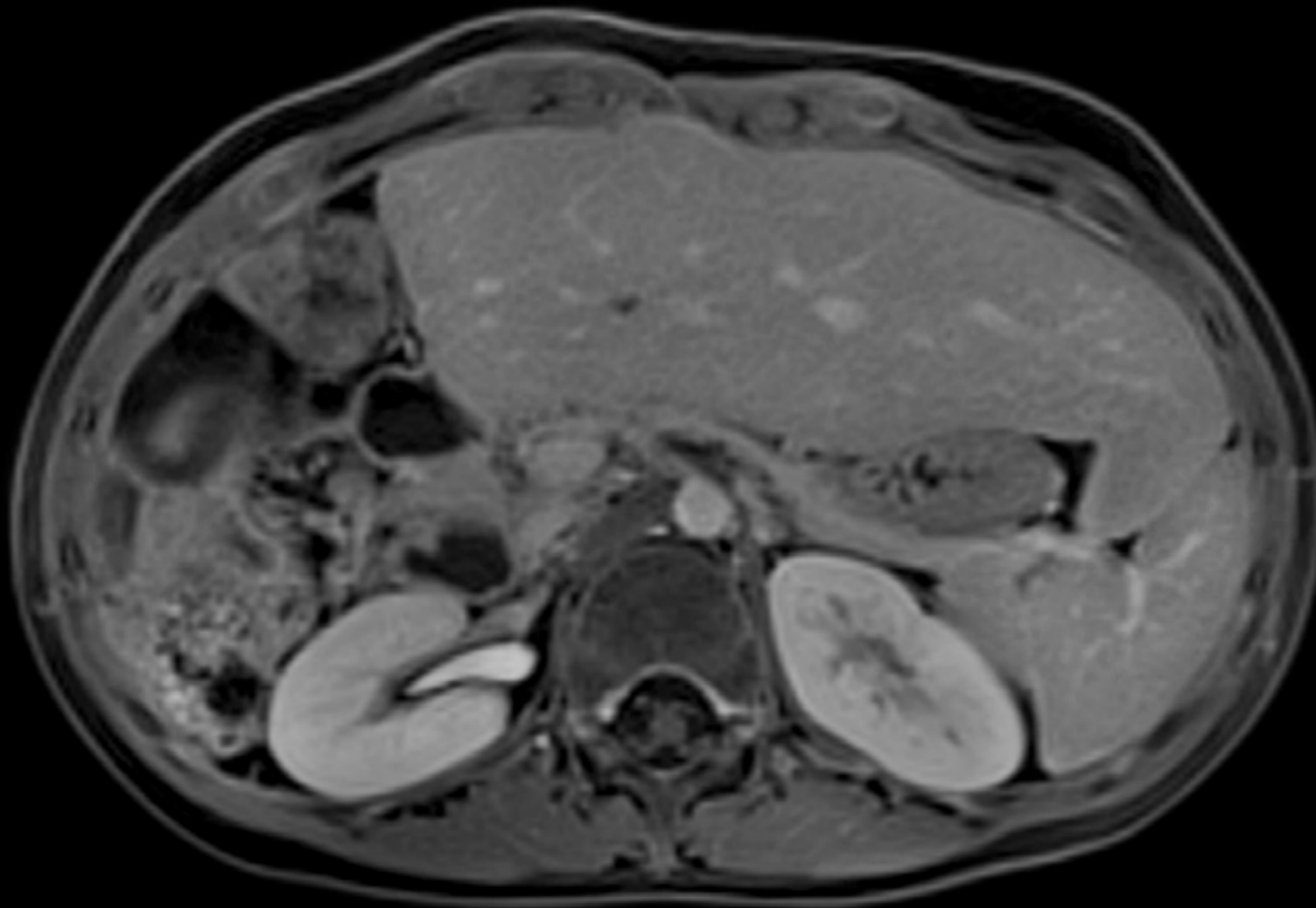
→ Examination

→ **Clinical Images**

→ Consequences



StarVIBE



Hepatoblastoma –
Post right Hepatectomy
Follow-up exam with StarVIBE

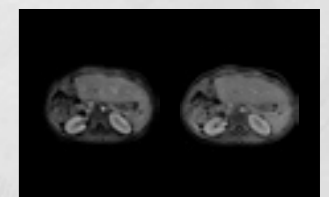
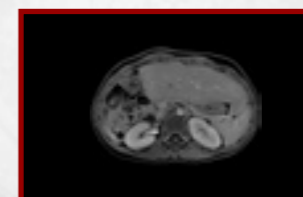
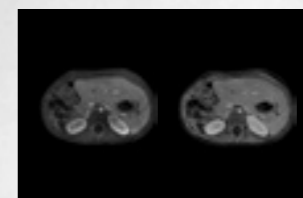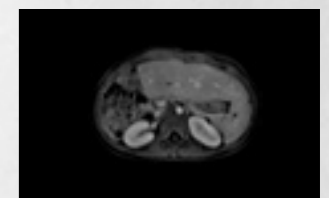
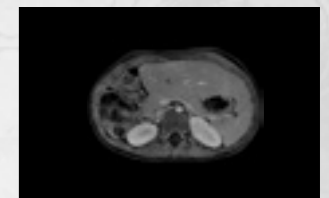
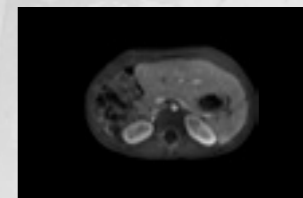
→ Background

→ Prehistory

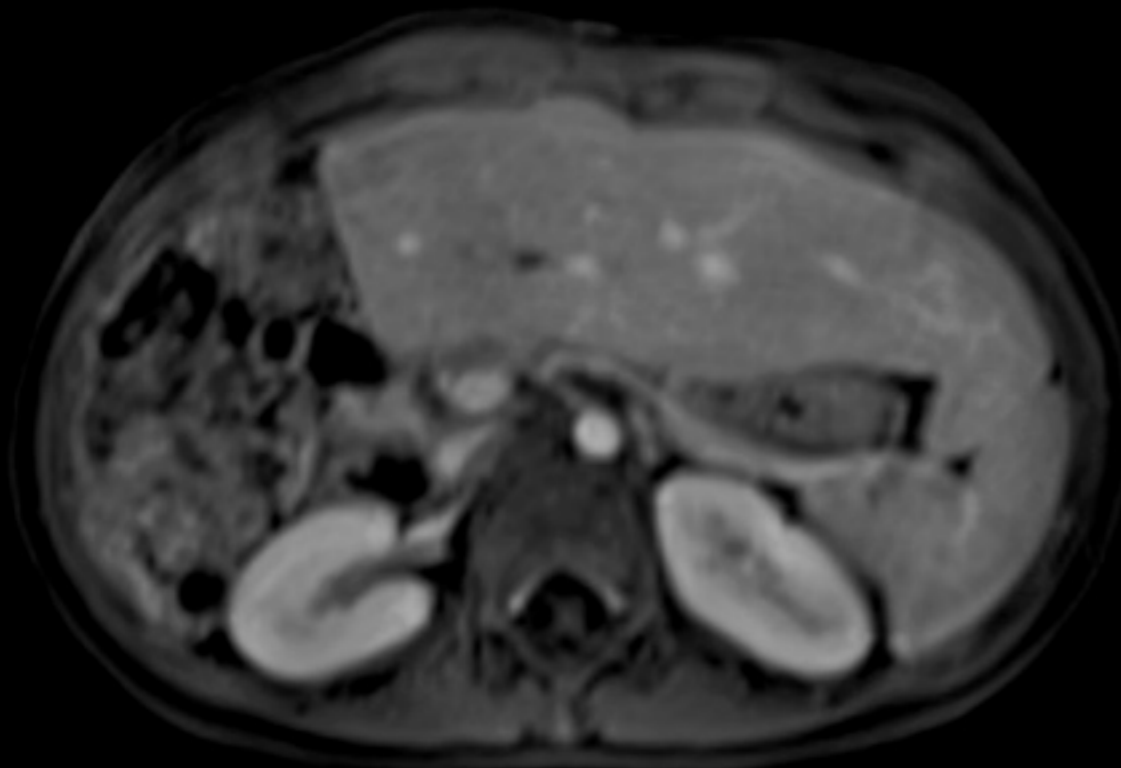
→ Examination

→ **Clinical Images**

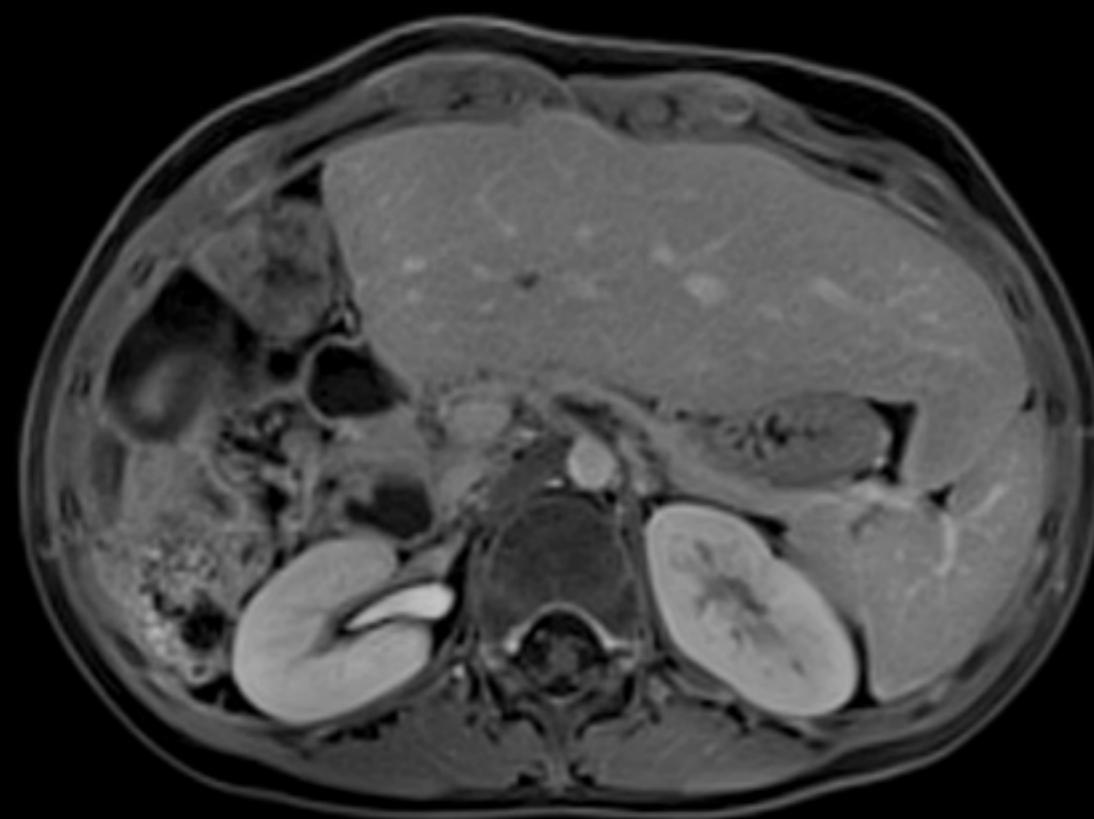
→ Consequences



3D VIBE



StarVIBE



Hepatoblastoma –
Post right Hepatectomy
Follow-up exam with StarVIBE

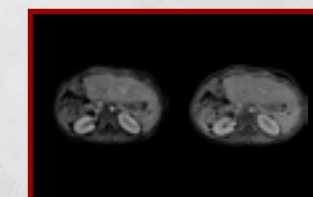
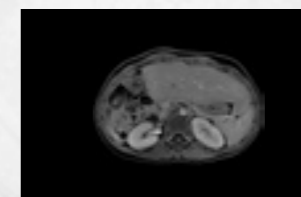
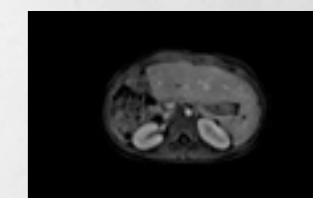
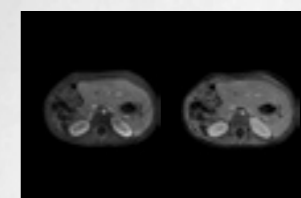
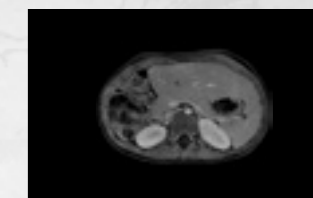
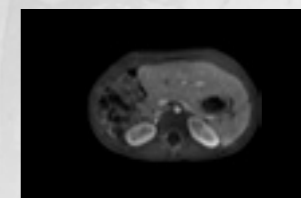
→ Background

→ Prehistory

→ Examination

→ **Clinical Images**

→ Consequences



Consequences

Consequences and procedure

Using a torso phased array coil, coronal HASTE axial T1, axial T2 fat, and axial diffusion weighted images were performed through the abdomen and pelvis.

2D time-of-flight images were obtained through the portal vein. Limited axial T2* weighted images were performed through the upper liver.

Multiple 3D GRE T1 fat-sat images were generated following the administration of intravenous gadolinium chelate.

StarVIBE was performed following the breath-hold Cartesian acquisition in the portal venous phase.

Therapeutic and prognostic relevance

Higher spatial resolution and improved motion robustness improves confidence in excluding local recurrence.

Hepatoblastoma –
Post right Hepatectomy
Follow-up exam with StarVIBE

→ Background

→ Prehistory

→ Examination

→ Clinical Images

→ **Consequences**

On account of certain regional limitations of sales rights and service availability, we cannot guarantee that all products included in this brochure are available through the Siemens sales organization worldwide. Availability and packaging may vary by country and is subject to change without prior notice. Some/All of the features and products described herein may not be available in the United States.

The information in this document contains general technical descriptions of specifications and options as well as standard and optional features which do not always have to be present in individual cases, and which may not be commercially available in all countries. Due to regulatory reasons their future availability cannot be guaranteed. Please contact your local Siemens organization for further details.

Siemens reserves the right to modify the design, packaging, specifications, and options described herein without prior notice. Please contact your local Siemens sales representative for the most current information.

Note: Any technical data contained in this document may vary within defined tolerances. Original images always lose a certain amount of detail when reproduced.

Local Contact Information

Asia/Pacific:

Siemens Medical Solutions
Asia Pacific Headquarters
The Siemens Center
60 MacPherson Road
Singapore 348615
Phone: +65 6490 6000

Canada:

Siemens Canada Limited
Healthcare Sector
1550 Appleby Lane
Burlington, ON L7L 6X7, Canada
Phone +1 905 315-6868

Europe/Africa/Middle East:

Siemens AG, Healthcare Sector
Henkestr. 127
91052 Erlangen, Germany
Phone: +49 9131 84-0

Latin America:

Siemens S.A., Medical Solutions
Avenida de Pte. Julio A. Roca No 516, Piso
C1067 ABN Buenos Aires, Argentina
Phone: +54 11 4340-8400

USA:

Siemens Medical Solutions USA, Inc.
51 Valley Stream Parkway
Malvern, PA 19355-1406, USA
Phone: +1 888 826-9702

¹ FREEZEit and StarVIBE are not commercially available in all countries. Due to regulatory reasons their future availability cannot be guaranteed. Please contact your local Siemens organization for further details.

© 2014 Siemens AG

www.siemens.com/body-mri-cases

Global Business Unit

Siemens AG
Medical Solutions
Magnetic Resonance
Henkestraße 127
DE-91052 Erlangen
Germany
Phone: +49 9131 84-0
www.siemens.com/healthcare

Global Siemens Headquarters

Siemens AG
Wittelsbacherplatz 2
80333 Muenchen
Germany

Global Siemens Healthcare Headquarters

Siemens AG
Healthcare Sector
Henkestraße 127
91052 Erlangen
Germany
Phone: +49 9131 84-0
www.siemens.com/healthcare