

# MR-guided Gynecological High Dose Rate (HDR) Brachytherapy

Joann I. Prisciandaro<sup>1</sup>; James M. Balter<sup>1</sup>; Yue Cao<sup>1</sup>; Katherine Maturen<sup>2</sup>; Amir Owrangi<sup>1</sup>; Shruti Jolly<sup>1</sup>

<sup>1</sup>Department of Radiation Oncology, University of Michigan, Ann Arbor, MI, USA

<sup>2</sup>Department of Radiology, University of Michigan, Ann Arbor, MI, USA

## Introduction

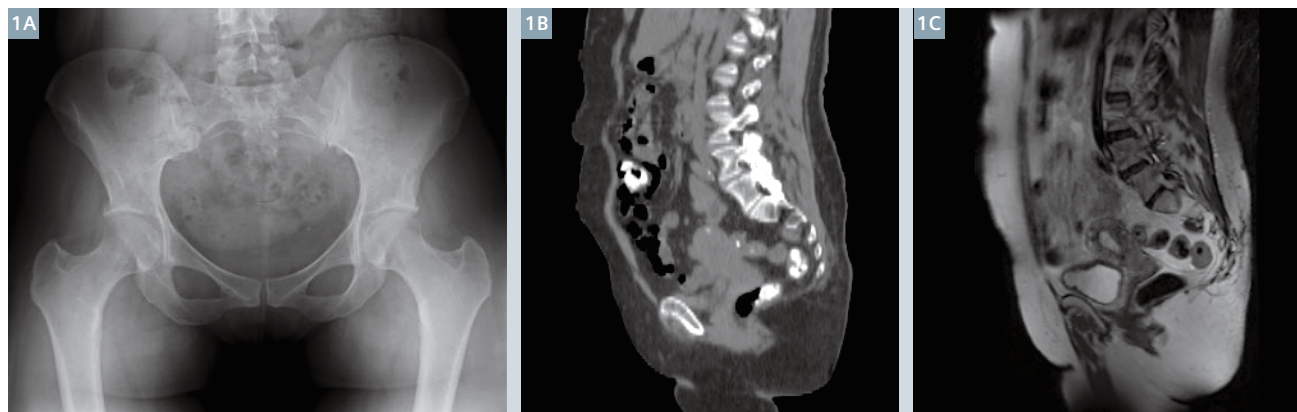Brachytherapy is a form of radiation therapy that is delivered using sealed radioactive sources positioned in close proximity to tissues with cancer. The term derives from the Greek meaning short distance therapy. It is one of the original forms of radiation therapy, and emerged shortly after the discovery of radium in the early 1900's. Up until the 1990's, little had changed in the way brachytherapy treatments were planned and delivered. The nominal workflow consisted of the selection and *in vitro* placement of the appropriate applicator (a device that contains the radioactive source(s)), acquisition of 2D radiographic images to determine the position of the applicator and sources relative to the patient's anatomy, determination of the desired dose to the cancerous tissues and dose limits to neighboring normal tissues, and development of a treatment strategy to deliver the dose. The last two steps are iterative, as one tries to optimize the position and length of time the radioactive source(s) may reside in

the applicator to deliver the highest possible dose to the defined region of interest, while minimizing dose to neighboring normal tissues. However, 2D imaging presents limitations to the development of an optimal treatment plan. Although radiographs provide sharp subject contrast and detail between objects with highly varying attenuation, such as bone and air, the limited differences in attenuation between different types of soft tissue make them difficult to discern (Fig. 1A). As a result, brachytherapy treatment plans have traditionally been designed to deliver the desired dose to a geometrically defined reference point relative to the applicator to which anatomic significance is attached. This approach limits the ability to individualize the patient's radiation to their specific tumor and normal tissues.

In the 1990's, as computed tomography (CT) and magnetic resonance imaging (MRI) became more widely available at clinics and hospitals,

brachytherapy imaging began to transition from the use of planar to volumetric imaging. Unlike radiographs, volumetric images support some visualization of tumors and adjacent normal soft tissues (Figs. 1B, C). Compared to CT, MR images have the advantage of superior soft tissue resolution, and clear distinction of pelvic structures such as the uterus and cervix. Since local tumor control is strongly dependent on appropriately defined tumor volumes and the accurate delivery of radiation, the ability to visualize and delineate soft tissue is expected to improve target coverage and normal tissue sparing [1].

Beginning in 2000, GEC-ESTRO (the Groupe Européen de Curiethérapie – European Society for Radiotherapy & Oncology) recognized the significance of volumetric imaging in the movement toward 3D treatment planning for gynecological diseases, namely cervical cancer, with the formation of the gynecological (GYN) GEC-ESTRO work group [1]. In the fourteen years



1 Example (1A) anterior pelvic radiograph [10], (1B) sagittal view of a pelvic CT simulation, and (1C) a sagittal reconstruction of a T2w 3D (SPACE) coronal image.

since its creation, the work group has released a series of recommendations to help standardize the approach to image-based brachytherapy treatment planning [1-4]. This has included the definition of a common language and means of delineating the target volumes (i.e., Low Risk-Clinical Target Volume (CTV), Intermediate Risk-CTV and High Risk-CTV for definitive treatment of cervix cancer), discussion on issues related to applicator reconstruction, and suggestions on the appropriate MR imaging sequences to utilize for treatment planning. Although these recommendations are helpful, there is a significant learning curve for each clinic during the clinical commissioning of MR-guided brachytherapy that is dependent on their specific MRI unit and brachytherapy applicators.

### MR-simulator

In 2012, a 3T wide-bore MRI-simulator was installed in the department of Radiation Oncology at the University of Michigan (MAGNETOM Skyra, Siemens Healthcare, Erlangen, Germany). This unit was purchased for the express purpose of complementing, and at times, replacing CT treatment simulations, and has been outfitted with a laser marking system (LAP, Lueneburg, Germany) and detachable couch [5]. The couch supports imaging and treatment of brachytherapy patients, eliminating the need to transfer patients to other tables and the risk of inadvertently modifying the local geometry of the applicator and surrounding tissues. The brachytherapy suite is directly across the hall from the MRI-simulator, and an access door and path was built into the room design to permit wheeling the couch directly to the treatment suite following scanning.

### Clinical commissioning

Prior to the clinical implementation of MR-guided brachytherapy, it is imperative to commission the process and workflow. Commissioning varies based on the desired treatment site, and involves the determination of the optimal imaging sequences for anatomical and applicator visualization. Care must be taken to ensure an MR conditional or compatible applicator is selected prior to the simulation. For treatment



2

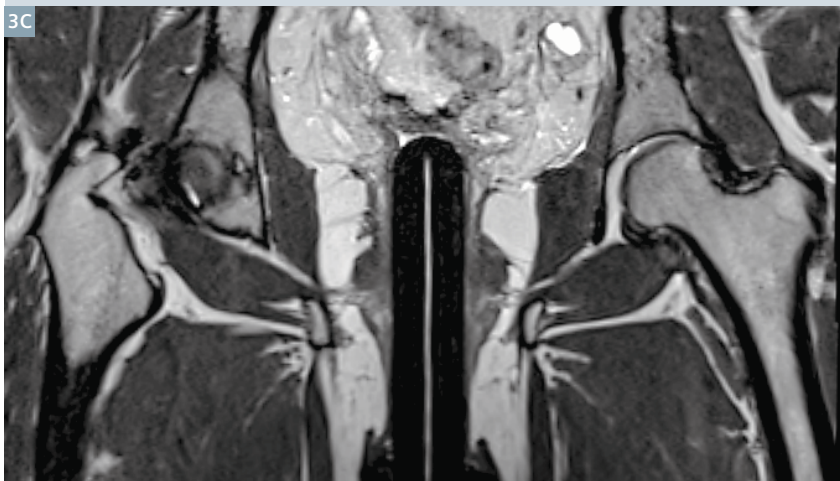
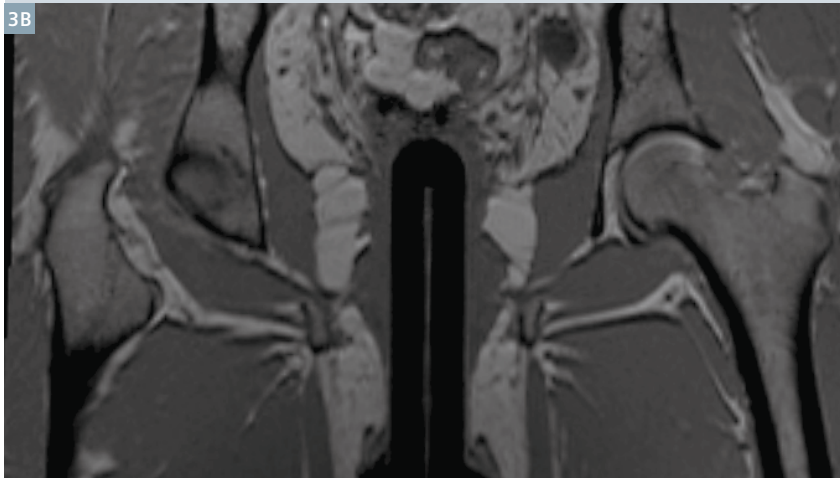
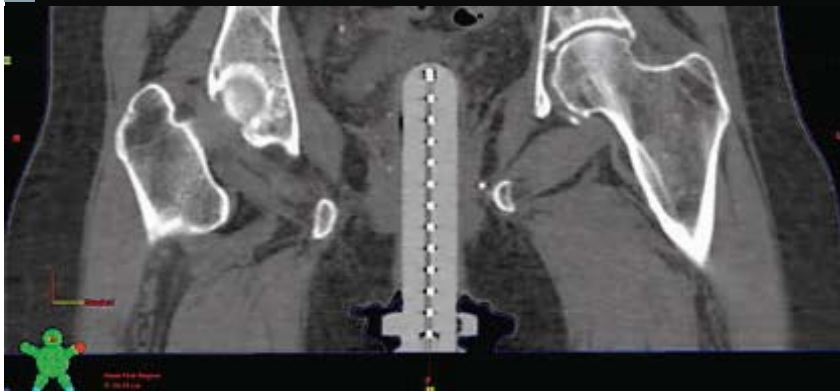Common brachytherapy applicators used for vaginal brachytherapy delivery, (2A) vaginal cylinder (Varian Medical Systems, Palo Alto, CA, USA) and (2B) ovoids (modified from the Fletcher Williamson Applicator Set, Nucletron/Elekta, Veenendaal, The Netherlands).

planning purposes, the images are imported into a software package (treatment planning system) that allows the user to identify the position of the applicator/potential source positions (a process known as applicator reconstruction) and the relevant patient anatomy. This software can then be used to optimize the length of time the radioactive source(s) should reside in various positions along the length of the applicator in order to deliver the desired dose and dose distribution to the patient. While the applicator, in particular the source channel (i.e., the hollow channel within the applicator where the source(s) may reside), is well-visualized in planar and CT imaging with the use of x-ray markers, this task is challenging with MRI. At present there are few MR markers that are commercially available to assist with applicator reconstruction. Additionally, the presence of the applicator, especially titanium applicators, produces image artifacts and distortions. Since dose calculations are dependent on the accurate definition of the applicator, namely the source position(s), relative to the patient's anatomy, geometrical uncertainties may result in dosimetric uncertainties to the target volume(s) and neighboring normal structures

[3]. Thus, it is critical to evaluate these uncertainties prior to the clinical implementation of MR-guided brachytherapy.

#### a. Vaginal high dose rate (HDR) brachytherapy

Clinically, vaginal brachytherapy is most often used in the adjuvant treatment of uterine cancer post hysterectomy to reduce the risk of cancer recurrence in the vagina. Vaginal brachytherapy can also be used for treatment of other gynecologic cancers, including cervix, primary vaginal and vulvar cancer as clinically indicated. The typical applicators used for the delivery of vaginal brachytherapy are the vaginal cylinder and ovoids [6] (see Fig. 2). A vaginal cylinder is typically a smooth, plastic cylinder with a dome shaped apex that is available in diameters ranging from approximately 2.0–4.0 cm, depending on the patient's anatomy. The applicator typically has a single, hollow channel that runs along the center of the device; however, multi-channel variants are also available. Ovoids are hollow egg or cylinder-shaped capsules that are inserted into a patient's vagina and pressed up against the cervix if present or apex of the vaginal vault. Whereas the ovoids may be used to treat the upper



**3** Coronal view of a patient with a vaginal cylinder on (3A) CT, (3B) 3D T1w (MPRAGE) MR, and (3C) 3D T2w (SPACE) MR. To assist with the visualization of the central source channel, the appropriate marker (x-ray for CT and contrast filled for MR) was inserted in the applicator prior to simulations.

portion of the vagina (known as the vaginal cuff), the vaginal cylinder offers the flexibility of treating the entire length of the vaginal vault [6].

During the clinical commissioning of MR-guided vaginal brachytherapy at the University of Michigan between August and September of 2013, three patients received a CT simulation preceding each HDR treatment

with a Philips Brilliance CT scanner (Philips Medical, Chesterfield, MO, USA), followed by an MRI simulation using a Siemens MAGNETOM Skyra 3T scanner. The patients were positioned supine with their legs straight. The CT scan was acquired with a 1 mm slice thickness with an x-ray marker in place (see Figure 3A). The MRI was acquired with T1 and T2-weighted 3D imaging sequences.

The following MRI sequences were used: 3D T2 (SPACE) coronal (FOV 320 × 320 × 176 mm, voxel size 0.94 × 0.94 × 1 mm, TR 1700 ms, TE 88 ms) and 3D T1 (MPRAGE) coronal (FOV 300 × 300 × 166.4 mm, voxel size 1.17 × 1.17 × 1.3 mm, TR 1900 ms, TE 2.35 ms, TI 900 ms, flip angle 9°). In order to identify the applicator channel, an MR marker was made in-house using a thin (0.046" outer diameter), hollow nylon tube (Best Medical International, Springfield, VA, USA) filled with gadolinium-doped water (T1 contrast) or either water or 0.2% Agarose Gel (T2 contrast), then sealed. Several different techniques were tested to seal the catheter ends including a heat seal with and without hot glue, bone wax with cyanoacrylate, and Water Weld™ with and without cyanoacrylate.

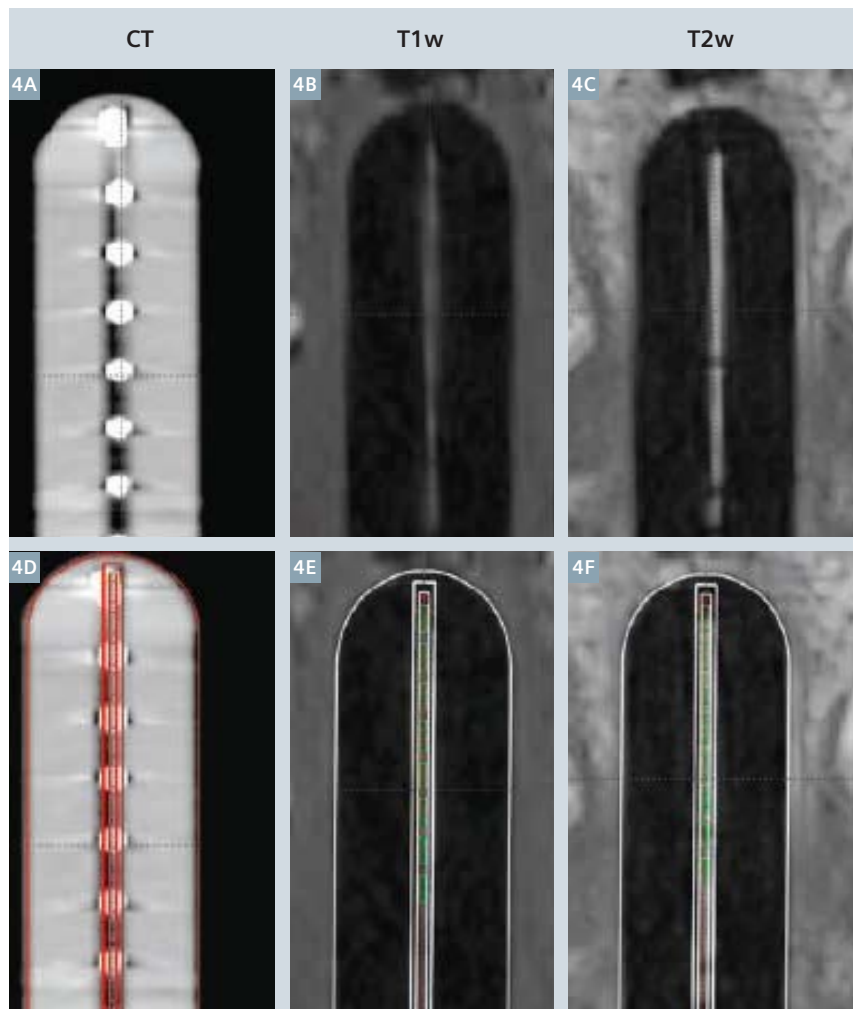
Although the applicator channel was easily visualized with the presence of the appropriate MR marker in both the T1w and T2w images as illustrated in Figures 3B and 3C, the applicator tip proved difficult to identify due to challenges in achieving a watertight seal. This resulted in observed displacements of the catheter tip, at times exceeding 1 cm. As such, an alternative method was investigated for applicator reconstruction using a solid model of the applicator available in the treatment planning software (BrachyVision 8.11, Varian Medical Systems, Palo Alto, CA, USA). Using T1w and/or T2w images, the solid model was aligned to the perimeter of the applicator (see Fig. 4). Deviations between the central source positions identified via aligning the applicator surface model to MR versus using the x-ray marker on CT to reconstruct the applicator (the conventional method) ranged from 0.07–0.19 cm and 0.07–0.20 cm for T1w and T2w images, respectively. Based on this study, vaginal brachytherapy patients at the University of Michigan now routinely undergo a single, T2w SPACE scan with approximately 1 mm isotropic voxel size. The applicator and related source positions for treatment planning are determined by alignment of the applicator model to the vaginal cylinder outline as observed on MRI.



### b. Cervical HDR brachytherapy

While cervical cancer remains the most common gynecologic cancer worldwide, in the United States, the incidence of cervical cancer has decreased significantly since the widespread use of Papanicolaou (pap) smears in preventative care. Currently, approximately 12,000 new cases of cervical cancer are diagnosed per year. Treatment options are dependent on the stage of the disease upon clinical exam. Early stage cervical cancers are treated primarily by surgery. Occasionally, post-operative radiation or chemotherapy may be needed. When cervical tumors are not considered to be small enough to be removed by definitive hysterectomy, then curative or neoadjuvant radiation therapy with chemotherapy is the standard of care. In such situations, the patient undergoes combined external beam radiation with brachytherapy to provide high doses of radiation close to the tumor. Such treatments employ a variety of brachytherapy applicators. For most cases, the cervix can be treated using a combination of a tandem and ovoids, ring, or cylinder applicators [7]. However, when significant vaginal and/or parametrial involvement are present, then an interstitial brachytherapy implant may be needed to safely bring the required high doses of radiation to those areas.

At the University of Michigan, a plastic MR compatible ring and tandem applicator (GM11001220 and GM1100760, Varian Medical Systems, Palo Alto, CA, USA) has typically been used for HDR brachytherapy treatment of cervical cancer. This applicator system consists of an intrauterine catheter (tandem) and a circular, ring shaped device that allows the sealed source to be placed adjacent to the cervix (see Fig. 5A). During applicator commissioning which commenced in November 2013, 3D T2 (SPACE) sagittal images (FOV  $300 \times 300 \times 79.2$  mm, voxel size  $0.94 \times 0.94 \times 0.9$  mm, TR 1700 ms, TE 88 ms), 3D T1 (MPRAGE) sagittal images (FOV  $300 \times 300 \times 79.2$  mm, voxel size  $1.17 \times 1.17 \times 0.9$  mm, TR 1900 ms, TE 2.49 ms, TI 932 ms, flip angle  $9^\circ$ ), and multi-planar 2D T2w images at 2–3 mm slice thickness, were acquired with in-house MR markers in each applicator. Although the



4 Para-coronal view of the vaginal cylinder on (4A) CT, (4B) 3D T1w (MPRAGE) MR, and (4C) 3D T2w (SPACE) MR. Following alignment, the overlay of the solid applicator model is depicted for each imaging set in (4D–F).



5 The (5A) plastic and (5B) titanium ring and tandem applicator system used at the University of Michigan (Varian Medical Systems, Palo Alto, CA, USA).

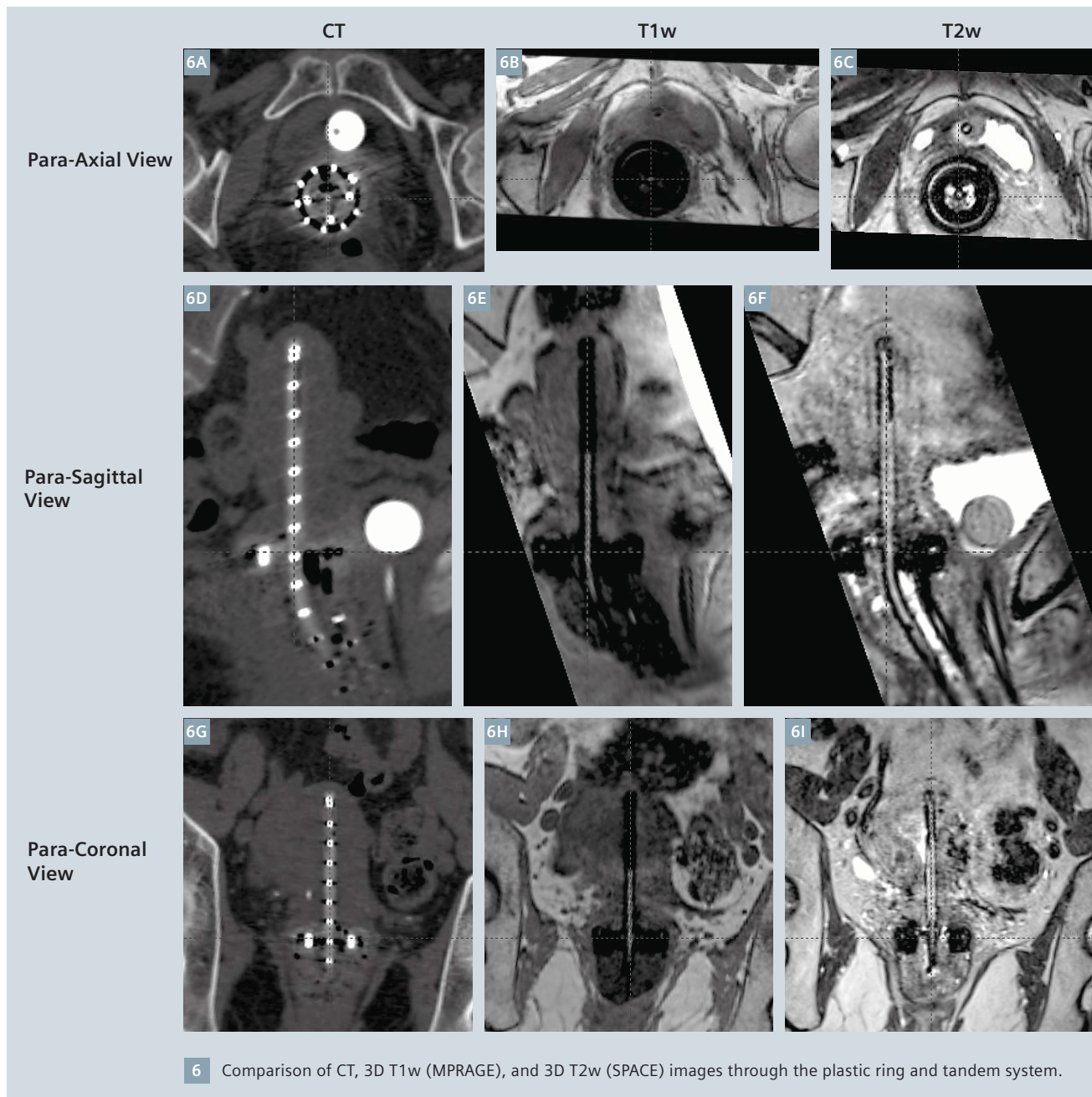
The MRI restrictions (if any) of the metal implant must be considered prior to patient undergoing MRI exam. MR imaging of patients with metallic implants brings specific risks. However, certain implants are approved by the governing regulatory bodies to be MR conditionally safe. For such implants, the previously mentioned warning may not be applicable. Please contact the implant manufacturer for the specific conditional information. The conditions for MR safety are the responsibility of the implant manufacturer, not of Siemens.


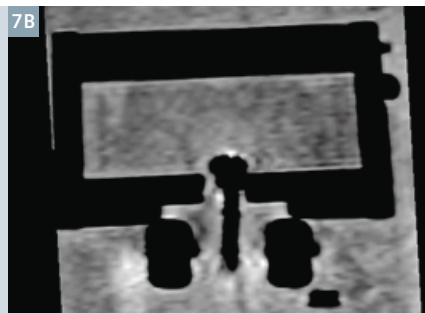

tip of the tandem and ring was not visualized reproducibly due to the compromised seal of the MR markers, the source path and MR marker was discernable on the T1w images (see Fig. 6). As a result of the significantly higher acquisition time for the T2w versus T1w images (nearly twice the scan time), the source channel and MR markers were blurred due to patient and organ motion on the T2w images (see Fig. 6). To minimize scan time, multi-planar 2D T2w images as well as a 3D T1 (VIBE) sagittal scan

with approximately 1 mm voxel size are acquired. Although the 2D T2w planar scans improve the quality of the resulting images, due to the large slice thickness of the 2D versus 3D MRI images, the MR marker was not visible on the 2D images. Therefore, 2D multi-planar T2w images as well as a small FOV 3D T2 (SPACE) sequence are acquired for soft tissue details, and 3D T1 (VIBE) sagittal images are acquired for applicator reconstruction. Prior to treatment planning, the registration of the T1w and T2w images

is verified. If significant patient motion is observed, the images are manually registered in the treatment planning software.

Unlike the vaginal cylinder, a solid applicator model was not available in the treatment planning system for the utilized plastic ring and tandem system. As such, a user defined library plan and applicator model was developed based on the CT reconstruction of the applicator. When a new treatment planning simulation is acquired, the library plan is imported, and the





- 7** Comparison of (7A) CT, (7B) 3D T1w (MPRAGE), and (7C) 3D T2w (SPACE) sagittal images of the titanium ring and tandem system. The applicator set was scanned in a custom phantom designed to hold the applicator in a fixed position (based on [8, 9]). Prior to imaging, the phantom was filled with gadolinium-doped water. As compared to the CT image, magnetic susceptibility effects produce a mushroom effect off the tip of the tandem in the T1w and T2w images, resulting in uncertainties in the identification of the applicator tip on MRI.

applicator model is aligned based on the visible portions of the source channel, specifically focusing on the curvature of the tandem and/or ring.

Following a recent recall of the plastic ring and tandem system (PN BT-01366 Rev A, Varian Medical Systems, Palo Alto, CA, USA), a new titanium ring and tandem system (AL13017000, Varian Medical Systems, Palo Alto, CA, USA) has been purchased by the University of Michigan (see Fig. 5B). Due to susceptibility artifacts, the MR marker is not visible in the titanium applicator [8]. Additionally, these artifacts result in a mushroom effect

off the tip of the applicator, making it challenging to accurately identify the applicator tip on MR (see Fig. 7). Kim *et al.* [9] have reported this effect to be considerably smaller when using a small slice thickness (i.e., 1 mm) T1w versus T2w MRI. With the recent arrival of the titanium ring and tandem system at our institution, the clinical commissioning of this applicator set is currently in progress.

## Conclusions

MRI based image guided brachytherapy has the potential to significantly change the treatment planning pro-

cess. Soft tissue contrast allows the user to customize treatment plans to accurately deliver therapeutic doses to the region-of-interest, while minimizing dose to the normal structures in the vicinity of the tumor, potentially resulting in fewer treatment-related complications. However, the transition from point to volume-based planning requires the user to perform a thorough set of commissioning tests to determine the geometric uncertainties related to their imaging and the associated dosimetric uncertainties.

## References

- Haie-Meder C, R. Potter, E. Van Limbergen *et al.*, Recommendations from Gynaecological (GYN) GEC-ESTRO Working Group (I): concepts and terms in 3D image based 3D treatment planning in cervix cancer brachytherapy with emphasis on MRI assessment of GTV and CTV, *Radiotherapy & Oncology*, 2005;74:235-245.
- R. Potter CH-M, E. Van Limbergen *et al.*, Recommendations from gynaecological (GYN) GEC ESTRO working group (II): Concepts and terms in 3D image-based treatment planning in cervix cancer brachytherapy – 3D dose volume parameters and aspects of 3D image-based anatomy, radiation physics, radiobiology, *Radiotherapy & Oncology*, 2006;78:67-77.
- Hellebust TP, C. Kirisits, D. Berger *et al.*, Recommendations from Gynaecological (GYN) GEC-ESTRO Working Group: Considerations and pitfalls in commissioning and applicator reconstruction in 3D image-based treatment planning of cervix cancer brachytherapy, *Radiotherapy & Oncology*, 2010;96:153-160.
- Dimopoulos JCA, P. Petrow, K. Tanderup *et al.*, Recommendations from Gynaecological (GYN) GEC-ESTRO Working Group (IV): Basic principles and parameters for MR imaging within the frame of image based adaptive cervix cancer brachytherapy, *Radiotherapy & Oncology*, 2012;103: 113-122.
- Balter J, Y. Cao, H. Wang *et al.*, Optimizing MRI for Radiation Oncology: Initial Investigations, *MAGNETOM Flash*, 2013(April): 45-49.
- Small W, S. Beriwal, D.J. Demanes *et al.*, American Brachytherapy Society consensus guidelines for adjuvant vaginal cuff brachytherapy after hysterectomy, *Brachytherapy*, 2012;11:58-67.
- Viswanathan AN, and B. Thomadsen, American Brachytherapy Society consensus guidelines for locally advanced carcinoma of the cervix. Part I: General principles, *Brachytherapy*, 2012;11:33 - 46.
- Haack S, S.K. Nielsen, J.C. Lindegaard *et al.*, Applicator reconstruction in MRI 3D image-based dose planning of brachytherapy for cervical cancer, *Radiotherapy & Oncology*, 2009;91:187-193.
- Kim Y, M. Muruganandham, J. M Modrick *et al.*, Evaluatin of artifacts and distortions of titanium applicators on 3.0-Tesla MRI: Feasibility of titanium applicators in MRI-guided brachytherapy for gynecological cancer, *Int. J. Radiation Oncology Biol. Phys.*, 2011;80(3):947-955.
- Jones, Jeremy. <http://images.radiopaedia.org/images/16912/7bb87421cbd7be3955346f5c27ef93.jpg>. Accessed June 29, 2014.

## Contact

Joann I. Prisciandaro, Ph.D.,  
FAAPM, Associate Professor  
Dept. of Radiation Oncology  
University of Michigan  
Ann Arbor, MI  
USA  
Phone: +1 (734) 936-4309  
[joann@med.umich.edu](mailto:joann@med.umich.edu)



Joann Prisciandaro



Shruti Jolly