

Artis zee - Study Protocol

# Follow-up after stent-assisted aneurysm coiling

Interventional Neuroradiology

## Supported by\*

- syngo InSpace 3D
- syngo DynaCT
- syngo DynaCT 360
- syngo InSpace 3D/3D Fusion
- syngo iPilot enhanced
- syngo iGuide Toolbox
- syngo iGuide
- syngo Neuro PBV IR
- syngo DynaPBV Body
- syngo Embolization Guidance
- syngo iFlow
- syngo Advanced Roadmap
- syngo iIdentify

## Courtesy of

Kiffon Keigher, APN,  
Demetrius K. Lopes, MD,  
Rush University Medical Center,  
Chicago, USA

## System & Software

Artis zee biplane VC21  
syngo X Workplace VB21

*\*This list of applications is not complete. Not all applications available for all software versions.*

## Case Description

### Patient History

73-year-old female patient. Left middle cerebral artery (MCA) aneurysm that was treated with stent-assisted coil embolization in 2005. Because of her history of contrast allergies, we decided to complete a syngo DynaCT run with IV injection of contrast medium in the angiography suite for the purpose of improved visualization and monitoring the patient post IV injection.

### Diagnosis

In 3-D rotational angiography we identified that the left MCA aneurysm was completely occluded, status post stenting and coiling. We were able to obtain accurate visualization of the parent vessel and verify occlusion of this aneurysm and patency of the stent. There was no evidence of in-stent stenosis.

### Treatment

The quality of the study was very good, with no evidence of any other abnormalities in the circle of Willis. She tolerated this imaging study without incident and was discharged home. Our plan will be to follow up with this patient in 12 months with repeated imaging study.

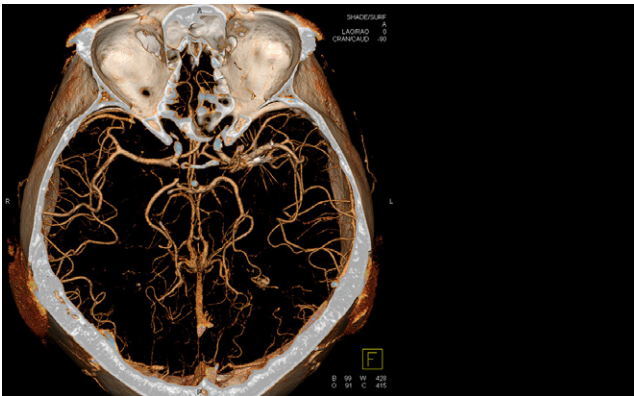
### General Comments

At our institution we are using syngo DynaCT runs with IV injection routinely for patients with the following concerns: stent patency, in-stent stenosis, residual filling of aneurysms s/p clipping and/or coiling, and vasospasm.

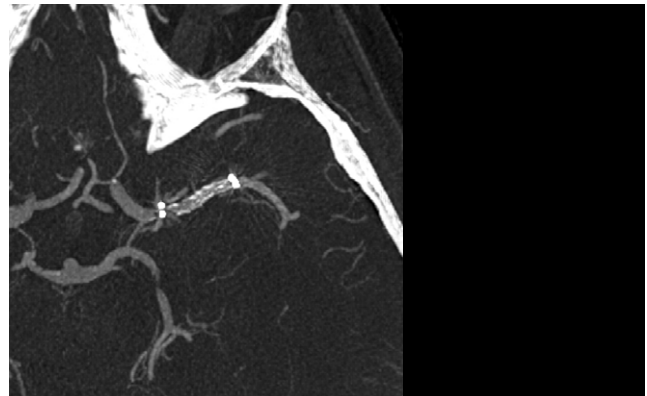
We were able to obtain accurate visualization of the parent vessel and verify occlusion of this aneurysm and patency of the stent.

## Follow-up after stent-assisted aneurysm coiling

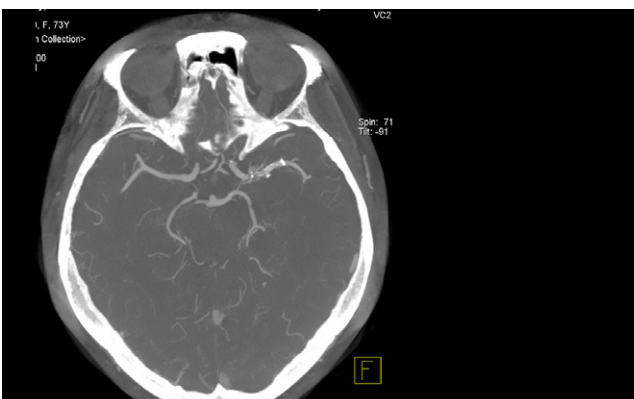
Acquisition Protocol	20sDCT Head 109kV	Reconstruction Protocol	DynaCT Head Nat Fill HU
<b>Injection Protocol</b>		VOI Size:	Full
Contrast Media (CM):	370 mg Iodine/ml	Slice Matrix:	512x512
Dilution (CM/Saline):	No	Kernel Type:	HU
Injection Volume:	80 ml	Image Characteristics:	Normal
Power Injector Used:	Yes	Reconstruction Mode:	Nat Fill
Injection Rate:	4 ml/s	Viewing Preset:	DynaCT Head
Duration of Injection:	20 s	<b>Secondary Recon</b>	In order to improve the visualization of the stent, a 2 <sup>nd</sup> reconstruction with a small size FoV was performed, using the same parameter as for the initial reconstruction.
X-ray Delay:	14 s	VOI Size:	Small
Injection/Catheter Position:	IV injection antecubital vein (18 G) allergy prep medication	Slice Matrix:	512x512
		Kernel Type:	HU
		Image Characteristics:	Normal
		Reconstruction Mode:	Nat Fill
		Viewing Preset:	DynaCT Head



VRT (Volume Rendering Technique) of syngo DynaCT run with IV injection, visualizing the X stent.



Axial MPR reconstruction outlining full patency of the X stent in the left middle cerebral artery (with secondary reconstruction).



Axial MPR reconstruction showing X stent in the left middle cerebral artery.

The statements by Siemens' customers presented here are based on results that were achieved in the customer's unique setting. Since there is no "typical" hospital and many variables exist (e.g., hospital size, case mix, level of IT adoption), there can be no guarantee that other customers will achieve the same results.

On account of certain regional limitations of sales rights and service availability, we cannot guarantee that all products included in this case are available throughout the Siemens sales organization worldwide. All rights reserved.

**Siemens Healthcare Headquarters**  
Siemens Healthcare GmbH  
Henkestr. 127  
91052 Erlangen  
Germany  
Phone: +49 9131 84-0  
[siemens.com/healthcare](http://siemens.com/healthcare)

PDF only. | © Siemens Healthcare GmbH, 2016

[www.siemens.com/healthcare](http://www.siemens.com/healthcare)