An Approach to Semi-Automated Cardiac MR Post-Processing Using *syngo*.via MR Cardiac Analysis

Ryan Avery, M.D.; Puneet Sharma, Ph.D.

University of Arizona Health Network, Department of Medical Imaging, Tucson, AZ, USA

Introduction

Cardiac MRI (CMR) has become the definitive examination for numerous pathologies due to unique pulse sequences that MRI provides to evaluate both cardiac function and tissue. In order to optimize CMR scanning, the introduction of standardized protocols provide an optimal balance between essential pulse sequences and scan time efficiency [1]. CMRI efficiency has been further advanced with the introduction of shorter MR sequences and automated scanning techniques, such as the Cardiac Dot Engine.

Despite these advances, CMR is still encumbered with time-intensive post-processing of these sequences. Manual techniques, such as Argus workflow (Siemens Multi-Modality WorkPlace) and other commercial post-processing software, perform quantitative analysis by user identification and contouring of anatomic structures; i.e., contouring the ventricular myocardium in short axis cine-gated sequences and evaluating vascular flow with phase contrast sequences, which continue to be a tedious component of CMR interpretation.

Siemens' *syngo*.MR Cardio Engine *in syngo*.via offers a semi-automatic workflow that provides an alternative to manual post-processing by utilizing computer-aided detection of the left ventricle and mitral valve position to provide automatic contouring of the left ventricular throughout the cardiac cycle.

The transition from manual cardiac post-processing to a semi-automatic format requires an adaption of the user's previous manual skill-set to the new semi-automatic workflow. In my clinical experience, most user difficulty relates to the adjustment to the more 'hands-off' workflow of automated post-processing. But with direction, users begin to adapt to the new workflow and are able to fully utilize *syngo*.via's semi-automated processing to acquire maximum efficiency.

In order to further propagate this instruction, I will outline a basic CMR post-processing session using *syngo*.via MR Cardiac Analysis with a notable emphasis regarding changes from traditional manual post-processing, and furthermore, how to maneuver out of potential pitfalls.

Technique

CMR scanning requires attention to proper image acquisition in relation to long-axis (LAX) and short-axis (SAX) views and central positioning of the heart within the image (Fig. 1). At our institution, the Cardiac Dot Engine ability to efficiently reproduce long- and shot-axis views of the heart is utilized in conjunction with SCMR protocols [1].

Within *syngo*.via, the MR Cardiac Analysis workflow steps are displayed as rectangular tiles (Fig. 2) notifying the performance of multiple steps of processing, which is a departure from

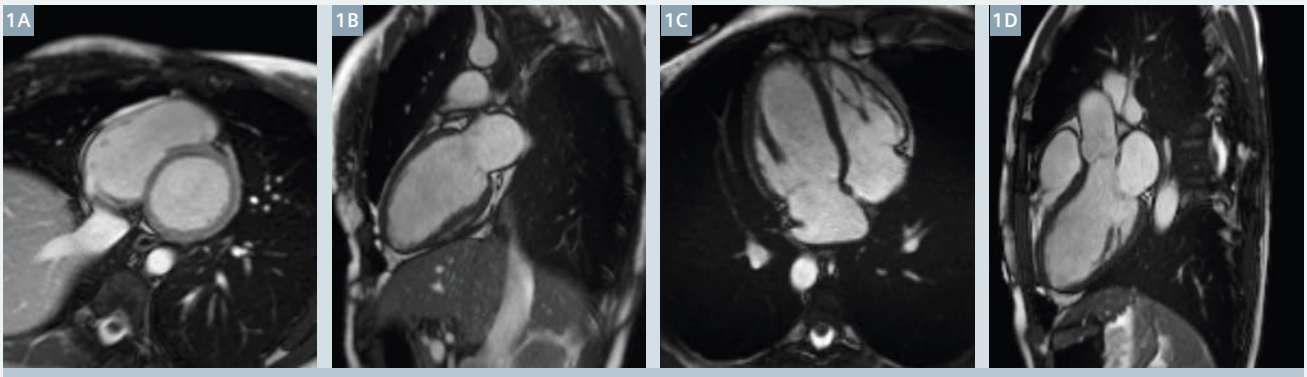

1 Representative SAX and LAX TrueFISP ECG-gated sequences demonstrating proper image orientation and central positioning of the heart.

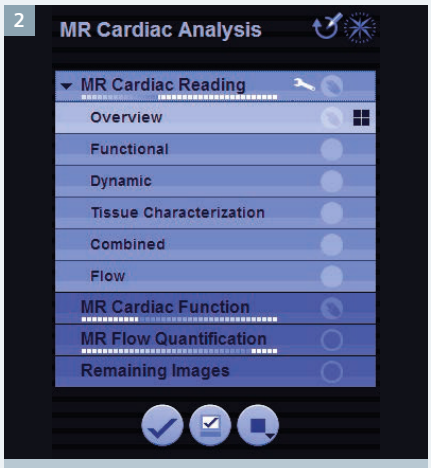

2 MR Cardiac workflow tiles demonstrate progress bars indicating automated processing.

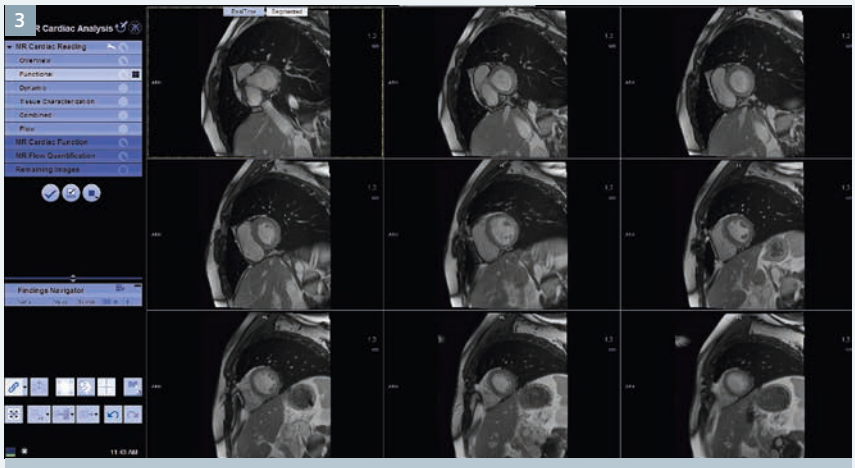

3 Functional workflow displays the SAX and LAX gated sequences in a cine loop. A representative set of SAX is displayed.

manual techniques because *syngo*.via identifies and sorts the sequences necessary for each workflow step and begins post-processing by automatic production of left ventricular base plane and myocardial contouring.

The Overview tile displays all sequences in the order acquired, allowing access to any desired sequence. Progressing to the second tile, Functional, will display the gated sequences for identification wall motion abnormalities (Fig. 3).

Each segmental wall motion abnormality can be display in a color-coded diagram (Fig. 4), which can be archived upon post-processing completion.

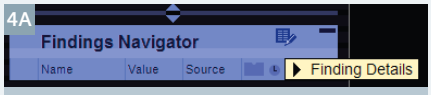

4A Within the Functional step's Finding Details, a color-coded segmental map of wall motion abnormalities can be produced.

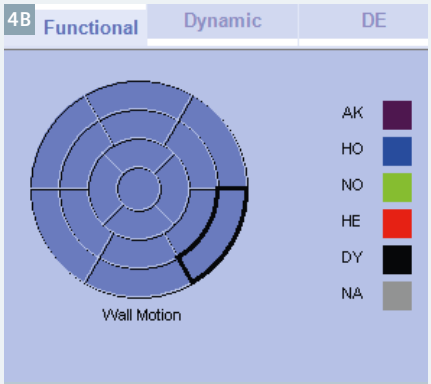

4B Wall segment motion is labeled by clicking on the segment, and then on the color box demarcating the wall motion visualized.

4C With a right click, all unlabeled segments may be labeled as normal.

The Dynamic, Tissue Characterization, and Flow tiles allow directed analysis of perfusion, late gadolinium enhancement, and phase contrast, respectively. Additionally, the Findings section of both Dynamic and Tissue Characterization allow for color-coded diagram production. (It is felt that these steps are similar enough to Functional that a step-by-step discussion is beyond the scope of this article.)

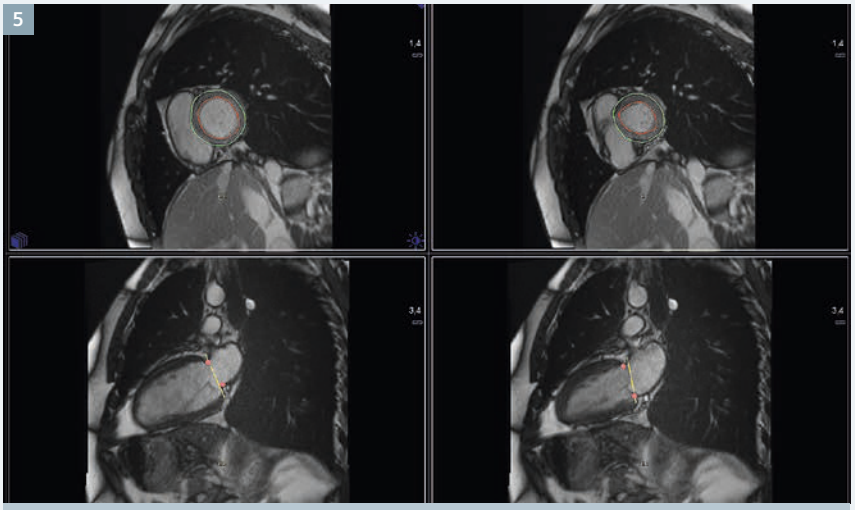

5 First monitor of MR Cardiac Function. The top row is dedicated to SAX views, and the bottom is dedicated to available LAX views. Automated myocardial contours are produced for the SAX (top row), and the designated position of the mitral valve base plane is displayed in the LAX views (bottom row).

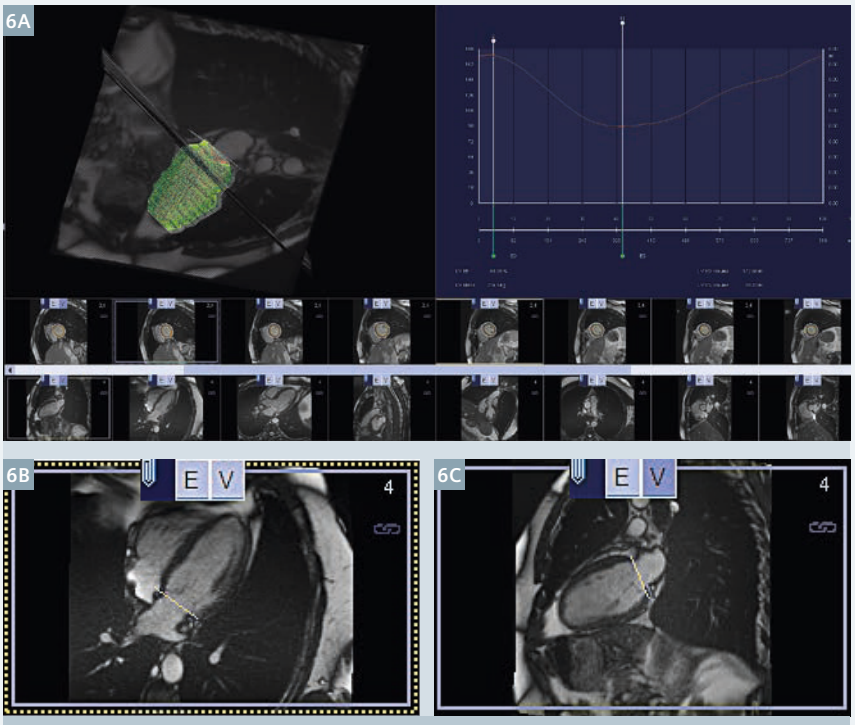

6 Second monitor of MR Cardiac Function. SAX and LAX views can be selected for further processing on monitor 1. A dashed yellow outline designates the image being processed, and any view displayed on monitor 1 has a light blue outline.

The discussion of MR Cardiac Function will assume a 2-monitor display. Monitor 1 is used for active post-processing and displays a 2 x 2 layout with SAX and LAX slices displayed in end-diastole (ED) and end-systole (ES) (Fig. 5).

Monitor 2 displays a row of all SAX views, and a separate row of additional gated-images, which contains the LAX views. Further evaluation of these views on monitor 1 can be performed with left and right arrow keys or mouse-clicking on the preferred slice (Fig. 6).

syngo.via's processing is performed by anatomic localization of key structures including the LV apex, the anterior RV insertion point, and LV blood pool, which are demonstrated by a series of automatically positioned color-coded dots (Fig. 7). If necessary, these localization dots may be modified within their respective tile.

The gated-image chosen to denote ED and ES appear on the image. To modify the image designated as ED or ES, the user can drag ED or ES pin on the volume curve (Fig. 8).

The user can quickly evaluate if the processed SAX contours and anatomic locations are correct, and if so, the apical localization, blood pool, and RV insertion steps can be considered accurate, and the user can proceed directly to the Refine Segmentation step (Fig. 9).

During SAX review, it is recommended that the left column of the first monitor be kept in ED, and the second column in ES (Fig. 10). Since the calculated changes between ED and ES are utilized for quantitative analysis, it is recommended that modification be kept to the ED and ES positions to minimize the amount of manual segmentation and processing data points.

The automated position of the mitral valve base plane uses the LAX views to localize the base of the left ventricle in both ED and ES (Fig. 11). Modification of the base plane can be performed in any LAX view by moving the localization dots.

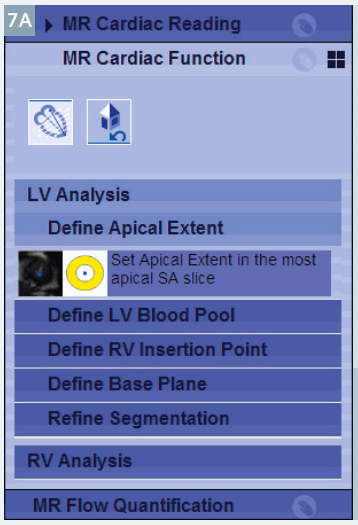

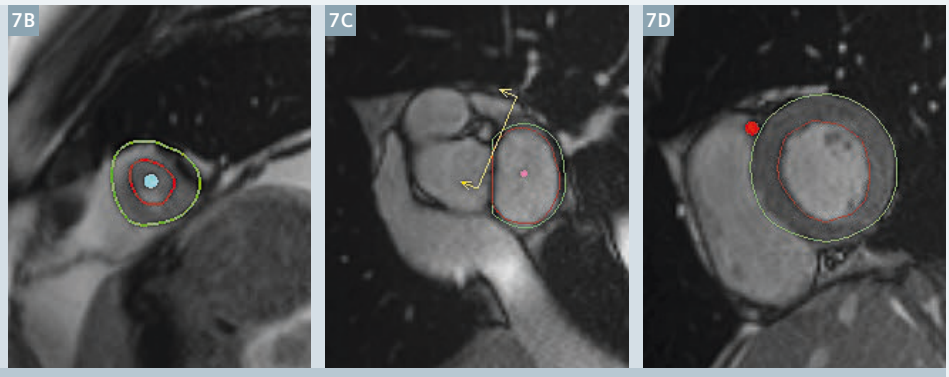

7 MR Cardiac Function interface starts with defining the apical extent, blood pool, and, RV insertions. A single blue dot denotes the position detected as the LV apex. A pink dot placed at the basal LV localizes the central LV blood pool. A red dot outside of the basal LV indicates the location of the RV insertion.

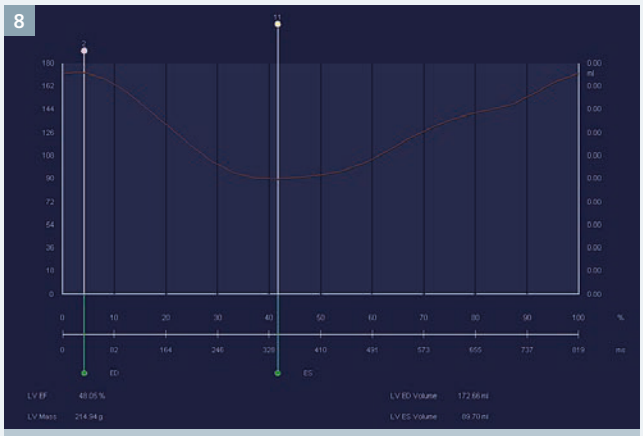

8 A volume curve displays the calculated ventricular volumes throughout the cardiac cycle. Pins designating ED and ES are automatically chosen by *syngo*.via. The image designated as ED or ES can by modified by dragging the pin left or right to the desired curve position.

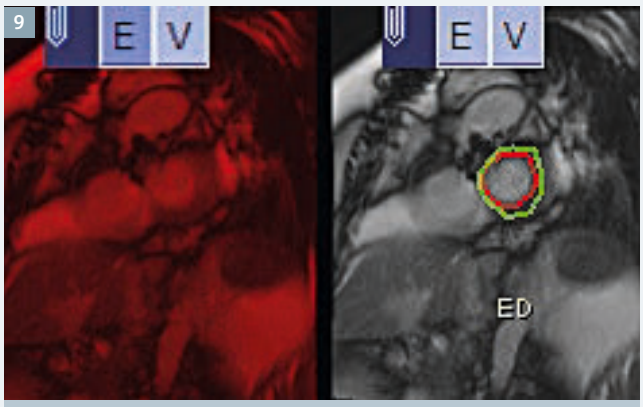

9 The SAX contours can be assessed by right-clicking through the SAX display row. If an image is degraded or unnecessary it may be excluded by clicking the E, which will turn the image red denoting that it's data will not be used in quantitative analysis.

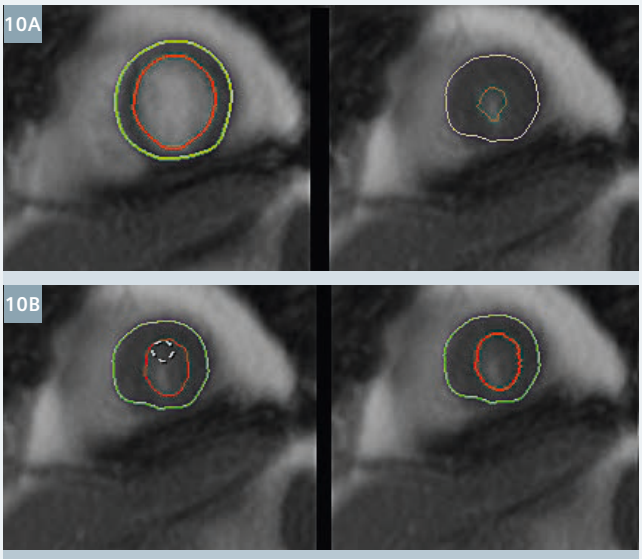

10 A myocardial contour used for processing of all images in series will be shown as a thick line. Initial processing is done in ED, but if the user modifies a contour it will change the line from thin to thick and will be used for contour processing.

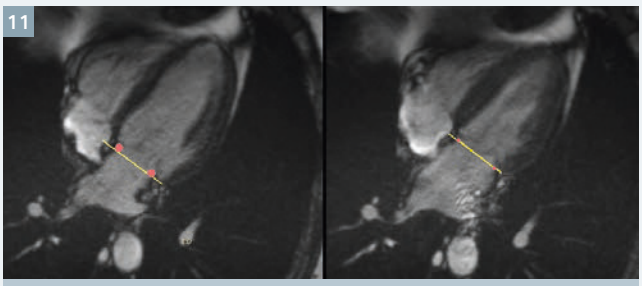

11 Automatic positioning of the mitral valve base plane uses pink localization dots depicting the septal and lateral position of the base plane. Big pink dots are displayed near ED and ES denoting that the image was used for automated processing of the entire cardiac cycle. The user is recommended to only modify the large dots thus decreasing manual post-processing.

Base plane position can be visualized in SAX views as a yellow line with an arrow at the superior and inferior aspects (Fig. 12).

For most CMRs performed, post-processing is complete at this point. Optimally, *syngo*.via should reduce post-processing to a series of visual quality checks confirming proper left ventricle localization and contouring, and mitral valve base plane placement. Manual post-processing, if necessary, should be reduced to simple nudging of portions of the contours and optimization of base plane position.

Some CMRs will require an advanced level of post-processing including RV evaluation and vascular flow quantification, which can also be performed with *syngo*.via using additional steps included in MR Cardiac Analysis.

Right ventricle assessment

The first step of RV Analysis requires manual contouring of each SAX position in ED. With the manual production of a single contour in ED, *syngo*.via will automatically generate contours for the remainder of the cardiac cycle.

Drawing a contour in a single motion using the free-hand tool is recommended because the processing time required for multiple steps may become tedious. After each contour generation, evaluation of the processed ES contour is recommended to assess accuracy and the possible need for editing (Fig. 13).

To produce the tricuspid valve base plane, the 4-chamber view is used to manually identify the RV base plane margins in ED. After the RV base plane is produced in ED, the RV basal margins must again be localized in the ES view to complete RV base plane processing (Fig. 14).

To complete ventricular processing, using the Join Function tool within Refine Segmentation will smoothly join the contours of both ventricles throughout the cardiac cycle (Fig. 15) producing a more accurate anatomic assessment.

Flow quantification

The MR Flow Quantification tile is used for phase contrast post-processing. This workflow step can perform vessel contouring with one step with the use of the auto-contour tool (Fig. 16).

If multiple phase contrast views are performed, the additional sequences dragged into the MR Flow Quantification layout from the sequence browser by clicking on the arrow on the right side of the display on the first monitor.

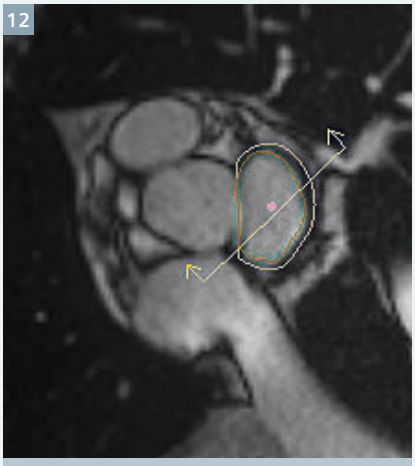

12 Base plane in SAX. The arrows arising from the LV base plane line denote the contour volumes included in the ventricular volume and mass.

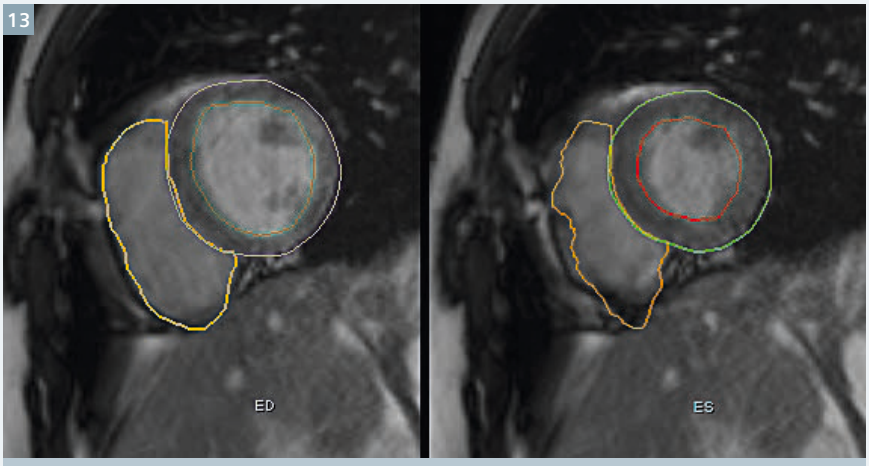

13 The RV contour is drawn for each slice of the SAX in ED. The processed ES contour should be visually assessed after ED contouring. Any refinement of the ES should be performed before moving to the next SAX position.

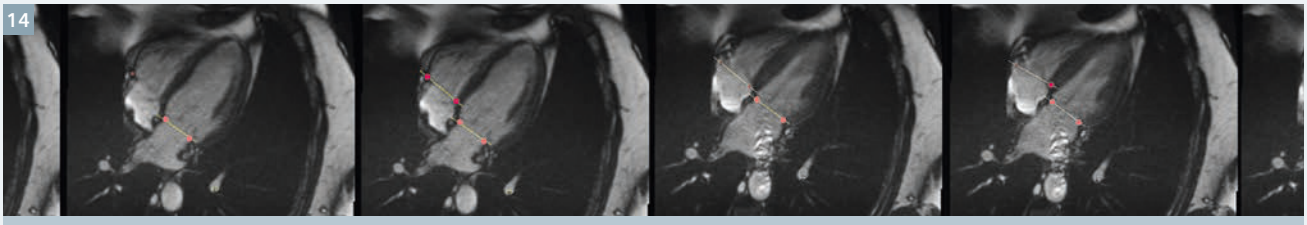

14 Sequential demonstration of Semi-Automated production of the RV base plane. Starting in the ED 4-chamber view, the user will click on the lateral and septal margins of the RV base producing 2 large dots, and the RV base plane line will then form between the dots. Next, in ES the dots are dragged to the proper position of the RV base allowing *syngo*.via to complete processing for the RV base plane throughout the cardiac cycle.

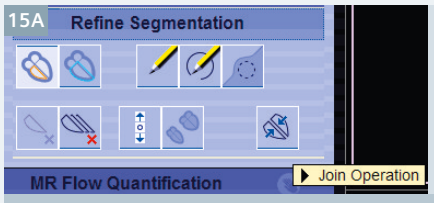

15 Clicking the Join Function tool will combine the septal portion of the RV contours with the LV contours.

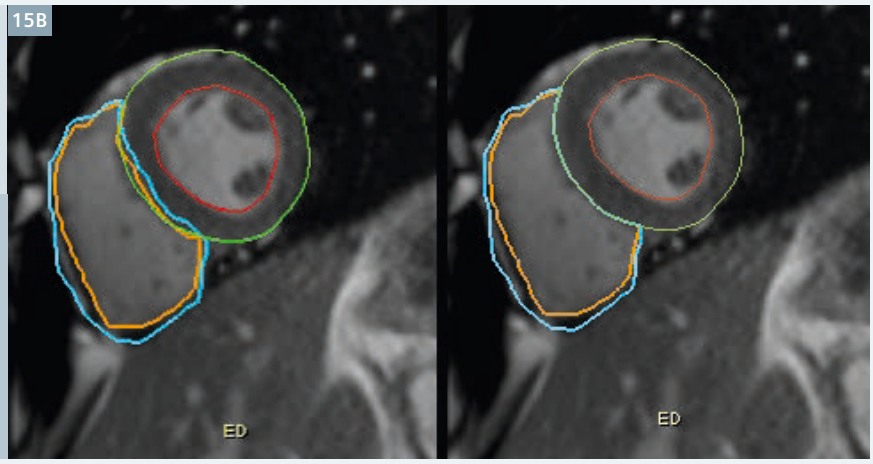

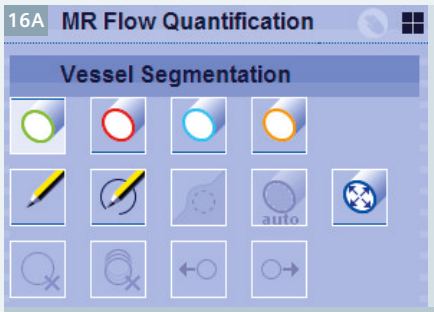

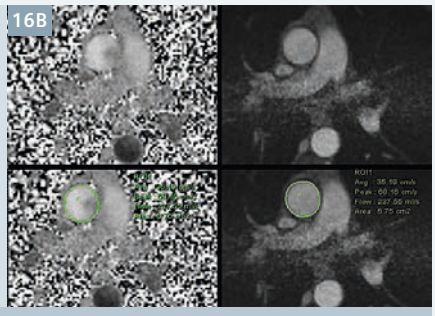

16 The One-Click Vessel Segmentation tool allows MR Flow Quantification to be performed in a single step by a clicking once in the vessel center of an in-plane phase contrast view, which produces an accurate contour of the vessel throughout all images in the sequence.

17 Miscalculation of the LV contours is often related to the entire heart being seen as the LV due to an excessively large image acquisition window during MR scanning.

At this stage, post-processing for even more advanced CMRs is completed, and the Finding Details icon can be clicked so ventricular and vessel quantitative data can be saved by clicking on the Create Findings button, which will allow the results to be archived upon completion of the study.

Pitfalls

Given the variability of cardiac anatomy and image acquisition, *syngo*.via post-processing can falter. Solving these miscalculations can be quite tedious if the user applies manual troubleshooting techniques. However, if approached with an appreciation of semi-automated processing, *syngo*.via can be leveraged to correctly redraw the LV in a short series of steps.

Since most miscalculations result from automated contouring of the wrong anatomic structure or the entire heart (Fig. 17), most cases can be solved by insuring that the SAX stack images are well centered within an appropriate sized acquisition window.

Within *syngo*.via, the first step to correct an LV miscalculation is to reposition the apical dot while in the Apical Localization step. Repositioning the blue dot will result in repeat auto-segmentation producing a new set of myocardial contours and repositioning the LV base plane.

If repositioning of the apical dot does not succeed, I recommend deleting all LV contours with the Delete Contours tool (Fig. 18A), and redrawing in ED the contours for a single SAX slice in the middle of the LV, which automatically produces contours throughout the cardiac cycle for the single SAX image (Fig. 18B). Next, clicking the Spatial Propagation tool will produce automated contours for the remaining SAX stack images (Fig. 18C).

After redrawing the LV contours, the LV base plane position should

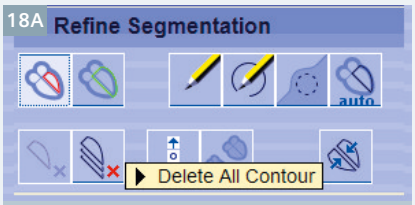

18A Delete Contours in both endocardial (red contour) and epicardial mode (green contour) to remove all LV contours.

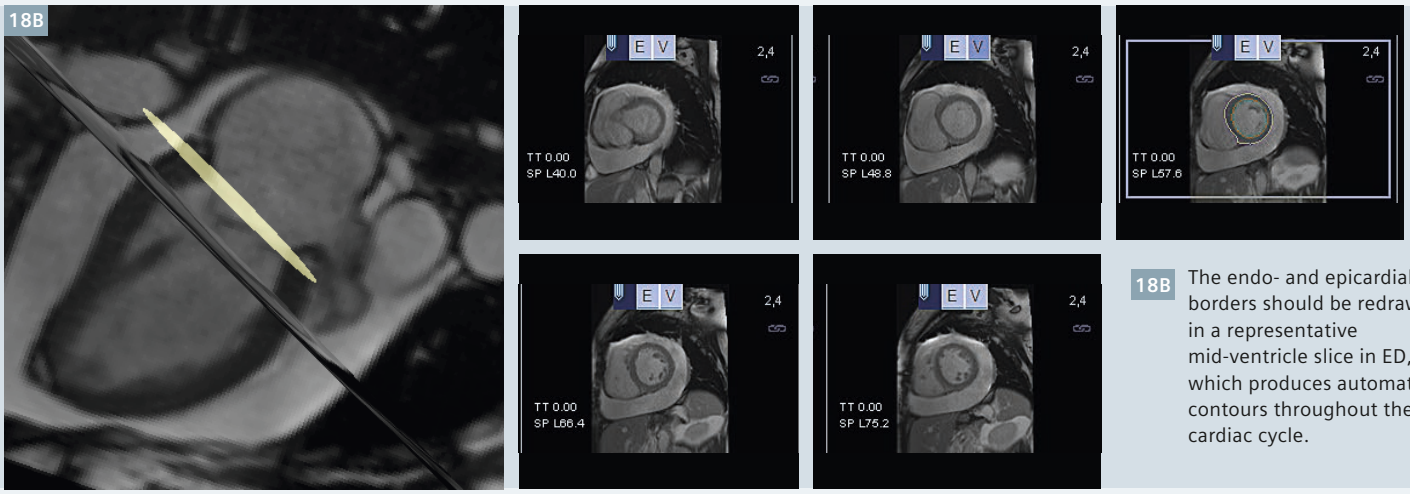

18B The endo- and epicardial borders should be redrawn in a representative mid-ventricle slice in ED, which produces automated contours throughout the cardiac cycle.

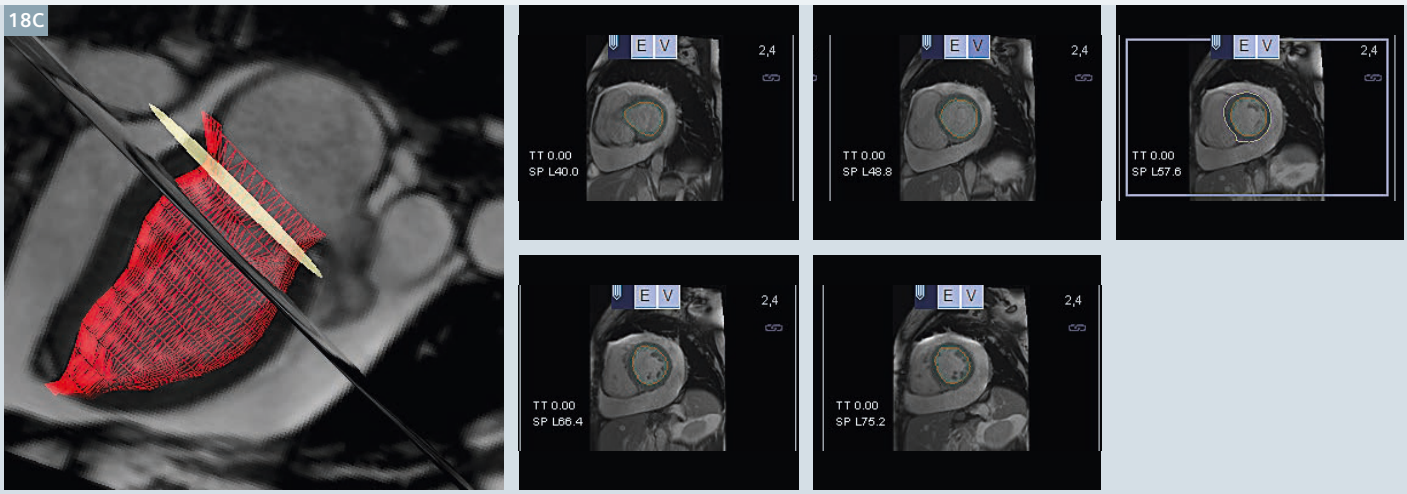

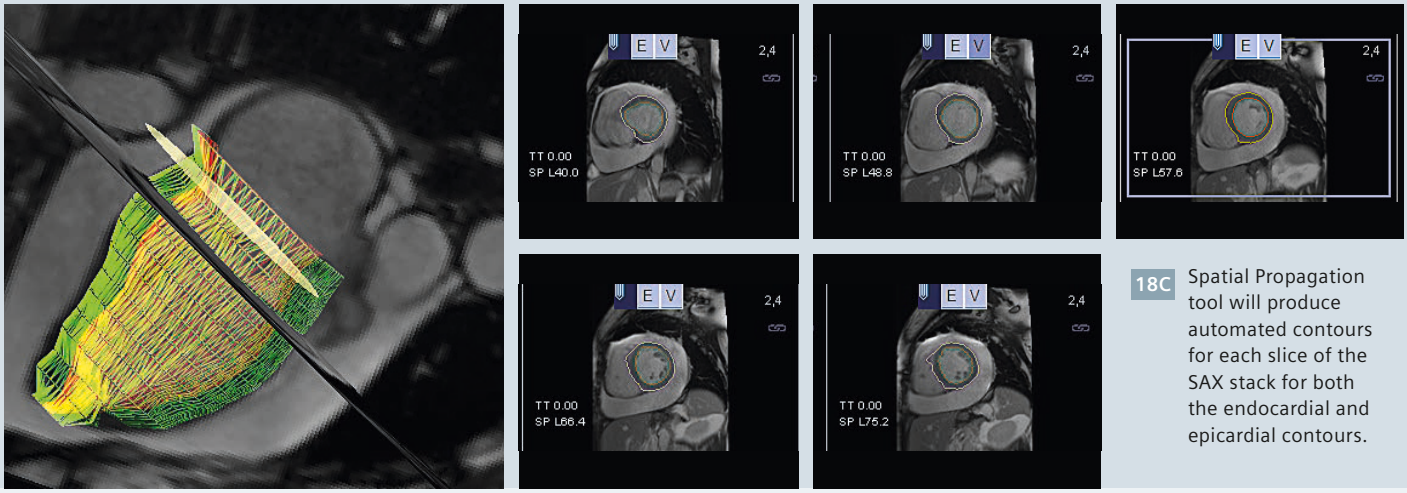

18C Spatial Propagation tool will produce automated contours for each slice of the SAX stack for both the endocardial and epicardial contours.

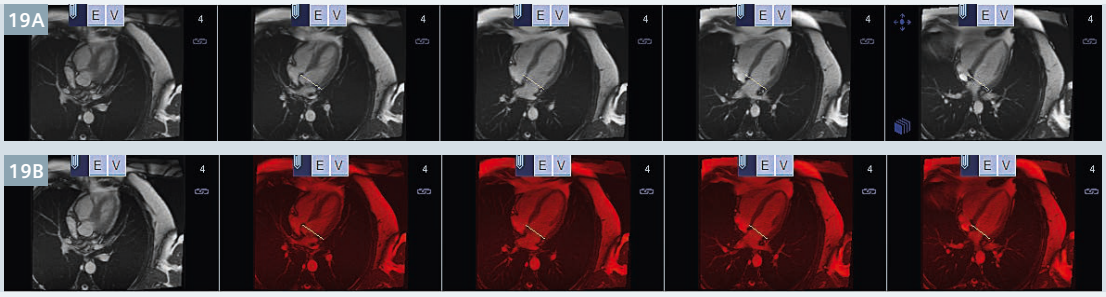

19 Exclusion of extraneous LAX images, and retention of the 2-, 3-, and 4-chamber LAX views will optimize automated LV base plane localization.

be checked in the LAX views and modified, if necessary, by optimal placement of the large dots.

Some CMR protocols require multiple LAX gated-cine images. If these sequences become accidentally integrated into MR Cardiac Function, the unnecessary LAX views should be excluded with the E button (Fig. 19).

If the LV base plane continues to be incorrect, use the ED/ES tool to restrict contouring to ED and ES thus requiring manual contouring to account for the mitral valve in SAX views. The ED/ES tool will convert *syngo*.via's processing software to a more manual workflow using only ED and ES contouring for quantitative analysis.

Conclusion

The semi-automatic post-processing offered by *syngo*.via provides an essential step forward in CMR efficiency. Complete post-processing automation is desirable for efficient clinical workflows. However, although single fully automated inline post-processing applications already demonstrated clinical value with respect to "higher interobserver and intraobserver reliability as well as a better time efficiency" [2], the complete semi-automated post-processed reading workflow offered by *syngo*.via provides an essential step forward in CMR efficiency.

To optimize semi-automatic post-processing, the user's manual skill set needs to be modified to the 'hands-off' semi-automated approach, which encourages less direct software interaction. As users transition their skill-set, it has been my experience that post-processing time dramatically improves while retaining high quantitative accuracy, which overall facilitates the movement of CMR into wider clinical application.

References

1 Kramer CM, Barkhausen J, Flamm SD, et al. Standardized cardiovascular magnetic resonance (CMR) protocols 2013 update. J Cardiovasc Magn Reson 2013. Oct 15:91.

2 Doesch C., et al. Detection of Myocardial Ischemia by Automated, Motion-Corrected, Color-Encoded Perfusion Maps Compared With Visual Analysis of Adenosine Stress Cardiovascular Magnetic Resonance Imaging at 3 T Invest Radiol 2013. 48:678.

Contact

Ryan Avery, M.D.
University of Arizona Health Network
Dept. of Medical Imaging
1501 N Campbell Ave
PO Box 245068
Tucson, AZ 85724
USA
ravery@radiology.arizona.edu

Did you know that ...

You can download SCMR recommended protocols with the Cardiac Dot Engine at

www.siemens.com/SCMR-recommended-protocols

"One of the most impressive features of the Cardiac Dot Engine is the fully automated user-independent Inline left ventricular analysis. The software instantaneously delivers all functional parameters without a single mouse click directly after the last acquisition of the cine sequences. This technology enables a complete functional assessment of the heart with all qualitative and quantitative parameters within just 14 minutes!"

Axel McKenna-Küttner, Radiology and Nuclear Medicine, Sportklinik Bad Nauheim, Germany

"In cardiac imaging a single mouse click will change, for example, the cardiac gating of all following sequences."

Stefan Schönberg, Institute of Clinical Radiology and Nuclear Medicine, University Medical Center Mannheim, Germany

"The main benefit of the Dot engines is to decrease the complexity of MR and to further standardize MR-examinations. It allows follow-up examinations to be conducted with the same parameter settings and hence with constant image quality over time, which is particularly important for quantitative evaluation of lesions in therapeutic clinical and research studies."

Stefan Schönberg, Institute of Clinical Radiology and Nuclear Medicine, University Medical Center Mannheim, Germany

More clinical articles, tips & tricks, talks on Siemens unique Dot engines at

www.siemens.com/magnetom-world-dot