SIEMENS

Partial Vertebral Compression Defined by xSPECT Bone

By **Solène Querellou, MD, and Pierre-Yves Salaun, MD**

Data courtesy of the Department of Nuclear Medicine, CHRU Brest, France

History

A 65-year-old female (157.5 cm [5 ft 2 in], 50.8 kg [112 lbs]) presented with severe back pain. X-rays of the lumbar vertebrae showed compression of the L2 vertebrae. The patient was referred for ^{99m}Tc DPD bone scan to evaluate the nature of the vertebral compression. The patient underwent an xSPECT Bone* study on a Symbia Intevo™* with integrated thin-slice diagnostic CT of the lower thoracic and lumbar spine and pelvis. Standard 3D iterative reconstructions and xSPECT Bone reconstructions were obtained for comparison. xSPECT Bone was further fused with CT.

Diagnosis

xSPECT Bone showed sharper delineation of increased skeletal uptake in the anterior half of the body of the L2 vertebrae, along with vertical shortening, when compared to 3D iterative reconstruction, which showed ill-defined focal accumulation in the vertebral body (*Figure 1*). xSPECT Bone coronal slices sharply delineated the upper and lower vertebral end plates and defined the vertical shortening, suggesting partial vertebral collapse. The L2-L3 intervertebral disc space was slightly narrowed with irregularity in the L2 lower-end plate, thus reflecting the partial collapse. The sagittal xSPECT Bone image better defined the anterior vertebral collapse with sharp delineation of the increased tracer uptake in the anterior half of the partially collapsed L2 vertebral body. As well, there was slightly increased uptake in the anterior part of the upper end plate of the L3 vertebrae, which appeared to be a reactive change that was secondary to the L2 vertebral collapse. The anterior wedge collapse also caused distortion and exaggeration of the normal spinal curvature. Transverse slices through the region of increased uptake in the L2 vertebrae showed sharp delineation of uptake in the anterior part of the vertebrae and extended up to the cortical bone of the anterior vertebral margin. The rest of the vertebral bodies showed considerable degenerative changes.

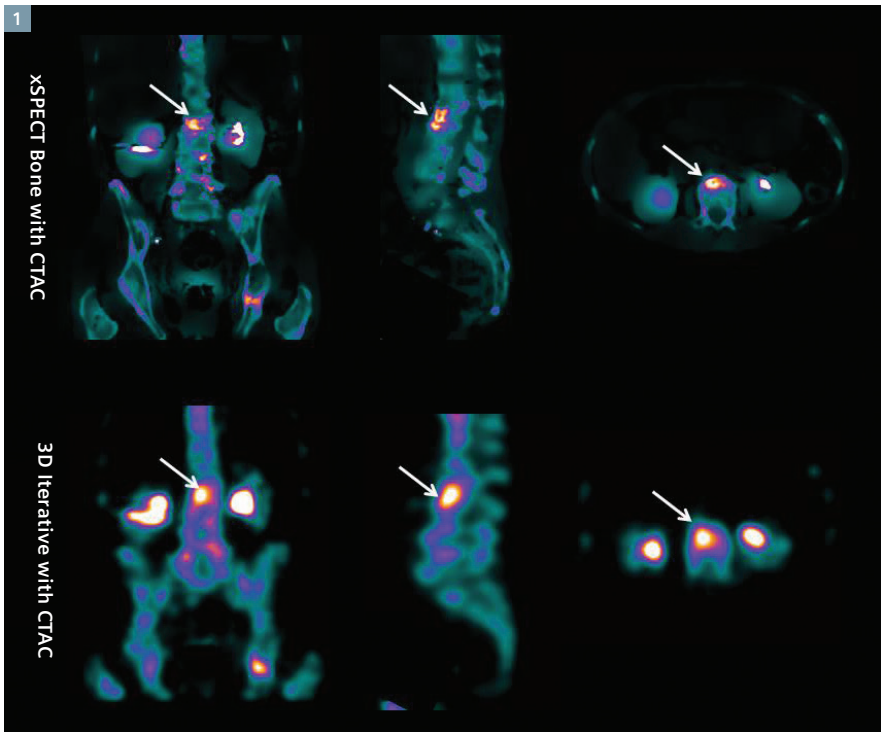

1 xSPECT Bone showed sharper delineation of increased skeletal metabolism in the anterior half of the body of the L2 vertebrae (*arrows*), along with vertical shortening, when compared to 3D iterative reconstruction, which showed ill-defined focal accumulation in the vertebral body.

In comparison, 3D iterative-reconstructed images showed ill-defined focal uptake in the vertebral body, which can merely be recognized as related to partial vertebral involvement, but without clear definition and blurred lesion margins. Clear definition of the vertebral collapse and its extent was not possible from the 3D iterative-reconstructed images.

CT images (*Figure 2* and *3*) showed anterior wedge compression of the L2 vertebral body with sclerosis in the

anterior part; severe distortion of the upper vertebral end plate; a decrease in the L2-L3 intervertebral disc; and slight sclerosis of the anterior part of the upper vertebral end plate of the L3 vertebrae. Fusion of xSPECT Bone and CT showed exact co-registration of the areas with increased uptake to the regions of focal sclerosis. Transverse CT slices showed sclerosis in the anterior aspect of the L2 vertebral body, interspersed with hypo-intense zones that reflected osteoporotic vertebral compression. Fusion of xSPECT Bone and CT showed exact co-registration of the sharply delineated zone of increased uptake in the anterior aspect of the vertebral body to the zone of sclerosis, reflecting the partial and anterior nature of the collapse. The posterior part of the vertebral body, transverse processes, facet joints and spinal canal appeared normal. Overall, CT showed significant decrease in trabecular density in the uninvolved vertebral bodies, suggesting severe osteoporosis. xSPECT Quant* estimation of SUV in the normal-appearing L1 vertebrae showed an SUV_{max} of 3.9 and an SUV_{avg} of 3.23, which was significantly lower than the normal average (Mean SUV of 5.91 ± 1.54) for this age group based on published literature.[1]

Comments

xSPECT Bone sharply delineated the increased uptake in the anterior half of the L2 vertebrae and the upper end plate of the L3 vertebrae, which co-registered exactly with the sclerosis seen on CT, clarifying, therefore, the diagnosis of partial anterior wedge collapse of the L2 vertebrae, secondary to osteoporosis, along with evidence of distortion of the spinal curvature secondary to collapse. Standard 3D iterative-reconstructed SPECT images did not show such sharp delineation of lesion due to lower resolution and blurred lesion margins. Exact characterization of the vertebral collapse was better performed with xSPECT Bone. The presence of severe osteoporosis was confirmed by the quantification of ^{99m}Tc MDP uptake in the lumbar vertebrae using xSPECT Quant, which

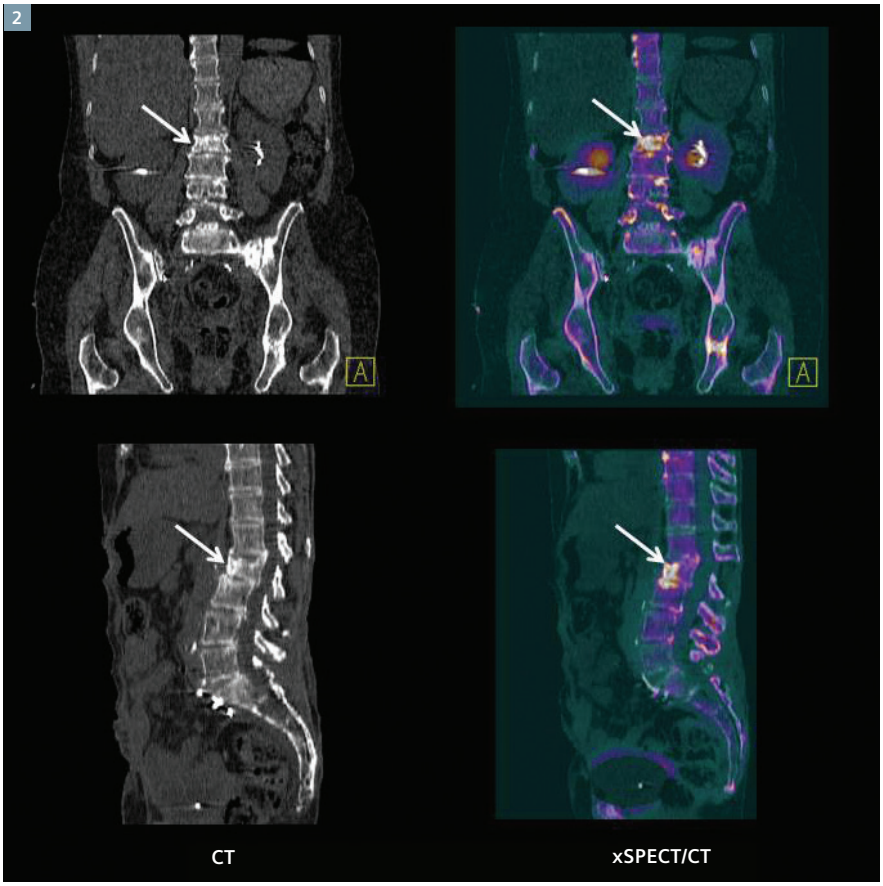

2 CT showed anterior collapse of the L2 vertebrae, with fused images showing exact matching of increased uptake with the sclerosis in the collapsed vertebrae.

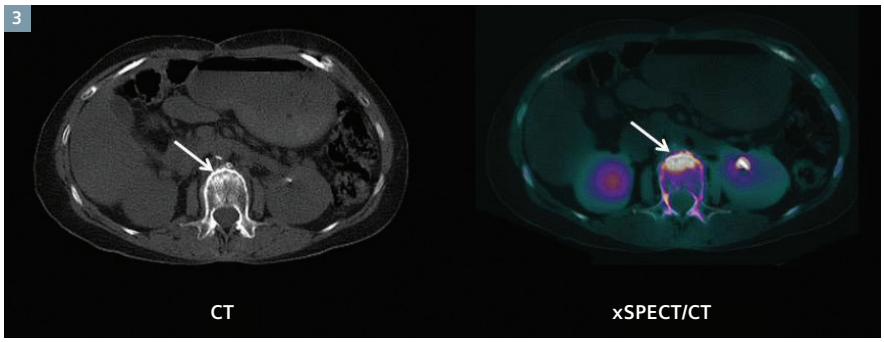

3 Transverse CT slices showed sclerosis in the anterior aspect of the L2 vertebral body interspersed with hypodense zones that reflected osteoporotic vertebral compression. Fusion of xSPECT Bone and CT showed the exact co-registration of the sharply delineated zone of increased uptake in the anterior aspect of the vertebral body to the zone of sclerosis reflecting the partial and anterior nature of the vertebral compression.

showed significantly reduced SUV of the spongy bone in the vertebral body of the L1 vertebrae that is not affected by the vertebral collapse, when compared to the normal average for the same age group.

Conclusion

xSPECT Bone demonstrated sharp delineation in areas of increased tracer uptake, providing increased image quality and, subsequently, more precise characterization of pathology.

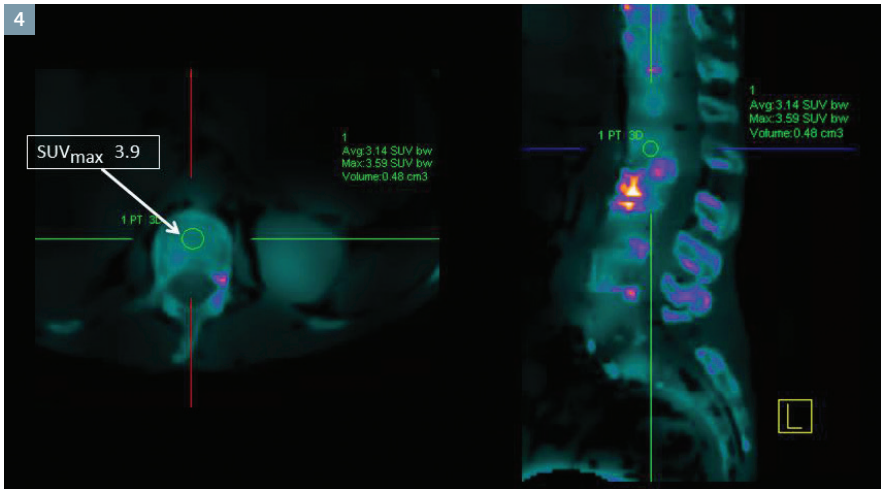

4 xSPECT Quant evaluation of SUV in the spongy bone of the vertebral body of the normal-appearing L1 vertebrae showed an SUV_{max} of 3.9 and an SUV_{avg} of 3.23.

Examination Protocol

Scanner	Symbia Intevo
Injected Dose	472 MBq (12.72 mCi) of ^{99m}Tc DPD
CT	130 kV, 50 eff mAs, 2x2.5 mm collimation; B80s kernel reconstruction
SPECT	60 frames 10 sec per frame
3D OSEM Reconstruction	8 iterations; 15 subsets; 128x128 matrix; output pixel size, 4.8 mm; Gauss filter, 12 mm
xSPECT Bone Reconstruction	4 iterations; 21 subsets; 256x256 matrix; output pixel size, 2 mm; Gauss filter, 10 mm

References:
1. **Cachovan et al.** *EJNMMI Research*. 2013. 3: 45.

* Symbia Intevo, xSPECT, xSPECT Bone and xSPECT Quant are not commercially available in all countries. Due to regulatory reasons their future availability cannot be guaranteed. Please contact your local Siemens organization for further details.