

SIEMENS

White Paper

FDG PET/CT and Cervical Cancer

Dr. Kristin Schmiedehausen

Answers for life.

Table of Contents

Executive Summary	1
Introduction	1
Diagnosis of Cervical Carcinoma	2
Current Status	2
Guidelines	2
Reimbursement	2
Initial Assessment of the Disease Extent	2
Current Status	2
Primary Tumor	2
Lymph Node Staging	2
Detection of Distant Metastases	3
Guidelines	3
National Comprehensive Cancer Network (NCCN)	3
Workup	3
Incidental Finding of Invasive Cervical Cancer	3
European Society for Medical Oncology (ESMO)	3
Reimbursement	3
PET/CT in Radiotherapy Planning for Cervical Cancer	4
Current Status	4
External Beam Radiation	4
Brachytherapy	4
Guidelines	4
NCCN	4
ESMO	4
Reimbursement	4
Treatment Response Monitoring	5
Guidelines	5
NCCN	5
ESMO	5
Reimbursement	5
Long-Term Follow-Up	5
Current Status	5
Guidelines	5
NCCN	5
ESMO	5
Reimbursement	5
FDG PET/CT and Prognosis	6
Current Status	6
Guidelines	6
NCCN	6
ESMO	6
Reimbursement	6
The Impact of Technological Advances—Outlook	6
References	7

Executive Summary

Positron emission tomography (PET) combined with computed tomography (CT), often referred to as PET/CT*, is a powerful modality to assess cervical cancer, in particular in tumors of stage IB and beyond. Fludeoxyglucose F18 Injection** is used to assess abnormal glucose metabolism and can depict, for example, lymphatic involvement and distant metastases. This may promote the use of PET/CT for personalized treatment triage and planning in patients with cervical cancer. Existing data suggest that the prognostic value derived from a pre-therapeutic FDG PET/CT scan can help in identifying subgroups of patients with higher risk, and the prognostic role of a PET/CT post-therapy follow-up has been established. The current potential of FDG PET/CT in cervical cancer is reflected in its integration into selected national cancer therapy guidelines and reimbursement policies.

Fludeoxyglucose F18 5-10mCi as an IV injection

**Indications and Usage

Fludeoxyglucose F 18 Injection (¹⁸F FDG) is indicated for positron emission tomography (PET) imaging in the following settings:

- **Oncology:** For assessment of abnormal glucose metabolism to assist in the evaluation of malignancy in patients with known or suspected abnormalities found by other testing modalities, or in patients with an existing diagnosis of cancer.

Important Safety Information

- **Radiation Risks:** Radiation-emitting products, including Fludeoxyglucose F 18 Injection, may increase the risk for cancer, especially in pediatric patients. Use the smallest dose necessary for imaging and ensure safe handling to protect the patient and health care worker.
- **Blood Glucose Abnormalities:** In the oncology and neurology setting, suboptimal imaging may occur in patients with inadequately regulated blood glucose levels. In these patients, consider medical therapy and laboratory testing to assure at least two days of normoglycemia prior to Fludeoxyglucose F 18 Injection administration.
- **Adverse Reactions:** Hypersensitivity reactions with pruritus, edema and rash have been reported; have emergency resuscitation equipment and personnel immediately available.

Full prescribing information for Fludeoxyglucose F 18 Injection can be found on page 12.

Fludeoxyglucose F 18 injection is manufactured by Siemens' PETNET Solutions, 810 Innovation Drive, Knoxville, TN 39732

Introduction

Cervical cancer is a malignant tumor arising from cells that originated in the cervix uteri. It is the fourth most common cancer in women, and around 85% of the global burden occurs in the less developed regions, where it is a leading cause of cancer death among women.¹ In 2012, there were 528,000 new cases and 266,000 deaths worldwide.² According to the National Cancer Institute (NCI), 12,360 new cases of cervical cancer and 4,020 deaths are projected in the United States in 2014.³ In addition to other risk factors, infection with human papilloma virus (HPV) is the main cause of this disease.⁴ Because of its dominant prevalence in underserved countries where sophisticated technology is not available, cervical cancer is staged clinically. The International Federation for Gynecology and Obstetrics (FIGO) evaluation procedures for staging gynecologic cervical cancer excludes complex radiologic and surgical staging procedures.^{5,6,7} Acceptable staging procedures include X-ray exams, colposcopy, biopsy, conization, cystoscopy, and proctosigmoidoscopy. The results of surgical staging or additional advanced imaging tests may aid in treatment planning but are not accepted for formal staging purposes and procedures. Most medical centers in developed countries employ cross-sectional imaging to overcome the limitations of traditional diagnostic methods and use the results for prognostic information, treatment guidance and planning.^{6,5,7}

PET/CT merges metabolic information with structural imaging. The distribution of the radiopharmaceutical ¹⁸F FDG reflects glucose metabolism, which is increased in many malignant cells. In the last years, PET/CT has demonstrated its impact on patient management in oncology.^{8,9,10,11,12} As for cervical cancer and other gynecologic malignancies, the significant increase in published literature about PET/CT correlates with the growing interest of clinicians in the complementary information that is provided by this promising modality.⁷

*In this paper, the term "PET/CT" includes standalone PET as well as combined PET/CT.

Diagnosis of Cervical Carcinoma

Current Status

The majority of cervical carcinomas are squamous cell carcinoma, followed by adenocarcinoma, sarcoma and other rare malignancies. Clinical examination and cervical biopsies normally establish the diagnosis of a cervical carcinoma.

The FDG accumulation in the healthy cervix is not significantly more intense than that of the surrounding tissue.¹³ Of note is that in premenopausal women, the endometrial FDG uptake varies during the menstrual cycle with two peaks during the ovulatory and menstrual phase, respectively.¹⁴ Since the presence of urinary bladder activity can impair assessment of the pelvis, patients should always void before PET/CT, and sometimes urinary bladder catheterization or diuretic administration is needed.¹⁵ Almost all primary cervical cancers of at least 7 mm diameter demonstrate increased FDG avidity^{16,17}, except for necrotic areas or areas within the uterine cavity (which might be distended by the accumulation of blood, pus, or serous fluid as a consequence of the malignant obstruction of the endocervical canal).^{17,15,18} The intensity of the FDG uptake in the tumor depends on the tumor grade and other histologic parameters¹⁹ and correlates with tumor proliferation. A high maximum standardized uptake value (SUV_{max}^*) is associated with a poorly differentiated tumor.¹⁹ In particular, squamous cell carcinoma and poorly differentiated cervical malignancies have a higher FDG uptake.²⁰

Guidelines

Neither the NCCN nor the ESMO recommends the use of PET/CT in the primary diagnosis of cervical cancer.

Reimbursement

The United States Centers for Medicare & Medicaid Services (CMS) do not cover an FDG PET for initial diagnosis of cervical cancer related to the Initial Treatment Strategy (formerly Diagnosis and Staging).²¹

Initial Assessment of the Disease Extent

Current Status

Primary Tumor

Even though the local extent of a cervical tumor is often determined by clinical examination, imaging provides important information regarding extra cervical tumor manifestation, as well as the presence of distant metastases. Most primary tumors exceeding one centimeter in diameter are detectable with FDG PET/CT¹⁵, and an encouraging publication showed a good correlation between the diameter of a tumor in early-stage cervical cancer in the FDG image and the diameter as measured at pathologic analysis.²² FDG PET/CT also can be helpful in identifying ureteral obstruction or encasement and also bladder or rectal involvement. Especially in those scenarios, a detailed reading of the PET and the coregistered diagnostic CT is of utmost importance.¹⁵ PET/CT also has been very helpful in delineating the tumor margins in cases when the tumor had spread either superiorly into the uterine cavity or inferiorly into the vagina.^{23,15} Nevertheless, subtle structural changes such as parametrial invasion might not be apparent because of the limited spatial resolution of the PET component.¹⁵ Higher spatial resolution of the PET component as in the newest generation PET/CT devices might help to detect more subtle changes than with conventional PET/CTs.

Lymph Node Staging

Cervical cancer initially expands and spreads first regionally, followed by lymphatic spread and lastly, hematogenous dissemination to distant organs. For patients with locally advanced tumors, reliable information about tumor manifestation in the pelvic and para-aortic lymph nodes impacts treatment planning decisions. The nodal status is not included in the International Federation for Gynecology and Obstetrics (FIGO) staging system; it is nevertheless, one of the most important and valuable, predictive and prognostic factors.^{17,24,25,16}

Several publications assessed the sensitivity and specificity of FDG PET/CT in the evaluation of early and advanced cervical cancer. These studies demonstrated the accuracy of PET/CT versus CT alone for evaluating lymph node status in patients with more advanced disease (\geq IB2), especially when CT findings are normal (Figure 1).^{17,16,26,27,28} In patients with advanced disease, extra pelvic spread, including para-aortic lymph node involvement, is frequent. The results of PET/CT, especially in scenarios with normal CT findings, were shown to lead to substantial changes in treatment planning.²⁹ In another study, PET/CT was more sensitive than MR in detecting nodal involvement for stages IB-IVA³⁰; specificity and accuracy were the same. Based on the results of a prospective study, Loft et al. concluded that whole-body PET/CT for newly-diagnosed cervical cancer in FIGO stage IB or greater outperformed diagnostic CT with IV contrast administration. PET/CT showed higher sensitivity and specificity for staging than CT did, and it is a valuable supplement to the FIGO staging system. The authors also considered PET/CT useful for treatment planning and biopsy guidance, especially when histologic confirmation might be necessary before change of treatment.³¹

*The SUV is a relative measure of FDG uptake.

The sensitivity and specificity of PET/CT to detect lymph node involvement depend on the stage of disease³², and PET/CT cannot replace lymphadenectomy for early stage patients.¹⁷

Detection of Distant Metastases

PET/CT can provide crucial information about distant lymphatic and hematogenous spread of the tumor. It is an effective imaging technique for localizing disease in supraclavicular³³ or mediastinal lymph nodes, as well as in the lung, bone, peritoneum, omentum, adrenal gland and liver.^{29,31,34} The potential impact on therapy management is demonstrated, for example, in Lee et al. For FDG-positive supraclavicular lymph nodes, the authors concluded that for nodes with an SUV_{max} of more than 3.0, further diagnostic procedures to confirm malignancy could be minimized because of the high positive predictive value of 95%.³³

A 46-year-old female patient presented with significant vaginal bleeding. The physical exam revealed a large pedunculated and non-mobile mass, clinically suggesting cervical cancer of at least stage IIA2. The histopathology exam diagnosed an invasive, poorly differentiated carcinoma. The CT scan showed an enlarged uterus with a 7x6 cm cervical lesion. There was no evidence of free fluid or adenopathy.

The patient was referred to undergo a FDG PET/CT scan to exclude distant metastases. The PET/CT showed an intense hypermetabolic, irregular 6.5 cm soft tissue lesion (SUV_{max} of 26.2) that was associated with the cervix (*Figure 1: Sagittal Hot Metal*). In addition, the PET/CT revealed FDG accumulation in the left iliac chain (*Figure 1: Cervical fused Hot Metal*) consistent with left iliac chain metastatic lymph nodes (*Figure 1: Sagittal VRT*). There was no evidence of distant metastatic disease outside the pelvis. The patient was referred for brachytherapy.

Guidelines

NCCN

Workup

For patients with Stage IB1 or higher, the guideline recommends chest radiograph, CT, or combined PET/CT and MR imaging. The expert panel considered imaging as optional for disease smaller than stage IB1.

If surgical “staging” reveals tumor manifestation in the para-aortical lymph nodes, the guidelines recommend chest CT or PET/CT to assess the patient for any distant metastases.⁶

Incidental Finding of Invasive Cervical Cancer

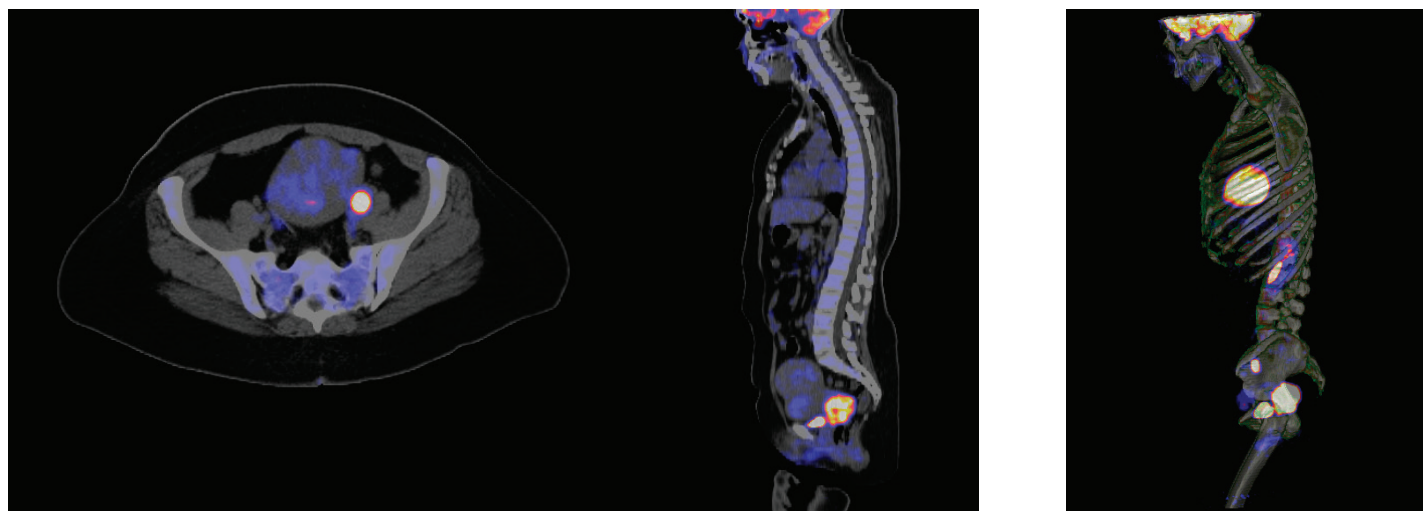
For patients who were diagnosed with invasive cervical cancer after a simple, extrafascial hysterectomy, the recommended imaging workup for stage IIB2 and beyond consists of chest X-ray, CT or PET/CT and potentially MR to rule out gross residual disease.⁶

ESMO

The guidelines of the ESMO discuss the potential benefit of PET/CT in staging and risk assessment in cervical cancer patients. The guideline mentions promising results, demonstrating PET/CT’s ability to accurately delineate the extent of disease, particularly in macroscopically normal lymph nodes and in distant sites; however, there is no direct recommendation as to when to appropriately use it.³⁵

Reimbursement

Except for the initial diagnosis, CMS nationally reimburses FDG PET for Initial Anti-tumor Treatment Strategy for cervical cancer.²¹



Sagittal Hot Metal

Cervical fused Hot Metal

Sagittal VRT

Figure 1: FDG PET/CT of a 46-year-old female patient presented with significant vaginal bleeding.

Data courtesy of University of Tennessee Medical Center, Knoxville, Tennessee, USA

PET/CT in Radiotherapy Planning for Cervical Cancer

Current Status

External Beam Radiation

External beam radiation therapy with simultaneous cisplatin-containing chemotherapy has been the standard therapy for patients with locally advanced cervical cancer. The detection of pathologic FDG uptake in para-aortal lymph nodes may modify the treatment approach, especially in patients who appear to have tumor manifestations limited to the cervix at initial clinical staging. According to Brunetti et al., results of PET/CT can change treatment planning volumes in up to 30% of patients. The more precise definition of metastatic disease may impact the target selection and delineation and allows the escalation of radiation dose to affected lymph nodes, potentially leading to better tumor control probability and improved local response.^{36,37}

Extended field radiotherapy might be needed for patients with involved common iliac or inferior para-aortic nodes but is associated with increased morbidity. A decade ago, researchers first reported that FDG imaging altered management in 18% of the study population—either by extension of the radiation field to include the para-aortic area or by a change in the total administered dose to the involved nodes in the pelvic area.^{38,37} The high positive predictive value of FDG PET/CT in detecting para-aortic and pelvic lymph node involvement can potentially obviate the need for pathological confirmation in order to perform extended-field radiotherapy.*³⁹ Even in patients with para-aortic, inguinal and/or supraclavicular nodal metastases on CT or MR, PET/CT can have an additional significant positive impact on the treatment management.⁴⁰

Within the context of advanced radiotherapy planning, PET/CT supported intensity modulated radiation therapy (IMRT) and showed good tumor coverage by acceptable sparing of healthy tissue.⁴¹ A more recent review publication from 2012 concluded that PET/CT-guided IMRT allows delivery of higher doses of radiation to the primary tumor and to involved nodal disease while minimizing treatment-related toxicity.⁴²

Not only can FDG PET/CT guide target selection and dose distribution for IMRT, but it might also help to limit hematological toxicity by identifying active bone marrow sub-regions and facilitating bone marrow sparing for patients who undergo combined radiochemotherapy.^{43,44}

Brachytherapy

The challenge of brachytherapy is to cover the maximum amount of targeted tumor volume within the prescribed dose without exceeding dose constraints to the critical organs. Most brachytherapy treatment procedures are planned using 2D radiographs; MR and CT have been investigated for 3D treatment planning and more conformal dose distribution to the target volume.^{17,29,37} Studies that investigated the role of PET/CT-guided brachytherapy showed that PET/CT based treatment planning leads to improved dose coverage of the tumor without a significant dose increase to the bladder and rectum.^{45,46}

Guidelines

NCCN

As for external beam radiation therapy, NCCN recommends optimal pre-therapeutic staging of all tumors larger than IB1 to precisely delineate the volume of the primary tumor and its draining lymph nodes. The target selection and delineation of radiation therapy is critical and guided by assessment of nodal involvement in the pelvic and para-aortic nodes, and PET/CT is considered very helpful to determine the nodule volume of coverage for patients who were not staged surgically.⁶

ESMO

The ESMO clinical practice guideline mentions the potential of FDG PET/CT to accurately delineate the disease extent, especially in macroscopically normal areas, but does not include specific recommendations with respect to its role in radiotherapy planning and guidance.³⁵

Reimbursement

CMS nationally reimburses FDG PET for Initial Anti-tumor Treatment Strategy in cervical cancer, with the exception of the use of PET/CT for the initial diagnosis.²¹

*Sampling is still required to exclude small-volume disease cranial to sites of abnormality on PET.³⁹

Treatment Response Monitoring

Depending on the stage of the disease, cervical carcinoma is treated with surgery, radiation therapy and chemotherapy or a combination of these three.¹⁷ Several studies have demonstrated the benefit of FDG PET/CT in assessment of treatment response. A retrospective study from 2004 came to the conclusion that any post-therapy abnormal FDG uptake might be predictive of tumor recurrence and death from cervical cancer.^{47,48} A prospective monocenter trial confirmed that a 3-month post-therapy FDG PET/CT robustly predicted the treatment outcome for cervical cancer and provided immediate information about response to therapy.⁴⁹ Also, the type and degree of metabolic response on post-therapy FDG PET/CT seem to predict different patterns of failure after radiotherapy for cervical cancer.⁵⁰

Approximately 20-40% of patients present persistent or recurrent disease after definitive chemoradiation, and the possibility to identify those patients *before* and *during* treatment would be very beneficial.⁵¹ A pilot study on 25 patients correlated several parameters from FDG PET/CT scans before treatment, as well as two and four weeks into treatment with a three-month, post-treatment PET/CT. In addition to confirming the prognostic value of a pre-treatment scan that will be discussed in detail below, the authors concluded that an FDG PET/CT scan at week four of the treatment provided valuable information for an early response assessment—in particular, the metrics SUV_{max} , metabolic tumor volume and the heterogeneity of the FDG distribution pattern.⁵¹ A further clinical validation of these and other parameters is needed and will, hopefully, confirm those promising data.

Guidelines

NCCN

The current NCCN guidelines underlines that a single PET/CT exam three to six months after chemoradiation for locally advanced cervical cancer can be helpful in identifying early or asymptomatic tumor persistence or recurrence.⁶

ESMO

The guideline indicates that there was no consensus on the best post-therapy surveillance, but recommends the use of a CT or PET/CT scan if clinically indicated.³⁵

Reimbursement

CMS covers FDG PET when used to guide Subsequent Anti-tumor Treatment Strategy (includes Treatment Monitoring, Restaging and Detection of Suspected Recurrence) in patients with cervical cancer.²¹

Long-Term Follow-Up

Current Status

More than two-thirds of recurrences of cervical cancer are estimated to present distant tumor manifestation. Anatomical imaging modalities like CT or MR are not ideal methods to differentiate tumor infiltration from benign processes like reactive hyperplasia, fibrosis or tissue scar and often miss small or normal-sized lymph node metastases.²⁹ Several publications suggest that PET/CT is able to help physicians diagnose loco-regional and disseminated cervical cancer recurrence.^{48,34,52,53} According to Wong et al.³⁴, PET/CT has high diagnostic accuracy (92%) in detecting locally recurrent and distant metastatic disease, has prognostic value for disease outcome and contributes to treatment management changes. Assuming a better overall survival of patients with asymptomatic recurrence⁵⁴, asymptomatic patients would potentially benefit from the ability of PET/CT imaging to detect tumor relapse in patients without any clinical symptoms of recurrent disease.^{55,56}

Guidelines

NCCN

The current guideline acknowledges that a single PET/CT exam three to six months after chemoradiation for locally advanced cervical cancer can be helpful in identifying early or asymptomatic tumor persistence or a relapse. Beyond that, NCCN recommends imaging (including PET and PET/CT) based on symptoms or suspicious results of other tests. Other imaging studies, including subsequent PET/CT, can be used to evaluate, manage and follow up recurrent disease, if clinically justified.⁶

ESMO

While appreciating the potential of PET/CT in staging and risk assessment in cervical cancer patients, the guideline indicates that there was no consensus on the best post-therapy surveillance but recommends the use of a CT or PET/CT scan if clinically indicated.³⁵

Reimbursement

CMS covers FDG PET to guide Subsequent Anti-tumor Treatment Strategy in patients with cervical cancer. As of mid-2013, three FDG PET scans are nationally (United States) covered when used to guide subsequent therapy management after completion of initial anti-tumor therapy. The approval of any additional FDG PET scans beyond those three scans will be determined by local Medicare Administrative Contractors.²¹

FDG PET/CT and Prognosis

Current Status

The quantitative measure SUV_{max} with the addition of the visual assessment of the PET image seems to be a useful tool in predicting treatment response, risk of pelvic recurrence, and disease-free survival and may influence initial treatment planning and surveillance. It also correlated with the presence of lymph node involvement.^{19,57,58} According to a study in 2007, the primary tumor SUV_{max} at the time of the diagnosis was a more significant prognosticator of the patient outcome than the FIGO stage, tumor volume, histology, or lymph node involvement and is an independent predictor for treatment response and prognosis.¹⁹ Others confirmed the correlation between SUV_{max} and the increased risk for recurrence after chemotherapy.¹⁸ Brunetti et al. pointed out that a SUV_{max} higher than 10 in the primary tumor and the pelvic nodes, as well as FDG accumulation in the para-aortic lymph nodes, are associated with poorer outcome. The SUV of the pelvic nodes is an independent factor to predict post-treatment disease persistence³⁶ and, potentially, recurrence and survival.⁵⁹

The qualitative assessment of the lymph node status determined with FDG imaging was the most significant independent pre-treatment predictor of progression-free survival and overall survival of patients with cervical cancer.^{25,24} While other assessments concluded that the total lesion glycolysis (TLG) and lymph node status on a PET/CT might be significant and/or independent prognostic factors for event-free survival.⁶⁰ For patients with recurrent cancer, the FDG uptake in the tumor allowed the outcome of radiation to be predicted.⁶¹

As for the combined use of several prognostic factors, Kidd et al. concluded that the combination of pre-treatment FDG PET/CT derived lymph node status, cervical tumor SUV_{max} , and tumor volume create good models for predicting cervical cancer recurrence-free survival, disease-specific survival and overall survival.⁶²

Guidelines

NCCN

The NCCN clinical practice guidelines do not discuss the use of PET/CT for prognostic purposes only; however, they mention its role in guiding treatment.^{6*}

ESMO

The ESMO guidelines appreciate the potential benefit of PET/CT in risk assessment for patients with the cervical cancer.³⁵

Reimbursement

CMS nationally covers FDG PET in solid tumors for Initial Anti-tumor Treatment strategy for cervical cancer, except for using PET for initial diagnosis of cervical cancer related to initial anti-tumor treatment. There is no specific information with respect to prognostication.²¹

The Impact of Technological Advances—Outlook

The diagnostic information of an FDG PET/CT scan can have an impact on therapy management and follow-up for patients with cervical cancer. Improvement in image resolution, as well as quantification as it is provided in the newest generation PET/CT scanner, may potentially widen the clinical role of PET/CT for those patients, for example, in the delineation extent of the primary tumor or in the detection of small lymph node metastases.⁶³ Also, recently introduced PET/MR systems show new insights into the combination of metabolic and soft tissue information, which might be beneficial for assessing the tumor extent in radiotherapy planning and for evaluating the presence of recurrent disease.

As for reimbursement, CMS clarified that integrated FDG PET/CT and integrated FDG PET/MRI are included in the term FDG PET, but that this decision did not imply any reconsideration determining any change in coverage either for CT or for MRI imaging.²¹

Lastly, promising new radiopharmaceuticals to better address cellular or micro environmental changes—such as hypoxia—in the tumor might be able to identify more malignant phenotypes and to modify the radiotherapy dose distribution accordingly.

*These current NCCN guidelines discuss squamous cell carcinoma, adenosquamous carcinoma, and adenocarcinoma of the cervix. Neuroendocrine carcinoma, small cell tumors, glassy-cell carcinomas, sarcomas, and malignancies with other histology are not incorporated.⁶

References

- 1 **WHO.** (2014, Feb). *WHO Fact Sheet #297: Cancer*. Retrieved Jan 10, 2014, from <http://www.who.int/mediacentre/factsheets/fs297/en/index.html>
- 2 **IARC.** (2014). *Globocan 2012: Estimated Cancer Incidence, Mortality and Prevalence Worldwide in 2012*. Retrieved Jan 23, 2014, from http://globocan.iarc.fr/Pages/fact_sheets_cancer.aspx
- 3 **NCI.** (2013). *Cervical Cancer*. Retrieved Jan 22, 2014, from <http://www.cancer.gov/cancertopics/types/cervical>
- 4 **Walboomers, J. e.** (1999). Human papillomavirus is a necessary cause of invasive cervical cancer worldwide. *J Pathol*, 189, 12-19
- 5 **AJCC.** (2010). *Cancer Staging Manual, 7th edition*. Chicago: Springer
- 6 **NCCN.** (2013, Jul 16). *NCCN Clinical Practice Guidelines in Oncology Cervical Cancer Version 3.2013*. Retrieved Jan 24, 2014, from http://www.nccn.org/professionals/physician_gls/pdf/cervical.pdf
- 7 **Amit, A. e.** (2011). PET/CT in Gynecologic Cancer: Present Applications and Future Prospects—A Clinician's Perspective. *Obstet Gynecol Clin N Am*, 28, 1-21
- 8 **Gambhir, S. e.** (2001). A Tabulated Summary of the FDG PET Literature. *JNM*, 42, 1S-92S
- 9 **Czernin, J. e.** (2007). Improvements in Cancer Staging with PET/CT: Literature-Based Evidence as of September 2006. *JNM*, 48, 78S-88S
- 10 **Forrest, W.** (2009). PET scores big win with CMS coverage for 11 cancers. *PET/CT NEWSLETTER(2)*
- 11 **Hillner, B. a.** (2008). Impact of Positron Emission Tomography/Computed Tomography and Positron Emission Tomography (PET) Alone on Expected Management of Patients With Cancer: Initial Results From the National Oncologic PET Registry Bruce E. Hillner, Barry A. Siegel, Dawei Liu, Anthony F. Shields, Ilana F. Gareen, Lucy Hanna, Sharon Hartson Stine, and R. Edward Coleman. *JCO*, 26, 2155-2161
- 12 **Hillner, B. e.** (2009). The Impact of Positron Emission Tomography (PET) on Expected Management During Cancer Treatment. *Cancer*, 115, 410-8
- 13 **Follen, M. e.** (2003). Imaging in cervical cancer. *Cancer*, 98(9S), 2028-38
- 14 **Lerman, H. e.** (2004). Normal and Abnormal 18 F-FDG Endometrial and Ovarian Uptake in Pre- and Postmenopausal Patients: Assessment by PET/CT. *J Nucl Med*, 45, 266-271
- 15 **Son, H. e.** (2010). PET/CT Evaluation of Cervical Cancer: Spectrum of Disease. *RadioGraphics*, 30, 1251-1268
- 16 **Patel, C. e.** (2011). 18F-FDG PET/CT of Cervical Carcinoma. *AJR*, 196, 1225-1233
- 17 **Mirpour, S. e.** (2013). The Role of PET/CT in the Management of Cervical Cancer. *AJR*, 201, W192-W205
- 18 **Lee, Y. e.** (2009). The prognostic significance of the SUV_{max} (maximum standardized uptake value for F-18 fluorodeoxyglucose) of the cervical tumor in PET imaging for early cervical cancer: preliminary results. *Gynecol Oncol*, 115, 65-8
- 19 **Kidd, E. e.** (2007). The standardized uptake value for F-18 fluorodeoxyglucose is a sensitive predictive biomarker for cervical cancer treatment response and survival. *Cancer*, 110(8), 1738-1744
- 20 **Kidd, E. e.** (2009). Cervical Cancer Histology and Tumor Differentiation Affect 18 F Fluorodeoxyglucose Uptake. *Cancer*, 115, 3548-54
- 21 **CMS.** (2013, June 11). Decision Memo for Positron Emission Tomography (FDG) for Solid Tumors (CAG-00181R4)
- 22 **Showalter, T. e.** (2009). 18F-fluorodeoxyglucose-positron emission tomography and pathologic tumor size in early-stage invasive cervical cancer. *Int J Gynecol Cancer.*, 19, 1412-4
- 23 **Grigsby, P.** (2007). The contribution of new imaging techniques in staging cervical cancer. *Gynecol Oncol*, 107(S1), S10-2
- 24 **Grigsby, P. e.** (2001). Lymph Node Staging by Positron Emission Tomography in Patients With Carcinoma of the Cervix. *JCO*, 19, 3745-3749
- 25 **Grigsby, P. e.** (2008). The prognostic value of PET and PET/CT in cervical cancer. *Cancer Imaging*, 8, 146-155
- 26 **Sironi, S. e.** (2006). Lymph Node Metastasis in Patients with Clinical Early-Stage Cervical Cancer: Detection with Integrated FDG PET/CT. *Radiology*, 238, 272-279
- 27 **Singh, A. e.** (2003). FDG-PET lymph node staging and survival of patients with FIGO stage IIIb cervical carcinoma. *Int J Radiat Oncol Biol Phys*, 56, 489-493
- 28 **Yildirim, Y.** (2008). Integrated PET/CT for the evaluation of para-aortic nodal metastasis in locally advanced cervical cancer patients with negative conventional CT findings. *Gynecol Oncol*. 2008 Jan;108(1):154-9, 108, 154-9

-
- 29 **Magné, N. e.** (2008). New trends in the evaluation and treatment of cervix cancer: The role of FDG–PET. *Cancer Treat Rev*, 34, 671–681
- 30 **Choi, H. e.** (2006). Comparison of the Accuracy of Magnetic Resonance Imaging and Positron Emission Tomography/Computed Tomography in the Presurgical Detection of Lymph Node Metastases in Patients with Uterine Cervical Carcinoma. *Cancer*, 106, 914–22
- 31 **Loft, A. e.** (2007). The diagnostic value of PET/CT scanning in patients with cervical cancer: a prospective study. *Gynecol Oncol*, 106, 29-34
- 32 **Wright, D. e.** (2005). Preoperative Lymph Node Staging of Early-Stage Cervical Carcinoma by [¹⁸F]-Fluoro-2-Deoxy-D-Glucose–Positron Emission Tomography. *Cancer*, 104, 2484-91
- 33 **Lee, J. e.** (2012). Supraclavicular Lymph Nodes Detected by ¹⁸F-FDG PET/CT in Cancer Patients: Assessment With ¹⁸F-FDG PET/CT and Sonograph. *AJR*, 187–193
- 34 **Wong, T. e.** (2004). Positron emission tomography with 2-deoxy-2-[(¹⁸F)]fluoro-Dglucose for evaluating local and distant disease in patients with cervical cancer. *Mol Imaging Biol*, 55-62
- 35 **Colombo, N. e.** (2012). Cervical cancer: ESMO Clinical Practice Guidelines for diagnosis, treatment and follow-up. *Annals of Oncology*, 23(Sup7), vii27–vii32
- 36 **Brunetti, J. e.** (2013). PET/CT in Gynecologic Malignancies. *Radiol Clin N Am*, 895–911
- 37 **Herrera, F. e.** (2013, Feb 26). The role of PET/CT in cervical cancer. *Front. Oncol*
- 38 **Belhocine, T. e.** (2002). Contribution of whole-body ¹⁸FDG PET imaging in the management of cervical cancer. *Gynecol Oncol.*, 87, 90-7
- 39 **Narayan, K. e.** (2001). A comparison of MRI and PET scanning in surgically staged locoregionally advanced cervical cancer: potential impact on treatment. *Int J Gynecol Cancer*, 11, 263-71
- 40 **Chao, A. e.** (2008). doi: 10.1016/j.ygyno.2008.03.018. Epub 2008 May 22. Positron emission tomography in evaluating the feasibility of curative intent in cervical cancer patients with limited distant lymph node metastases. *Gynecol Oncol.*, 110, 172-8
- 41 **Esthappan, J. e.** (2004). Treatment planning guidelines regarding the use of CT/PETguided IMRT for cervical carcinoma with positive paraaortic lymph nodes. *Int J Radiat Oncol Biol Phys.*, 1289-97
- 42 **Salem, A. e.** (2011). Evidence for the use PET for radiation therapy planning in patients with cervical cancer: a systematic review. *Hematol Oncol Stem Cell Ther.*, 4, 173-81
- 43 **Rose, B. e.** (2012). Correlation between radiation dose to ¹⁸F-FDG-PET defined active bone marrow subregions and acute hematologic toxicity in cervical cancer patients treated with chemoradiotherapy. *Int J Radiat Oncol Biol Phys.*, 1185-91
- 44 **Liang, Y. e.** (2013). Prospective study of functional bone marrow-sparing intensity modulated radiation therapy with concurrent chemotherapy for pelvic malignancies. *Int J Radiat Oncol Biol Phys.*, 406-14
- 45 **Lin, L. e.** (2007). Adaptive brachytherapy treatment planning for cervical cancer using FDG-PET. *Int J Radiat Oncol Biol Phys*, 67, 91-6
- 46 **Nam, H. e.** (2012). ¹⁸F-fluorodeoxyglucose positron emission tomography/computed tomography guided conformal brachytherapy for cervical cancer. *Int J Radiat Oncol Biol Phys.*, 84, e29-34
- 47 **Grigsby, P. e.** (2004). Posttherapy [¹⁸F] fluorodeoxyglucose positron emission tomography in carcinoma of the cervix: response and outcome. *J Clin Oncol*, 22, 2167–2171
- 48 **Havrilesky, L. e.** (2003). The role of PET scanning in the detection of recurrent cervical cancer. *Gynecol Oncol*, 90, 186-90
- 49 **Schwarz, J. e.** (2007). Association of Posttherapy Positron Emission Tomography With Tumor Response and Survival in Cervical Carcinoma. *JAMA*, 298, 2289-2295
- 50 **Schwarz, J. e.** (2012), Metabolic response on post-therapy FDG-PET predicts patterns of failure after radiotherapy for cervical cancer. *Int J Radiat Oncol Biol Phys*, 83, 185-90
- 51 **Kidd, E. e.** (2013). Changes in Cervical Cancer FDG Uptake During Chemoradiation and Association with Response. *Int J Radiat Oncol Biol Phys*, 85, 116–12
- 52 **Sakurai, H. e.** (2006). FDG-PET in the detection of recurrence of uterine cervical carcinoma following radiation therapy—tumor volume and FDG uptake value. *Gynecol Oncol*, 100, 601-7
- 53 **Mittra, E. e.** (2009). Efficacy of ¹⁸F-FDG PET/CT in the evaluation of patients with recurrent cervical carcinoma. *Eur J Nucl Med Mol Imaging*, 1952-9
- 54 **Bodurka-Bevers, D. e.** (2000). Post-therapy surveillance of women with cervical cancer: an outcomes analysis. *Gynecol Oncol*, 78, 187-93

-
- 55 **Brooks, R. e.** (2009). Surveillance FDG-PET detection of asymptomatic recurrences in patients with cervical cancer. *Gynecol Oncol.*, 112, 104-9
- 56 **Chung, H. e.** (2006). Clinical impact of FDG-PET imaging in post-therapy surveillance of uterine cervical cancer: from diagnosis to prognosis. *Gynecol Oncol.*, 103, 165-70
- 57 **Kidd, E. e.** (2010). Pelvic Lymph Node F-18 Fluorodeoxyglucose Uptake as a Prognostic Biomarker in Newly Diagnosed Patients With Locally Advanced Cervical Cancer. *Cancer*, 1469–75
- 58 **Yilmaz, M. e.** (2010). FDG PET-CT in cervical cancer: relationship between primary tumor FDG uptake and metastatic potential. *Nucl Med Commun*, 31, :526-31
- 59 **Nakamura, K.** (2014). Maximum standardized lymph node uptake value could be an important predictor of recurrence and survival in patients with cervical cancer. *Eur J Obstet Gynecol Reprod Biol*, 173, 77-82
- 60 **Yoo, J. e.** (2012). Prognostic significance of volume-based metabolic parameters in uterine cervical cancer determined using ¹⁸F-fluorodeoxyglucose positron emission tomography. *Int J Gynecol Cancer*, 1226-33
- 61 **Sharma, D. e.** (2012). Positron emission tomography scan for predicting clinical outcome of patients with recurrent cervical carcinoma following radiation therapy. *J Cancer Res Ther.*, 8, 23-7
- 62 **Kidd, E. e.** (2012). FDG-PET-based prognostic nomograms for locally advanced cervical cancer. *Gynecol Oncol.*, 127, 136-40
- 63 **Siemens.** (2013, 9). Biograph mCT Flow FlowMotion, the end of stop and go

HIGHLIGHTS OF PRESCRIBING INFORMATION

These highlights do not include all the information needed to use Fludeoxyglucose F 18 Injection safely and effectively. See full prescribing information for Fludeoxyglucose F 18 Injection.

Fludeoxyglucose F 18 Injection, USP
For intravenous use
Initial U.S. Approval: 2005

RECENT MAJOR CHANGES

Warnings and Precautions (5.1, 5.2)	7/2010
Adverse Reactions (6)	7/2010

INDICATIONS AND USAGE

Fludeoxyglucose F 18 Injection is indicated for positron emission tomography (PET) imaging in the following settings:

- **Oncology:** For assessment of abnormal glucose metabolism to assist in the evaluation of malignancy in patients with known or suspected abnormalities found by other testing modalities, or in patients with an existing diagnosis of cancer.
- **Cardiology:** For the identification of left ventricular myocardium with residual glucose metabolism and reversible loss of systolic function in patients with coronary artery disease and left ventricular dysfunction, when used together with myocardial perfusion imaging.
- **Neurology:** For the identification of regions of abnormal glucose metabolism associated with foci of epileptic seizures (1).

DOSAGE AND ADMINISTRATION

Fludeoxyglucose F 18 Injection emits radiation. Use procedures to minimize radiation exposure. Screen for blood glucose abnormalities.

- In the oncology and neurology settings, instruct patients to fast for 4 to 6 hours prior to the drug's injection. Consider medical therapy and laboratory testing to assure at least two days of normoglycemia prior to the drug's administration (5.2).
- In the cardiology setting, administration of glucose-containing food or liquids (e.g., 50 to 75 grams) prior to the drug's injection facilitates localization of cardiac ischemia (2.3).

Aseptically withdraw Fludeoxyglucose F 18 Injection from its container and administer by intravenous injection (2).

The recommended dose:

- for adults is 5 to 10 mCi (185 to 370 MBq), in all indicated clinical settings (2.1).
 - for pediatric patients is 2.6 mCi in the neurology setting (2.2).
- Initiate imaging within 40 minutes following drug injection; acquire static emission images 30 to 100 minutes from time of injection (2).

DOSAGE FORMS AND STRENGTHS

Multi-dose 30mL and 50mL glass vial containing 0.74 to 7.40 GBq/mL (20 to 200 mCi/mL) Fludeoxyglucose F 18 Injection and 4.5mg of sodium chloride with 0.1 to 0.5% w/w ethanol as a stabilizer (approximately 15 to 50 mL volume) for intravenous administration (3).

CONTRAINDICATIONS

None

WARNINGS AND PRECAUTIONS

- **Radiation risks:** use smallest dose necessary for imaging (5.1).
- **Blood glucose abnormalities:** may cause suboptimal imaging (5.2).

ADVERSE REACTIONS

Hypersensitivity reactions have occurred; have emergency resuscitation equipment and personnel immediately available (6).

To report SUSPECTED ADVERSE REACTIONS, contact PETNET Solutions, Inc. at 877-473-8638 or FDA at 1-800-FDA-1088 or www.fda.gov/medwatch.

USE IN SPECIFIC POPULATIONS

- **Pregnancy Category C:** No human or animal data. Consider alternative diagnostics; use only if clearly needed (8.1).
- **Nursing mothers:** Use alternatives to breast feeding (e.g., stored breast milk or infant formula) for at least 10 half-lives of radioactive decay, if Fludeoxyglucose F 18 Injection is administered to a woman who is breast-feeding (8.3).
- **Pediatric Use:** Safety and effectiveness in pediatric patients have not been established in the oncology and cardiology settings (8.4).

See 17 for PATIENT COUNSELING INFORMATION

Revised: 1/2011

FULL PRESCRIBING INFORMATION: CONTENTS*

1 INDICATIONS AND USAGE

- 1.1 Oncology
- 1.2 Cardiology
- 1.3 Neurology

2 DOSAGE AND ADMINISTRATION

- 2.1 Recommended Dose for Adults
- 2.2 Recommended Dose for Pediatric Patients
- 2.3 Patient Preparation
- 2.4 Radiation Dosimetry
- 2.5 Radiation Safety – Drug Handling
- 2.6 Drug Preparation and Administration
- 2.7 Imaging Guidelines

3 DOSAGE FORMS AND STRENGTHS

4 CONTRAINDICATIONS

5 WARNINGS AND PRECAUTIONS

- 5.1 Radiation Risks
- 5.2 Blood Glucose Abnormalities

6 ADVERSE REACTIONS

7 DRUG INTERACTIONS

8 USE IN SPECIFIC POPULATIONS

- 8.1 Pregnancy
- 8.3 Nursing Mothers
- 8.4 Pediatric Use

11 DESCRIPTION

- 11.1 Chemical Characteristics
- 11.2 Physical Characteristics

12 CLINICAL PHARMACOLOGY

- 12.1 Mechanism of Action
- 12.2 Pharmacodynamics
- 12.3 Pharmacokinetics

13 NONCLINICAL TOXICOLOGY

- 13.1 Carcinogenesis, Mutagenesis, Impairment of Fertility

14 CLINICAL STUDIES

- 14.1 Oncology
- 14.2 Cardiology
- 14.3 Neurology

15 REFERENCES

16 HOW SUPPLIED/STORAGE AND DRUG HANDLING

17 PATIENT COUNSELING INFORMATION

* Sections or subsections omitted from the full prescribing information are not listed.

FULL PRESCRIBING INFORMATION

1 INDICATIONS AND USAGE

Fludeoxyglucose F 18 Injection is indicated for positron emission tomography (PET) imaging in the following settings:

1.1 Oncology

For assessment of abnormal glucose metabolism to assist in the evaluation of malignancy in patients with known or suspected abnormalities found by other testing modalities, or in patients with an existing diagnosis of cancer.

1.2 Cardiology

For the identification of left ventricular myocardium with residual glucose metabolism and reversible loss of systolic function in patients with coronary artery disease and left ventricular dysfunction, when used together with myocardial perfusion imaging.

1.3 Neurology

For the identification of regions of abnormal glucose metabolism associated with foci of epileptic seizures.

2 DOSAGE AND ADMINISTRATION

Fludeoxyglucose F 18 Injection emits radiation. Use procedures to minimize radiation exposure. Calculate the final dose from the end of synthesis (EOS) time using proper radioactive decay factors. Assay the final dose in a properly calibrated dose calibrator before administration to the patient [see Description (11.2)].

2.1 Recommended Dose for Adults

Within the oncology, cardiology and neurology settings, the recommended dose for adults is 5 to 10 mCi (185 to 370 MBq) as an intravenous injection.

2.2 Recommended Dose for Pediatric Patients

Within the neurology setting, the recommended dose for pediatric patients is 2.6 mCi, as an intravenous injection. The optimal dose adjustment on the basis of body size or weight has not been determined [see Use in Special Populations (8.4)].

2.3 Patient Preparation

- To minimize the radiation absorbed dose to the bladder, encourage adequate hydration. Encourage the patient to drink water or other fluids (as tolerated) in the 4 hours before their PET study.
- Encourage the patient to void as soon as the imaging study is completed and as often as possible thereafter for at least one hour.
- Screen patients for clinically significant blood glucose abnormalities by obtaining a history and/or laboratory tests [see Warnings and Precautions (5.2)]. Prior to Fludeoxyglucose F 18 PET imaging in the oncology and neurology settings, instruct patient to fast for 4 to 6 hours prior to the drug's injection.
- In the cardiology setting, administration of glucose-containing food or liquids (e.g., 50 to 75 grams) prior to Fludeoxyglucose F 18 Injection facilitates localization of cardiac ischemia

2.4 Radiation Dosimetry

The estimated human absorbed radiation doses (rem/mCi) to a newborn (3.4 kg), 1-year old (9.8 kg), 5-year old (19 kg), 10-year old (32 kg), 15-year old (57 kg), and adult (70 kg) from intravenous administration of Fludeoxyglucose F 18 Injection are shown in Table 1. These estimates were calculated based on human² data and using the data published by the International Commission on Radiological Protection⁴ for Fludeoxyglucose ¹⁸F. The dosimetry data show that there

are slight variations in absorbed radiation dose for various organs in each of the age groups. These dissimilarities in absorbed radiation dose are due to developmental age variations (e.g., organ size, location, and overall metabolic rate for each age group). The identified critical organs (in descending order) across all age groups evaluated are the urinary bladder, heart, pancreas, spleen, and lungs.

Table 1. Estimated Absorbed Radiation Doses (rem/mCi) After Intravenous Administration of Fludeoxyglucose F 18 Injection^a

Organ	Newborn (3.4 kg)	1-year old (9.8 kg)	5-year old (19 kg)	10-year old (32 kg)	15-year old (57 kg)	Adult (70 kg)
Bladder wall ^b	4.3	1.7	0.93	0.60	0.40	0.32
Heart wall	2.4	1.2	0.70	0.44	0.29	0.22
Pancreas	2.2	0.68	0.33	0.25	0.13	0.096
Spleen	2.2	0.84	0.46	0.29	0.19	0.14
Lungs	0.96	0.38	0.20	0.13	0.092	0.064
Kidneys	0.81	0.34	0.19	0.13	0.089	0.074
Ovaries	0.80	0.8	0.19	0.11	0.058	0.053
Uterus	0.79	0.35	0.19	0.12	0.076	0.062
LLI wall*	0.69	0.28	0.15	0.097	0.060	0.051
Liver	0.69	0.31	0.17	0.11	0.076	0.058
Gallbladder wall	0.69	0.26	0.14	0.093	0.059	0.049
Small intestine	0.68	0.29	0.15	0.096	0.060	0.047
ULI wall**	0.67	0.27	0.15	0.090	0.057	0.046
Stomach wall	0.65	0.27	0.14	0.089	0.057	0.047
Adrenals	0.65	0.28	0.15	0.095	0.061	0.048
Testes	0.64	0.27	0.14	0.085	0.052	0.041
Red marrow	0.62	0.26	0.14	0.089	0.057	0.047
Thymus	0.61	0.26	0.14	0.086	0.056	0.044
Thyroid	0.61	0.26	0.13	0.080	0.049	0.039
Muscle	0.58	0.25	0.13	0.078	0.049	0.039
Bone surface	0.57	0.24	0.12	0.079	0.052	0.041
Breast	0.54	0.22	0.11	0.068	0.043	0.034
Skin	0.49	0.20	0.10	0.060	0.037	0.030
Brain	0.29	0.13	0.09	0.078	0.072	0.070
Other tissues	0.59	0.25	0.13	0.083	0.052	0.042

^a MIRDSE 2 software was used to calculate the radiation absorbed dose. Assumptions on the biodistribution based on data from Gallagher et al.¹ and Jones et al.²

^b The dynamic bladder model with a uniform voiding frequency of 1.5 hours was used. *LLI = lower large intestine; **ULI = upper large intestine

2.5 Radiation Safety – Drug Handling

- Use waterproof gloves, effective radiation shielding, and appropriate safety measures when handling Fludeoxyglucose F 18 Injection to avoid unnecessary radiation exposure to the patient, occupational workers, clinical personnel and other persons.
- Radiopharmaceuticals should be used by or under the control of physicians who are qualified by specific training and experience in the safe use and handling of radionuclides, and whose experience and training have been approved by the appropriate governmental agency authorized to license the use of radionuclides.
- Calculate the final dose from the end of synthesis (EOS) time using proper radioactive decay factors. Assay the final dose in a properly calibrated dose calibrator before administration to the patient [see Description (11.2)].
- The dose of Fludeoxyglucose F 18 used in a given patient should be minimized consistent with the objectives of the procedure, and the nature of the radiation detection devices employed.

2.6 Drug Preparation and Administration

- Calculate the necessary volume to administer based on calibration time and dose.
- Aseptically withdraw Fludeoxyglucose F 18 Injection from its container.
- Inspect Fludeoxyglucose F 18 Injection visually for particulate matter and discoloration before administration, whenever solution and container permit.
- Do not administer the drug if it contains particulate matter or discoloration; dispose of these unacceptable or unused preparations in a safe manner, in compliance with applicable regulations.
- Use Fludeoxyglucose F 18 Injection within 12 hours from the EOS.

2.7 Imaging Guidelines

- Initiate imaging within 40 minutes following Fludeoxyglucose F 18 Injection administration.
- Acquire static emission images 30 to 100 minutes from the time of injection.

3 DOSAGE FORMS AND STRENGTHS

Multiple-dose 30mL and 50mL glass vial containing 0.74 to 7.40 GBq/mL (20 to 200 mCi/mL) of Fludeoxyglucose F 18 Injection and 4.5 mg of sodium chloride with 0.1 to 0.5% w/w ethanol as a stabilizer (approximately 15 to 50 mL volume) for intravenous administration.

4 CONTRAINDICATIONS

None

5 WARNINGS AND PRECAUTIONS

5.1 Radiation Risks

Radiation-emitting products, including Fludeoxyglucose F 18 Injection, may increase the risk for cancer, especially in pediatric patients. Use the smallest dose necessary for imaging and ensure safe handling to protect the patient and health care worker [see Dosage and Administration (2.5)].

5.2 Blood Glucose Abnormalities

In the oncology and neurology setting, suboptimal imaging may occur in patients with inadequately regulated blood glucose levels. In these patients, consider medical therapy and laboratory testing to assure at least two days of normoglycemia prior to Fludeoxyglucose F 18 Injection administration.

6 ADVERSE REACTIONS

Hypersensitivity reactions with pruritus, edema and rash have been reported in the post-marketing setting. Have emergency resuscitation equipment and personnel immediately available.

7 DRUG INTERACTIONS

The possibility of interactions of Fludeoxyglucose F 18 Injection with other drugs taken by patients undergoing PET imaging has not been studied.

8 USE IN SPECIFIC POPULATIONS

8.1 Pregnancy

Pregnancy Category C

Animal reproduction studies have not been conducted with Fludeoxyglucose F 18 Injection. It is also not known whether Fludeoxyglucose F 18 Injection can cause fetal harm when administered to a pregnant woman or can affect reproduction capacity. Consider alternative diagnostic tests in a pregnant woman; administer Fludeoxyglucose F 18 Injection only if clearly needed.

8.3 Nursing Mothers

It is not known whether Fludeoxyglucose F 18 Injection is excreted in human milk. Consider alternative diagnostic tests in women who are breast-feeding. Use alternatives to breast feeding (e.g., stored breast milk or infant formula) for at least 10 half-lives of radioactive decay, if Fludeoxyglucose F 18 Injection is administered to a woman who is breast-feeding.

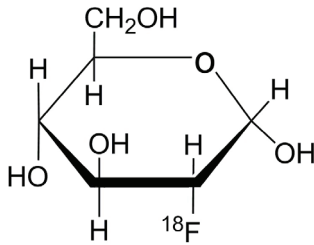
8.4 Pediatric Use

The safety and effectiveness of Fludeoxyglucose F 18 Injection in pediatric patients with epilepsy is established on the basis of studies in adult and pediatric patients. In pediatric patients with epilepsy, the recommended dose is 2.6 mCi. The optimal dose adjustment on the basis of body size or weight has not been determined. In the oncology or cardiology settings, the safety and effectiveness of Fludeoxyglucose F 18 Injection have not been established in pediatric patients.

11 DESCRIPTION

11.1 Chemical Characteristics

Fludeoxyglucose F 18 Injection is a positron emitting radiopharmaceutical that is used for diagnostic purposes in conjunction with positron emission tomography (PET) imaging. The active ingredient 2-deoxy-2-[¹⁸F]fluoro-D-glucose has the molecular formula of C₆H₁₁18FO₅ with a molecular weight of 181.26, and has the following chemical structure:



Fludeoxyglucose F 18 Injection is provided as a ready to use sterile, pyrogen free, clear, colorless solution. Each mL contains between 0.740 to 7.40GBq (20.0 to 200 mCi) of 2-deoxy-2-[¹⁸F]fluoro-D-glucose at the EOS, 4.5 mg of sodium chloride and 0.1 to 0.5% w/w ethanol as a stabilizer. The pH of the solution is between 4.5 and 7.5. The solution is packaged in a multiple-dose glass vial and does not contain any preservative.

11.2 Physical Characteristics

Fluorine F 18 decays by emitting positron to Oxygen O 16 (stable) and has a physical half-life of 109.7 minutes. The principal photons useful for imaging are the dual 511 keV gamma photons, that are produced and emitted simultaneously in opposite direction when the positron interacts with an electron (Table 2).

Radiation/Emission	% Per Disintegration	Mean Energy
Positron(β^+)	96.73	249.8 keV
Gamma(\pm)*	193.46	511.0 keV

*Produced by positron annihilation
From: Kocher, D.C. Radioactive Decay Tables DOE/TIC-1 1026, 89 (1981)

The specific gamma ray constant (point source air kerma coefficient) for fluorine F 18 is 5.7 R/hr/mCi (1.35×10^{-6} Gy/hr/kBq) at 1 cm. The half-value layer (HVL) for the 511 keV photons is 4 mm lead (Pb). The range of attenuation coefficients for this radionuclide as a function of lead shield thickness is shown in Table 3. For example, the interposition of an 8 mm thickness of Pb, with a coefficient of attenuation of 0.25, will decrease the external radiation by 75 percent.

Table 3. Radiation Attenuation of 511 keV Photons by lead (Pb) shielding

Shield thickness (Pb) mm	Coefficient of attenuation
0	0.00
4	0.50
8	0.25
13	0.10
26	0.01
39	0.001
52	0.0001

For use in correcting for physical decay of this radionuclide, the fractions remaining at selected intervals after calibration are shown in Table 4.

Table 4. Physical Decay Chart for Fluorine F 18

Minutes	Fraction Remaining
0*	1.000
15	0.909
30	0.826
60	0.683
110	0.500
220	0.250

*calibration time

12 CLINICAL PHARMACOLOGY

12.1 Mechanism of Action

Fludeoxyglucose F 18 is a glucose analog that concentrates in cells that rely upon glucose as an energy source, or in cells whose dependence on glucose increases under pathophysiological conditions. Fludeoxyglucose F 18 is transported through the cell membrane by facilitative glucose transporter proteins and is phosphorylated within the cell to [¹⁸F] FDG-6-phosphate by the enzyme hexokinase. Once phosphorylated it cannot exit until it is dephosphorylated by glucose-6-phosphatase. Therefore, within a given tissue or pathophysiological process, the retention and clearance of Fludeoxyglucose F 18 reflect a balance involving glucose transporter, hexokinase and glucose-6-phosphatase activities. When allowance is made for the kinetic differences between glucose and Fludeoxyglucose F 18 transport and phosphorylation (expressed as the "lumped constant" ratio), Fludeoxyglucose F 18 is used to assess glucose metabolism.

In comparison to background activity of the specific organ or tissue type, regions of decreased or absent uptake of Fludeoxyglucose F 18 reflect the decrease or absence of glucose metabolism. Regions of increased uptake of Fludeoxyglucose F 18 reflect greater than normal rates of glucose metabolism.

12.2 Pharmacodynamics

Fludeoxyglucose F 18 Injection is rapidly distributed to all organs of the body after intravenous administration. After background clearance of Fludeoxyglucose F 18 Injection, optimal PET imaging is generally achieved between 30 to 40 minutes after administration.

In cancer, the cells are generally characterized by enhanced glucose metabolism partially due to (1) an increase in activity of glucose transporters, (2) an increased rate of phosphorylation activity, (3) a reduction of phosphatase activity or, (4) a dynamic alteration in the balance among all these processes. However, glucose metabolism of cancer as reflected by Fludeoxyglucose F 18 accumulation shows considerable variability. Depending on tumor type, stage, and location, Fludeoxyglucose F 18 accumulation may be increased, normal, or decreased. Also, inflammatory cells can have the same variability of uptake of Fludeoxyglucose F 18.

In the heart, under normal aerobic conditions, the myocardium meets the bulk of its energy requirements by oxidizing free fatty acids. Most of the exogenous glucose taken up by the myocyte is converted into glycogen. However, under ischemic conditions, the oxidation of free fatty acids decreases, exogenous glucose becomes the preferred myocardial substrate, glycolysis is stimulated, and glucose taken up by the myocyte is metabolized immediately instead of being converted into glycogen. Under these conditions, phosphorylated Fludeoxyglucose F 18 accumulates in the myocyte and can be detected with PET imaging.

In the brain, cells normally rely on aerobic metabolism. In epilepsy, the glucose metabolism varies. Generally, during a seizure, glucose metabolism increases. Interictally, the seizure focus tends to be hypometabolic.

12.3 Pharmacokinetics

Distribution: In four healthy male volunteers, receiving an intravenous administration of 30 seconds in duration, the arterial blood level profile for Fludeoxyglucose F 18 decayed triexponentially. The effective half-life ranges of the three phases were 0.2 to 0.3 minutes, 10 to 13 minutes with a mean and standard deviation (STD) of 11.6 (\pm) 1.1 min, and 80 to 95 minutes with a mean and STD of 88 (\pm) 4 min.

Plasma protein binding of Fludeoxyglucose F 18 has not been studied.

Metabolism: Fludeoxyglucose F 18 is transported into cells and phosphorylated to [18 F]FDG-6-phosphate at a rate proportional to the rate of glucose utilization within that tissue. [18 F]-FDG-6-phosphate presumably is metabolized to 2-deoxy-2-[18 F]fluoro-6-phospho-D-mannose([18]FDM-6-phosphate).

Fludeoxyglucose F 18 Injection may contain several impurities (e.g., 2-deoxy-2-chloro-D-glucose (CIDG)). Biodistribution and metabolism of CIDG are presumed to be similar

to Fludeoxyglucose F 18 and would be expected to result in intracellular formation of 2-deoxy-2-chloro-6-phospho-D-glucose (CIDG-6-phosphate) and 2-deoxy-2-chloro-6-phospho-D-mannose (CIDM-6-phosphate). The phosphorylated deoxyglucose compounds are dephosphorylated and the resulting compounds (FDG, FDM, CIDG, and CIDM) presumably leave cells by passive diffusion. Fludeoxyglucose F 18 and related compounds are cleared from non-cardiac tissues within 3 to 24 hours after administration. Clearance from the cardiac tissue may require more than 96 hours. Fludeoxyglucose F 18 that is not involved in glucose metabolism in any tissue is then excreted in the urine.

Elimination: Fludeoxyglucose F 18 is cleared from most tissues within 24 hours and can be eliminated from the body unchanged in the urine. Three elimination phases have been identified in the reviewed literature. Within 33 minutes, a mean of 3.9% of the administered radioactive dose was measured in the urine. The amount of radiation exposure of the urinary bladder at two hours post-administration suggests that 20.6% (mean) of the radioactive dose was present in the bladder.

Special Populations: The pharmacokinetics of Fludeoxyglucose F 18 Injection have not been studied in renally-impaired, hepatically impaired or pediatric patients. Fludeoxyglucose F 18 is eliminated through the renal system. Avoid excessive radiation exposure to this organ system and adjacent tissues.

The effects of fasting, varying blood sugar levels, conditions of glucose intolerance, and diabetes mellitus on Fludeoxyglucose F 18 distribution in humans have not been ascertained [see Warnings and Precautions (5.2)].

13 NONCLINICAL TOXICOLOGY

13.1 Carcinogenesis, Mutagenesis, Impairment of Fertility

Animal studies have not been performed to evaluate the Fludeoxyglucose F 18 Injection carcinogenic potential, mutagenic potential or effects on fertility.

14 CLINICAL STUDIES

14.1 Oncology

The efficacy of Fludeoxyglucose F 18 Injection in positron emission tomography cancer imaging was demonstrated in 16 independent studies. These studies prospectively evaluated the use of Fludeoxyglucose F 18 in patients with suspected or known malignancies, including non-small cell lung cancer, colo-rectal, pancreatic, breast, thyroid, melanoma, Hodgkin's and non-Hodgkin's lymphoma, and various types of metastatic cancers to lung, liver, bone, and axillary nodes. All these studies had at least 50 patients and used pathology as a standard of truth. The Fludeoxyglucose F 18 Injection doses in the studies ranged from 200 MBq to 740 MBq with a median and mean dose of 370 MBq.

In the studies, the diagnostic performance of Fludeoxyglucose F 18 Injection varied with the type of cancer, size of cancer, and other clinical conditions. False negative and false positive scans were observed. Negative Fludeoxyglucose F 18 Injection PET scans do not exclude the diagnosis of cancer. Positive Fludeoxyglucose F 18 Injection PET scans can not replace pathology to establish a diagnosis of cancer. Non-malignant conditions such as fungal infections, inflammatory processes and benign tumors have patterns of increased glucose metabolism that may give rise to false-positive scans. The efficacy of Fludeoxyglucose F 18 Injection PET imaging in cancer screening was not studied.

14.2 Cardiology

The efficacy of Fludeoxyglucose F 18 Injection for cardiac use was demonstrated in ten independent, prospective studies of patients with coronary artery disease and chronic left ventricular systolic dysfunction who were scheduled to undergo coronary revascularization. Before revascularization, patients underwent PET imaging with Fludeoxyglucose F 18 Injection (74 to 370 MBq, 2 to 10 mCi) and perfusion imaging with other diagnostic radiopharmaceuticals. Doses of Fludeoxyglucose F 18 Injection ranged from 74 to 370 MBq (2 to 10 mCi). Segmental, left ventricular, wall-motion assessments of asynergic areas made before revascularization were compared in a blinded manner to assessments made after successful revascularization to identify myocardial segments with functional recovery.

Left ventricular myocardial segments were predicted to have reversible loss of systolic function if they showed Fludeoxyglucose F 18 accumulation and reduced perfusion (i.e., flow-metabolism mismatch). Conversely, myocardial segments were predicted to have irreversible loss of systolic function if they showed reductions in both Fludeoxyglucose F 18 accumulation and perfusion (i.e., matched defects).

Findings of flow-metabolism mismatch in a myocardial segment may suggest that successful revascularization will restore myocardial function in that segment. However, false-positive tests occur regularly, and the decision to have a patient undergo revascularization should not be based on PET findings alone. Similarly, findings of a matched defect in a myocardial segment may suggest that myocardial function will not recover in that segment, even if it is successfully revascularized. However, false-negative tests occur regularly, and the decision to recommend against coronary revascularization, or to recommend a cardiac transplant, should not be based on PET findings alone. The reversibility of segmental dysfunction as predicted with Fludeoxyglucose F 18 PET imaging depends on successful coronary revascularization. Therefore, in patients with a low likelihood of successful revascularization, the diagnostic usefulness of PET imaging with Fludeoxyglucose F 18 Injection is more limited.

14.3 Neurology

In a prospective, open label trial, Fludeoxyglucose F 18 Injection was evaluated in 86 patients with epilepsy. Each patient received a dose of Fludeoxyglucose F 18 Injection in the range of 185 to 370 MBq (5 to 10 mCi). The mean age was 16.4 years (range: 4 months to 58 years; of these, 42 patients were less than 12 years and 16 patients were less than 2 years old). Patients had a known diagnosis of complex partial epilepsy and were under evaluation for surgical treatment of their seizure disorder. Seizure foci had been previously identified on ictal EEGs and sphenoidal EEGs. Fludeoxyglucose F 18 Injection PET imaging confirmed previous diagnostic findings in 16% (14/87) of the patients; in 34% (30/87) of the patients, Fludeoxyglucose F 18 Injection PET images provided new findings. In 32% (27/87), imaging with Fludeoxyglucose F 18 Injection was inconclusive. The impact of these imaging findings on clinical outcomes is not known.

Several other studies comparing imaging with Fludeoxyglucose F 18 Injection results to subsphenoidal EEG, MRI and/or surgical findings supported the concept that the degree of hypometabolism corresponds to areas of confirmed epileptogenic foci. The safety and effectiveness of Fludeoxyglucose F 18 Injection to distinguish idiopathic epileptogenic foci from tumors or other brain lesions that may cause seizures have not been established.

15 REFERENCES

1. Gallagher B.M., Ansari A., Atkins H., Casella V., Christman D.R., Fowler J.S., Ido T., MacGregor R.R., Som P., Wan C.N., Wolf A.P., Kuhl D.E., and Reivich M. "Radiopharmaceuticals XXVII. ¹⁸F-labeled 2-deoxy-2-fluoro-D-glucose as a radiopharmaceutical for measuring regional myocardial glucose metabolism in vivo: tissue distribution and imaging studies in animals," *J Nucl Med*, 1977; 18, 990-6.
2. Jones S.C., Alavi, A., Christman D., Montanez, I., Wolf, A.P., and Reivich M. "The radiation dosimetry of 2 [F-18] fluoro-2-deoxy-D-glucose in man," *J Nucl Med*, 1982; 23, 613-617.
3. Kocher, D.C. "Radioactive Decay Tables: A handbook of decay data for application to radiation dosimetry and radiological assessments," 1981, DOE/TIC-1 1026, 89.
4. ICRP Publication 53, Volume 18, No. I-4, 1987, pages 75-76.

16 HOW SUPPLIED/STORAGE AND DRUG HANDLING

Fludeoxyglucose F 18 Injection is supplied in a multi-dose, capped 30 mL and 50 mL glass vial containing between 0.740 to 7.40GBq/mL (20 to 200 mCi/mL), of no carrier added 2deoxy-2-[F 18] fluoro-D-glucose, at end of synthesis, in approximately 15 to 50 mL. The contents of each vial are sterile, pyrogen-free and preservative-free.

NDC 40028-511-30; 40028-511-50

Receipt, transfer, handling, possession, or use of this product is subject to the radioactive material regulations and licensing requirements of the U.S. Nuclear Regulatory Commission, Agreement States or Licensing States as appropriate.

Store the Fludeoxyglucose F 18 Injection vial upright in a lead shielded container at 25°C (77°F); excursions permitted to 15-30°C (59-86°F).

Store and dispose of Fludeoxyglucose F 18 Injection in accordance with the regulations and a general license, or its equivalent, of an Agreement State or a Licensing State.

The expiration date and time are provided on the container label. Use Fludeoxyglucose F 18 Injection within 12 hours from the EOS time.

17 PATIENT COUNSELING INFORMATION

Instruct patients in procedures that increase renal clearance of radioactivity. Encourage patients to:

- drink water or other fluids (as tolerated) in the 4 hours before their PET study.
- void as soon as the imaging study is completed and as often as possible thereafter for at least one hour.

Manufactured by: PETNET Solutions Inc.
810 Innovation Drive
Knoxville, TN 37932

Distributed by: PETNET Solutions Inc.
810 Innovation Drive
Knoxville, TN 37932

PN0002262 Rev. A
March 1, 2011

Trademarks and service marks used in this material are property of Siemens Medical Solutions USA or Siemens AG.

Siemens Medical Solutions USA, Inc.
© Siemens Medical Solutions USA, Inc.
All rights reserved.

All photographs © Siemens Medical Solutions, USA, Inc. All rights reserved.

Note: Original images always lose a certain amount of detail when reproduced.

Global Business Unit

Siemens Medical Solutions USA, Inc.
Molecular Imaging
2501 N. Barrington Road
Hoffman Estates, IL 60192-2061
USA
Telephone: +1 847 304 7700
www.siemens.com/mi

Global Siemens Headquarters

Siemens AG
Wittelsbacherplatz 2
80333 Munich
Germany

**Global Siemens Headquarters
Healthcare Headquarters**

Siemens AG
Healthcare Sector
Henkestrasse 127
91052 Erlangen
Germany
Telephone: +49 9131 84-0
www.siemens.com/healthcare

Address of legal manufacturer

Siemens Medical Solutions USA, Inc.
Molecular Imaging
810 Innovation Drive
Knoxville, TN 37932-9702
USA
Telephone: +1 865 218 2000
www.usa.siemens.com/mi