

# The Potential Role of Ultrashort Echo Time Sequences in MRI Guided Radiotherapy

Soumya Ghose<sup>3</sup>; Robba Rai<sup>1</sup>; Jason Dowling<sup>3</sup>; Sankar Arumugam<sup>1</sup>; Benjamin Schmitt<sup>4</sup>; Gary Liney<sup>1,2</sup>

<sup>1</sup>Liverpool Cancer Therapy Centre, Liverpool Hospital, Sydney, Australia

<sup>2</sup>Ingham Institute for Applied Medical Research, Sydney, Australia

<sup>3</sup>CSIRO, The Australian e-Health & Research Centre, Brisbane, Queensland

<sup>4</sup>Siemens Healthcare, Australia

## Introduction

An increasing number of Oncology Centers are implementing MRI into the planning and monitoring of radiation treated patients so that the benefits of improved soft-tissue contrast can be utilized in both the tumor target and organs-at-risk. The effects of geometric distortion both from the system and the patient are well documented and can be mitigated to acceptable levels of accuracy. However CT is still required to provide the electron density correction that is needed in the dose calculation. The current treatment workflow therefore involves the patient undergoing both a CT and MRI examination and the state-of-the-art solution is to acquire both of these in the same treatment position to facilitate registration in a treatment planning system. Nevertheless there are inherent differences between CT and MRI contrast that makes registration of certain structures and materials difficult. Furthermore, the require-

ment of a CT each time a plan is calculated, means that the potential of MRI for informing and adapting treatment at any point is never fully exploited.


One of the key attractions of MRI for Oncologists is the variety of imaging techniques that can be acquired in a single examination. Ultrashort echo time (UTE) sequences<sup>1</sup> [1] are now being added to the list and finding new clinical applications with their ability to image at tens of microseconds. Recently developed sequences are able to achieve the shortest possible TEs limited only by transmit/receive switching times and gradient performance and requiring no hardware upgrades. These have the potential to generate signal in previously invisible structures and/or reduce susceptibility artefacts both of which could hold advantages for radiotherapy (RT) planning; either providing better registration between the two modalities or moving towards replacing CT altogether.

This commentary describes two phantom studies that were performed to explore the potential application of UTE sequences for RT planning. All imaging was undertaken on our current 3 Tesla wide-bore MAGNETOM Skyra system, which is used as a dedicated 'MR-simulator' at Liverpool Cancer Therapy Centre in South West Sydney.

<sup>1</sup> The product is still under development and not commercially available yet. Its future availability cannot be ensured.

## MR-CT registration: a gold marker study

Fiducial marker insertion is a common clinical practice for radiotherapy (RT) to improve target localization in the prostate. Marker position on the planning CT can be aligned with daily cone beam CT (CBCT) image by table shifts prior to RT treatment. Fiducial marker appearance on CT can include areas of streak artefacts due to their



**1** (1A) 3D rendering of artefacts in the 6 seeds for the FLASH (red) and UTE (yellow) sequences which show a 15 fold difference in volume. (1B) Seeds imaged with UTE show an excellent agreement compared to positions in CT.

high electron density and large Hounsfield units (HU). On MRI, these markers produce no signal but due to the difference in magnetic susceptibility, they can create signal voids and distortions that are not truly representative of the marker dimension [2]. In the prostate, these markers can be hard to visualize on anatomical T2-weighted images which are used in RT planning. An additional gradient-echo sequence such as fast low angle shot (FLASH) is currently used to increase the conspicuity of markers due to the enhanced susceptibility artifact however this is at the cost of accuracy of the marker size and location. Susceptibility artifacts are known to depend on material, orientation to the magnetic field, imaging sequence as well as echo time (TE). With the increased use of MRI for target localization and soft tissue delineation, the MRI appearance of these markers needs to be carefully characterized, particularly for new pulse sequences which may be beneficial for imaging markers. The purpose of the first study was to evaluate the appearance of two commercial fiducial markers using the current departmental protocol and compare it to various types of imaging sequences not currently used in our clinic. Five sequences were performed including the current clinical gradient echo sequence (FLASH), T2-weighted turbo spin echo (TSE), turbo gradient spin echo (TGSE), and two versions of ultra short echo time imaging (UTE and PETRA [3]). The final two sequences enabled a comparison of two minimum TEs of 0.04 ms and 0.06 ms respectively.

To evaluate these effects in a controlled manner, an in-house gelatine phantom was constructed containing three gold soft tissue markers (CIVCO Medical Solutions, Coralville, IA, USA) and 3 polymer markers (Polymark™, Portland, OR, USA). The gold marker dimensions are 1.2 x 3 mm. The Polymark™ dimensions are 1 x 3 mm and made of a PEEK-Optima polymer and medical grade stainless steel core. The fiducial markers were positioned parallel to each other and the phantom was imaged both with CT and MRI with the latter repeated so that the markers were aligned both

perpendicular and parallel to the  $B_0$  field. Results showed that the marker-induced susceptibility artifacts in the FLASH sequence were 15 times greater in total volume compared to the UTE sequence which produced the smallest artifacts (Fig. 1A). The susceptibility artifacts of the (steel cored) polymer markers were larger in dimension compared to gold markers in all cases. The FLASH sequence increased the apparent size of the polymer marker to 5.5 x 10 mm (diameter x length) perpendicular and 4.5 x 10 mm parallel to the main magnetic field. As expected, the TSE sequence reduced susceptibility artifacts compared to the FLASH for both gold and polymer in the perpendicular direction, to 2 x 5.5 mm and 2.5 x 7 mm respectively. The TGSE sequence showed a further reduction in marker artefacts to 3 x 5 mm (gold/perpendicular orientation) and 3.5 x 6.5 mm (polymer/perpendicular). PETRA demonstrated reduced artefacts of 2.5 x 3.5 mm for gold and 2.5 x 4.5 mm for polymer in the perpendicular directions. Overall the UTE images exhibited the smallest dimensions (2 x 3 mm for gold/parallel and 3 x 3 mm for polymer/perpendicular) and was comparable to the actual marker size. The Euclidean distance between the centroids of each automatically contoured UTE gold marker were sub-voxel (mean distance 1.2 mm) when compared to the CT (Fig. 1B).

### Direct MR to CT conversion: validation in animal tissue

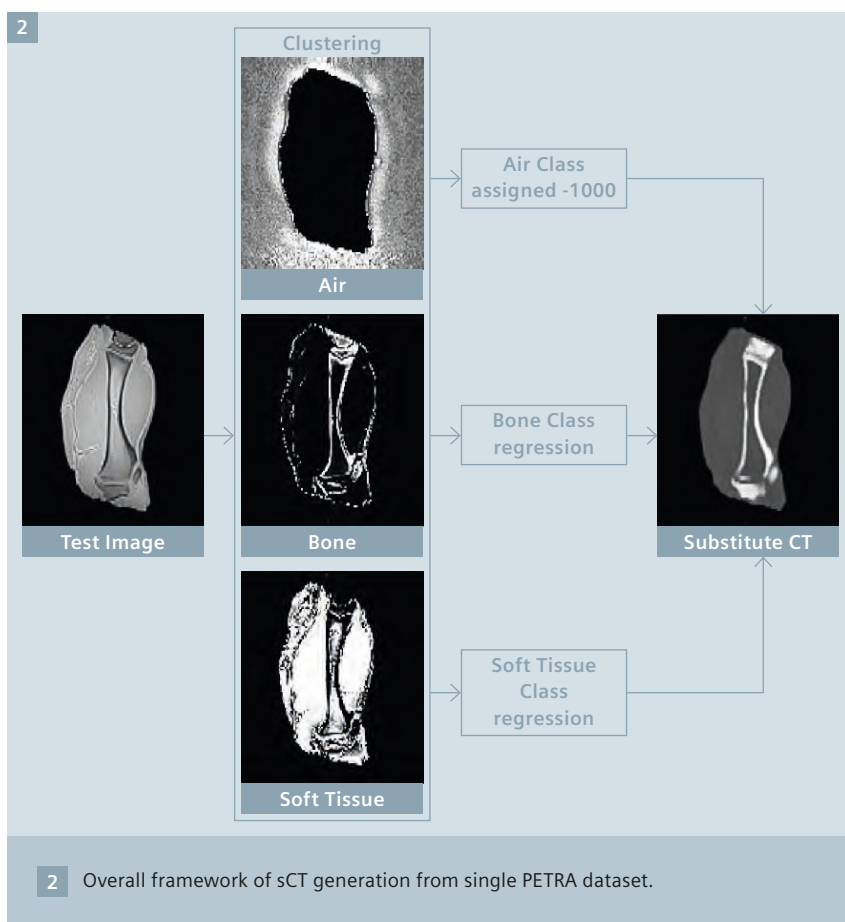
The necessity of a CT scan in the patient workflow has often hindered the flexibility and usefulness of MRI and led to many research centers turning towards MR-only planning<sup>2</sup> solutions – where the need for CT in the process is replaced altogether with the generation of a substitute (sCT) CT dataset from the MRI. The methods for the generation of substitute CT images to date may be broadly categorized into and atlas-based methods [4] and direct conversion or regression-based methods [5].

Atlas based methods have received most attention thus far and have been shown to produce accurate results. They work by first acquiring a representative set of co-registered patient CT and MR images. Registering these atlas MR images to a new patient MRI enables the co-registered CT Hounsfield Units to be mapped (and combined) into an MRI-based substitute CT. However atlas methods can fail in extreme cases not represented by the atlas population. The goal of regression based methods is to establish a relationship between CT and MR signal generated from one or more contrast weightings. In this next study we describe a regression-based approach to generate substitute CT images from just a single PETRA sequence<sup>2</sup>. Whereas soft tissue is easily seen on MRI, cortical bone which is highly electron dense is invisible on routine imaging; at ultrashort echo times signal can be detected with the potential ability to provide a tissue classification model of soft tissue, air and bone. Compared to a purely atlas-based method, the model is computationally efficient and fast.

MRI and CT scans of a porcine leg were used to validate the proposed method – this provides us with cortical bone, fat and muscle in a convenient phantom. The approach may be broadly divided into two parts: (a) an expectation maximization (EM) based clustering of the soft tissues, bone and the air class followed by (b) random forest regression based prediction of CT intensities for every voxels from class probabilities.

A 3D PETRA sequence (TE/TR 0.07/10 ms; 0.93 mm isotropic pixels) was co-registered to the corresponding CT image [6] (1.17 x 1.17 x 2 mm) to build tissue specific regression models. The MRI signal intensity was normalized between zero mean and

<sup>2</sup> Radiotherapy Planning where MR data is the only imaging information is ongoing research. The concepts and information presented in this article are based on research and are not commercially available. Its future availability cannot be ensured.



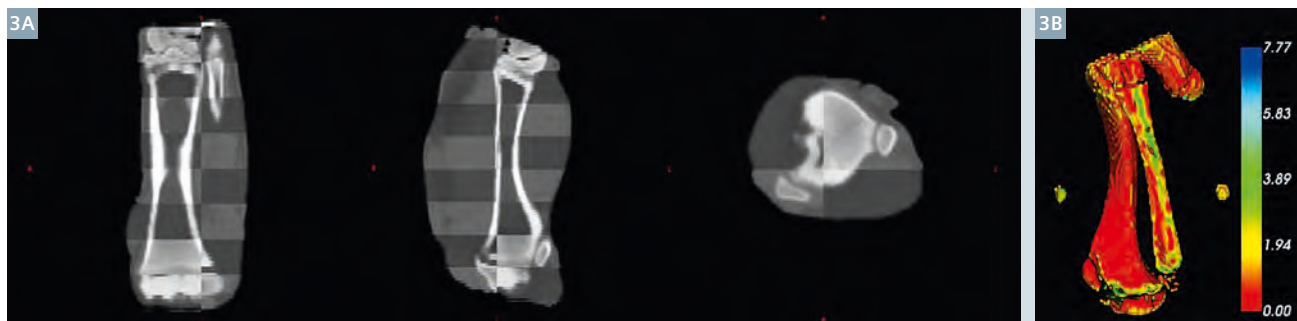
unit variance for faster convergence of the EM algorithm. A 3 class EM based clustering was performed on the co-registered PETRA image to identify the soft tissues, dense bone and air class. Unlike T2-weighted MRI the PETRA sequence is useful in separating the bone and the air classes. For each of the tissue classes (soft tissue, air and bone) the class probabilities and corresponding CT intensities were sampled from

the co-registered CT/PETRA images to build tissue-specific regression models. Thus we model separate random forest regression models for soft tissue and bone. Unlike other regression models used for HU prediction we do not use signal intensities for building the regression model but instead use class probabilities (bone, soft tissues and air probabilities) for a voxel in the random forest regression model to

predict the corresponding HU. The proposed approach is intuitive as there may not be any direct relationship between CT HU and MRI intensities. There is, however, a direct relationship between class probabilities of air, bone and soft tissues and corresponding HU maps. In our model we propose to exploit this relation. Air identified from the EM model is directly assigned a value of -1000 HU.

Further the degree of the regression curve is directly learnt from the class probability distribution.

For validation, an EM based clustering identified the soft tissue, the bone and the air in the phantom. Tissue specific regression models of the soft tissues and the bone were generated from half of the image to predict the other half of the image. The three classes (air, soft tissue and bone) were combined to generate the sCT. Use of half of the bone information during the training stage ensures that the training and the testing voxels were segregated. The entire substitute CT is reconstructed in less than 180 seconds. The entire framework of substitute CT image generation is illustrated in Figure 2. Checkerboard images of the CT and the substitute CT are presented in Figure 3A. The CT and the substitute CT were both thresholded at 500 HU to segment cortical bone. The surface distance difference map of the bone in mm is presented in Figure 3B. Results showed the desired level of accuracy for dosimetry calculations with a mean HU error of 15.6 HU (within the phantom skin boundary) when com-



3 (3A) Checkerboard overlay between the actual CT and PETRA-derived sCT shows good approximation of the CT.  
(3B) The surface distance error map between bone segmented from CT and sCT.

pared to CT. The proposed approach also achieves a 1.3 mm bone surface reconstruction error when compared to CT bone.

## Summary

This very early work shows the potential of ultra-short TE sequences to play an important role in MR guided Radiotherapy. Acquiring signal intensity at this vastly reduced echo time opens up new imaging contrasts and many possibilities. In this report two investigations were performed; Firstly ultrashort TE was used to reduce susceptibility artifacts from fiducial marker seeds. This showed a much closer agreement with known dimension and demonstrated an improved localization accuracy compared to currently used clinical sequences. In

the second example, a single ultra-short sequence was used to generate the substitute CT data directly using a novel modelling approach. This method of generating sCT shows great promise for the generation of fast MRI based sCT radiation therapy planning and PET attenuation correction. Both these methods will need further investigation *in vivo*.

## References

- 1 Robson MD, Gatehouse PD, Bydder M, Bydder GM. Magnetic Resonance: An Introduction to Ultrashort TE (UTE) Imaging. *Journal of Computer Assisted Tomography*. 2003;27:825-46.
- 2 Wachowicz K, Thomas SD, Fallone BG. Characterization of the susceptibility artifact around a prostate brachytherapy seed in MRI. *Medical Physics*. 2006;33:4459-67.
- 3 Grodzki DM, Jakob PM, Heismann B. Ultra short echo time imaging using pointwise encoding time reduction with radial acquisition (PETRA), *Proc ISMRM* (2011):2815.
- 4 Jason A. Dowling et al. (2015). Automatic substitute CT generation and contouring for MRI-alone external beam radiation therapy from standard MRI sequences, *Int. J. Radiat. Oncol. Biol. Phys.*, DOI: <http://dx.doi.org/10.1016/j.ijrobp.2015.08.045>.
- 5 Hsu et al. (2013). Investigation of a method for generating synthetic CT models from MRI scans of the head and the neck for radiation therapy. *Phy. Med. Biol.*, 58(23), 8419-35.
- 6 David Rivest-Hénault et al. (2015). Robust inverse-consistent affine CT-MR registration in MRI-assisted and MRI-alone prostate radiation therapy. *Med Image Anal*. 2015 Jul;23(1):56-69.



Soumya Ghose



Robba Rai



Gary Liney

## Contact

Associate Professor Gary Liney (UNSW)  
Hon Principal Fellow, University of Wollongong  
Ingham Institute for Applied Medical  
Research & Radiation Oncology  
Liverpool Hospital, 1 Campbell Street  
Liverpool NSW 2170, Australia  
Phone: +61 2 8738 9221  
[gary.liney@sswahs.nsw.gov.au](mailto:gary.liney@sswahs.nsw.gov.au)

## Further Reading

For further articles, application tips and clinical talks from experts focusing on the role of MRI in Radiation Therapy, please visit us at:

[www.siemens.com/magnetom-world-rt](http://www.siemens.com/magnetom-world-rt)