

# Whole-body Diffusion-weighted MR Image Analysis with syngo.via Frontier MR Total Tumor Load

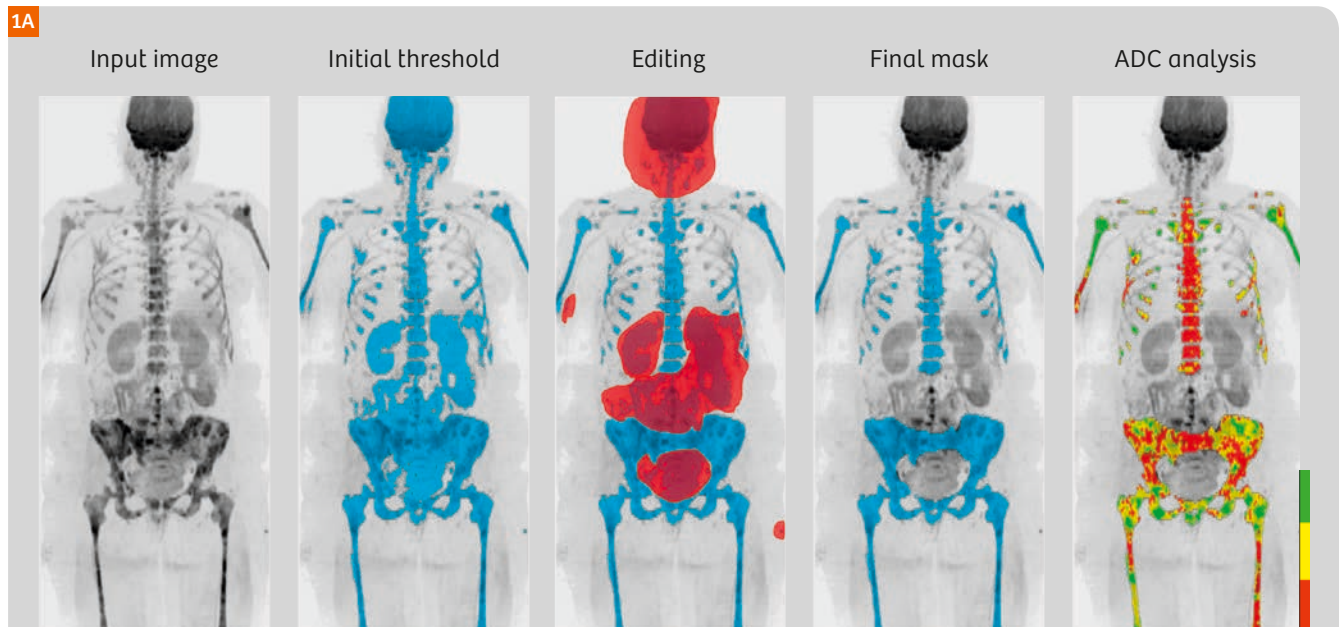
Robert Grimm<sup>1</sup>, Anwar R. Padhani<sup>2</sup>

<sup>1</sup> Siemens Healthineers, Erlangen, Germany

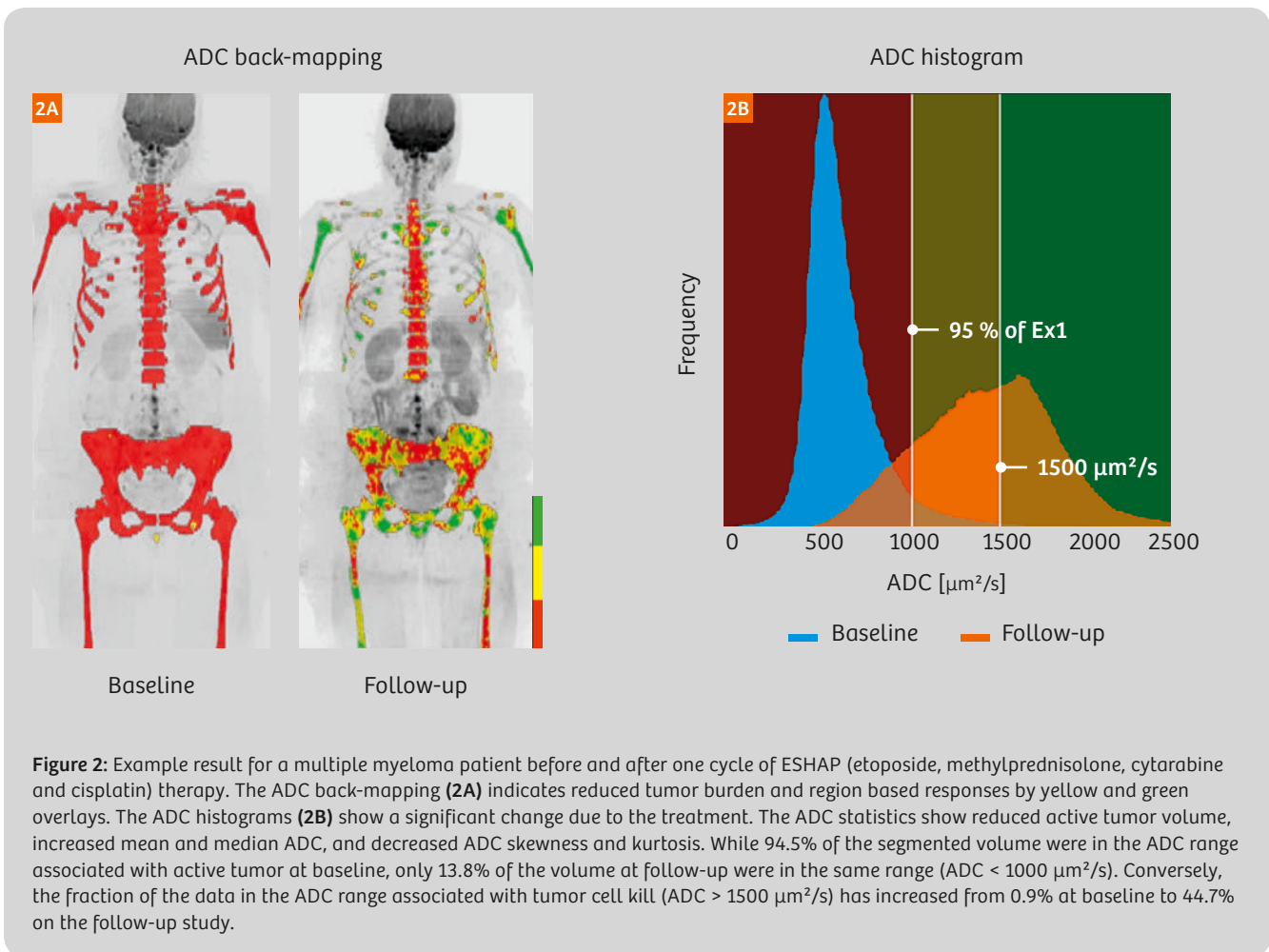
<sup>2</sup> Paul Strickland Scanner Centre, Mount Vernon Hospital, Northwood, Middlesex, UK

Whole-body diffusion-weighted MRI has recently gained a lot of attention as a promising technique for the assessment of multifocal bone disease such as multiple myeloma and bone metastases from breast and prostate cancer [1–3]. Compared to other imaging techniques, diffusion-weighted MRI has a high sensitivity and specificity for disease detection, without exposing the patient to ionizing radiation. Uniquely, diffusion imaging also enables therapy response to be evaluated, with particular application for bone disease. However, one challenge is the relatively large effort in response interpretation, due to the number of images that are generated and the lack of tools for efficient evaluation for multifocal disease.

This limitation was addressed by an efficient analysis approach that has been proposed by Blackledge et al. [4], using a threshold-based segmentation on diffusion-weighted images to identify regions of disease. Based on this segmentation, the overall tumor volume as well as histogram metrics of the corresponding apparent diffusion coefficient (ADC) maps are analyzed. Excellent inter- and intra-observer agreement of this computed approach was demonstrated recently in a pilot study [5].



**Figure 1:** Application workflow. A computed high b-value image ( $b = 800 \text{ s/mm}^2$ ) serves as input. An initial segmentation of the multiple myeloma lesions is obtained by thresholding and then edited to manually exclude regions from the analysis. In this case the brain, neck nodes, salivary glands, kidneys, spleen, and pelvic bowel were removed. Furthermore, the lower lumbar spine was removed, because of artifacts from a spine stabilization. Finally, back-mapping analysis reveals the ADC associated with each voxel, and provides detailed ADC histogram metrics (see also Figure 2).



Quantitative whole-body diffusion MRI is implemented in the *syngo.via* Frontier MR Total Tumor Load<sup>1</sup> released research prototype: It uses diffusion-weighted images as input and allows creation of a 3D mask on diffusion images, for the analysis of the corresponding ADC maps. The prototype supports evaluation of up to two time-points, side-by-side and utilizes maximum intensity projections (MIPs) to facilitate efficient visual assessment of the intermediate result at each step. The workflow is structured in three steps, as depicted in Figure 1. The example illustrates the processing steps for a patient with multiple myeloma:

- 1. Initial segmentation:** An initial mask is defined interactively by applying a threshold to a computed high b-value image (for example,  $b = 800 \text{ s}/\text{mm}^2$ ). An automatic outlier removal can be performed to reduce false positive voxels due to artifacts or T2 shine-through.
- 2. Mask editing:** The initial mask is edited by the user. The user can perform volume punching in order to exclude artifact regions and normal hyperintense organs such

as brain, kidneys, spleen, testes, salivary glands etc, or users can choose to retain only a selected volume of interest. Furthermore, a volumetric, semi-automatic segmentation tool is available for manually adding false negative regions to the mask if not already captured.

Metric	Baseline	Follow-up
Volume [ $\text{cm}^3$ ]	1298	978
ADC mean [ $\mu\text{m}^2/\text{s}$ ]	653	1432
ADC median [ $\mu\text{m}^2/\text{s}$ ]	609	1437
ADC skewness	2.11	0.12
ADC e. kurtosis	8.21	0.07
% Low	94.5	13.8
% High	0.9	44.7

**Table 1:** Segmentation statistics. The tumor volume as well as several histogram metrics have changed significantly during treatment.

<sup>1</sup> *syngo.via* Frontier is for research only, not a medical device.

3. **Analysis:** The ADC histogram and corresponding statistics are computed for the edited masked volume. Histogram metrics include mask volume, mean, median, standard deviation, skewness, excess kurtosis, and customizable percentiles.

Regions of low, intermediate and high ADC values can be inspected interactively by adjusting slider positions on the histogram. Depending on the ADC chosen, the colored back-mapping ADC overlays allow the visual discrimination of regions with untreated disease (typically associated with lower ADC values) compared to disease regions that have been treated effectively (high ADC values).

In the example shown in Figure 2, the 95<sup>th</sup> percentile of the baseline examination, approximately 1000  $\mu\text{m}^2/\text{s}$ , was used as lower ADC threshold and 1500  $\mu\text{m}^2/\text{s}$  was used as upper threshold. The ADC back-mapping in Figure 2A shows a red overlay for voxels with an ADC below 1000  $\mu\text{m}^2/\text{s}$ , a yellow overlay for voxels in the intermediate range, and a green overlay for voxels above 1500  $\mu\text{m}^2/\text{s}$ . The corresponding histograms and limits are shown in Figure 2B. The patient shows changes consistent with a significant response to the therapy, indicated by the emergence of mixed yellow and green regions in the humeri, pelvis, and femur. However, red regions continue to be seen indicating the continued presence of untreated disease.

The histogram statistics, listed in Table 1, show a reduction of the total diffusion volume, from 1298  $\text{cm}^3$  at baseline to 978  $\text{cm}^3$  at follow-up, and a radical change in the histogram shape. The mean and median values have increased from 653 (609)  $\mu\text{m}^2/\text{s}$  at baseline to 1432 (1437)  $\mu\text{m}^2/\text{s}$  in the follow-up examination. The skewness decreased from 2.11 to 0.12, while the excess kurtosis decreased from 8.21 to 0.07.

Further examples obtained with the *syngo.via* Frontier MR Total Tumor Load<sup>1</sup> released research prototype software can be found in the article “*Metastatic Prostate Cancer in Practice – the MET-RADS-P Imaging Response System Using Whole-body MRI*” on page 64 and in the case study “*Observing Endocrine Therapy Resistance in Metastatic Breast Cancer with Whole-body MRI*” on page 80 of this issue of MAGNETOM Flash.

To summarize, the *syngo.via* Frontier MR Total Tumor Load released research prototype provides an efficient and reproducible workflow with quantitative results for the processing and analysis of whole-body diffusion-weighted images in the response assessment setting. It is a promising tool to support the standardization of whole-body MRI for treatment response monitoring of bone disease in particular. Extensions like a fully automatic bone segmentation (as described in “*Whole-body MRI Reading and Bone*

*Assessment with syngo.via Frontier MR Bone Scan*” on page 76 in this issue), simultaneous consideration of other MR parameters such as the normalized signal intensity, fat fraction, or Gadolinium enhancement fraction [6, 7], and integrated classification techniques to detect and separate regions of discordant response [7], may further add to the potential of the technique to promote high-precision medicine.

#### References

- 1 Pawlyn C, Fowkes L, Otero S, et al. Whole-body diffusion-weighted MRI: a new gold standard for assessing disease burden in patients with multiple myeloma? *Leukemia*. 2016;30(6):1446-1448. doi:10.1038/Leu.2015.338.
- 2 Padhani AR, Lecouvet FE, Tunariu N, Koh DM, De Keyzer F, et al. (2016) Rationale for Modernising Imaging in Advanced Prostate Cancer. *European Urology Focus*, Available online. doi:10.1016/j.euf.2016.06.018.
- 3 Padhani AR and Tunariu N, Metastatic response system in using whole body MRI for prostate cancer in practice. See also page 76 in this issue of MAGNETOM Flash.
- 4 Blackledge MD, Collins DJ, Tunariu N, Orton MR, Padhani AR, et al. (2014) Assessment of Treatment Response by Total Tumor Volume and Global Apparent Diffusion Coefficient Using Diffusion-Weighted MRI in Patients with Metastatic Bone Disease: A Feasibility Study. *PLOS ONE* 9(4): e91779. doi: 10.1371/journal.pone.0091779.
- 5 Blackledge MD, Tunariu N, Orton MR, Padhani AR, Collins DJ, et al. (2016) Inter- and Intra-Observer Repeatability of Quantitative Whole-Body, Diffusion-Weighted Imaging (WBDWI) in Metastatic Bone Disease. *PLOS ONE* 11(4): e0153840. doi: 10.1371/journal.pone.0153840
- 6 Amlani A, Ghosh-Ray S, van Ree K, Makris A, D'Sa S, Ostler P, Anyamene N, Padhani AR. Relationships Between Diffusion Weighted Signal Intensity, ADC and Water/fat Content of Malignant Bone Marrow. Program Number: 3447. Proceedings of the International Society of Magnetic Resonance in Medicine. 20th Scientific Meeting and Exhibition, Salt Lake City, May 2013.
- 7 Blackledge MD, Leach M, Rata M, Tunariu N, Koh DM, et al. (2016) Visualizing whole-body treatment response heterogeneity using multi-parametric magnetic resonance imaging. *Journal of Algorithms & Computation Technology*, in press. doi: 10.1177/1748301816668024.

#### Contact



Robert Grimm, Ph.D.  
Siemens Healthcare GmbH  
HC DI MR PI TIO ONCO  
  
Postbox 32 60  
91050 Erlangen  
Germany  
Phone: +49 (0) 9131 84-2717  
robertgrimm@siemens.com