Multi-chamber visualization

for transseptal punctures

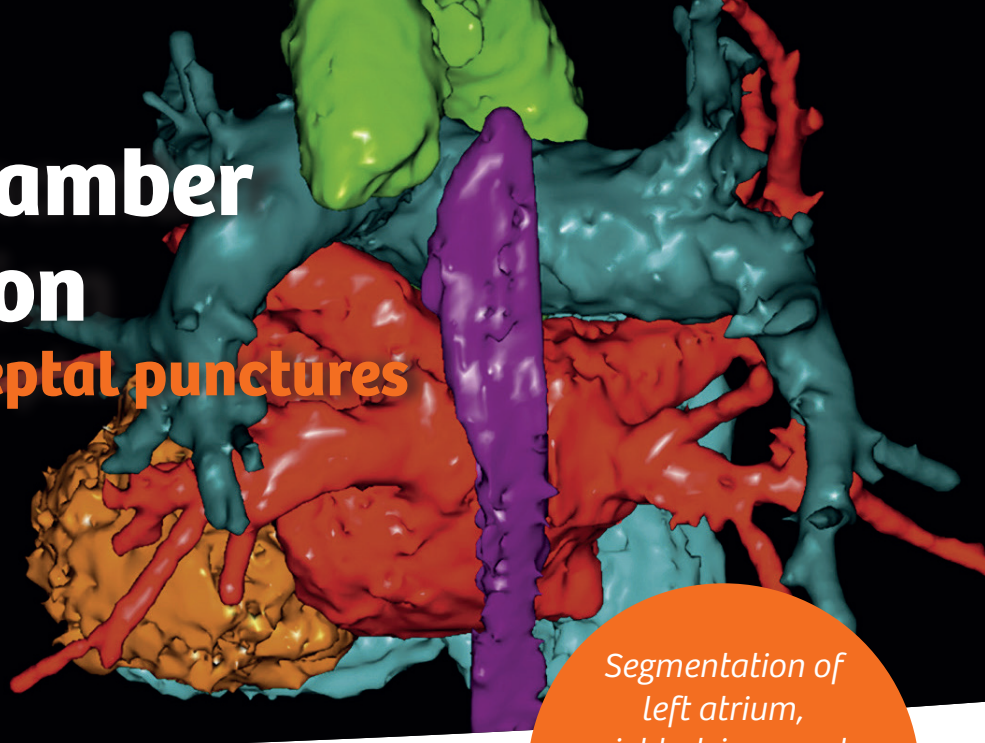

Segmentation of left atrium, right atrium, and ascending aorta used for guidance in transseptal punctures.

Arrhythmias

Study Protocol

Courtesy of
Prof. Johannes Brachmann, MD,
Georg Nölker, MD,
Harald Marschang, MD,
Department of Cardiology,
Klinikum Coburg, Germany

Supported by
- *syngo* DynaCT Cardiac
- *syngo* iPilot
- *syngo* InSpace3D
- *syngo* InSpaceEP

System & Software
Artis zee with 30 × 40 FD
syngo X Workplace

Case Description

Patient history
Left atrium segmentation for ablation treatment.

Diagnosis
Paroxysmal atrial fibrillation.

Treatment
Ablation therapy.

Exclusion criteria:
- Patients with highly irregular heart rates, frequent extra systoles, additional extra pulsations, without sinus heart rhythms.
- Patients with implanted metallic cables and electrodes of a cardiac defibrillator, for example. A pacemaker may be permitted. However, there is some risk of image artifacts.
- Patients who cannot hold their breath for 25-30 seconds.

Tips and tricks
- Patient's arms must be placed above the head.
- If barium contrast medium is administered to visualize the esophagus, use a moderate dose. Excessive contrast causes severe streak artifacts in the images.
- Train patient in breathhold maneuver. Exclude patients who seem to be incapable of holding their breath or who cannot hold still for 25-30 seconds.
- Metallic cables should be removed from the field of view.
- Use X-ray translucent ECG leads and electrodes.

Multi-chamber visualization for transseptal punctures

Acquisition protocol	5s DCT Card ECG
Number of projections	248
System dose	0.54 µGy/f[1]
Increment in degrees	0.8 °/f
Number of sweeps	4 (configurable)
Total scan time in seconds	Approx. 25 seconds
Center of triggered phase	75 % (adjustable)
Width of triggered phase	50 % (recommended)
Reconstructions	
VOI size	Full
Slice matrix	512 × 512
Kernel type	HU
Image characteristics	Normal
Reconstruction mode	Nat fill
Viewing preset	Golden

[1] For software version VC14 and higher, 0.36 uGy/f is used for all 5-second protocols (except for low-dose protocols).

Injection protocol		
Catheter position		Inferior vena cava (not in right atrium)
Contrast medium (CM)		370 mg iodine/mL
Test bolus		w/o
Dilution		w/o
Injection volume		Depending on patient's weight
Weight	**Rate**	**Quantity**
50 kg	3.5 mL/s	105 mL
65 kg	4.0 mL/s	120 mL
80 kg	4.5 mL/s	135 mL
100 kg	5.0 mL/s	150 mL
Injection rate		0.5 mL/s × (square root weight/kg)
Duration of injection		30 s
X-ray delay		10 s
Power injector used		Yes

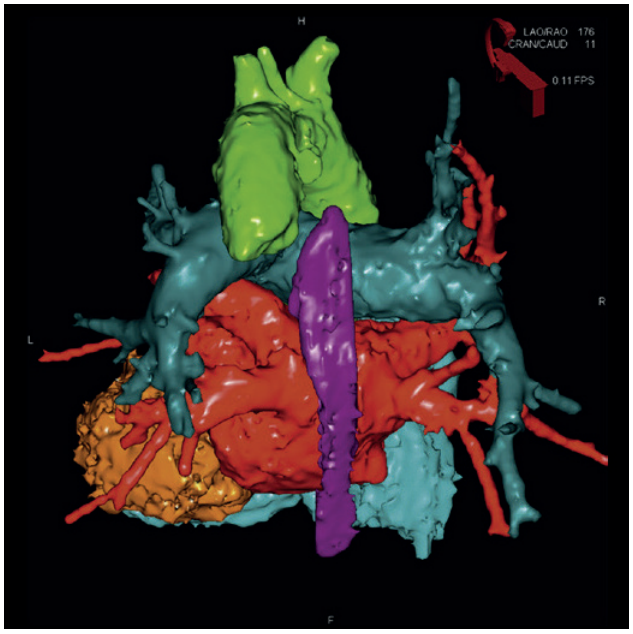

Image segmentation via *syngo* InSpaceEP: left atrium (red), aorta (green), right atrium (blue) in posterior orientation

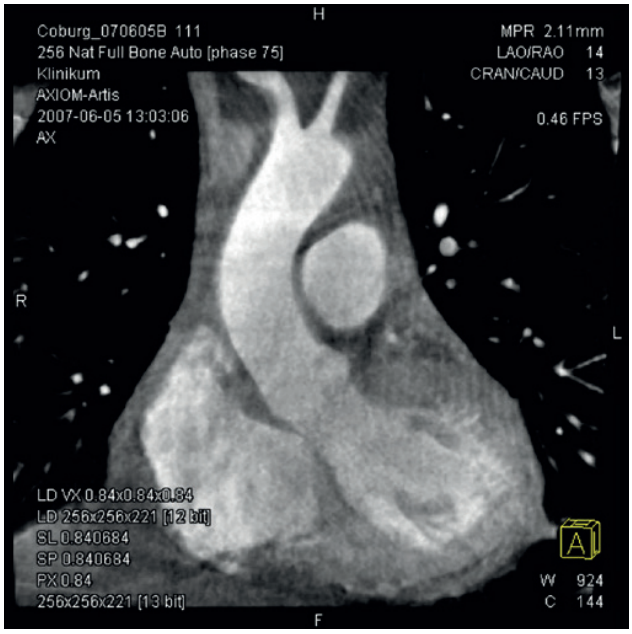

Visualization of MPR slice in sagittal orientation

Siemens Healthineers Headquarters
Siemens Healthcare GmbH
Henkestr. 127
91052 Erlangen, Germany
Phone: +49 9131 84-0
siemens.com/healthineers

Published by Siemens Healthcare GmbH · AT 4672-32 0218 digital · ©Siemens Healthcare GmbH, 2018