

# Coronary CT Angiography – an Appealing Alternative for Coronary Stent Evaluation?

By Guihan Lin, MD; Chunmiao Chen, MD; Chenying Lu, MD; Xianghua Hu, MD, and Jiansong Ji, PhD Department of Radiology, Lishui Central Hospital, The No. 5 Affiliated Hospital of Wenzhou Medical College, Lishui, Zhejiang, P. R. China

## History

A 57-year-old male patient, who had suffered from a left coronary artery stenosis and undergone a percutaneous coronary intervention (PCI) 3 years ago, came for a routine follow-up. A coronary CT angiography (cCTA) was requested for evaluation.

associated morbidity and mortality risks.[2] A noninvasive and less costly technique for detecting in-stent restenosis would be of great interest and use for follow-up examinations.[3] In this case, the latest generation of Dual Source CT scanners was used, which offers a temporal resolution of 66 ms and an isotropic resolution of 0.3 mm.

The images were reconstructed using standard parameters (0.75 mm, kernel Bv40) and are excellent for diagnosis. The in-stent resolution can be further improved using thinner slices (0.5 mm) and a sharper kernel (Bv44) reconstruction. The whole acquisition was completed in 0.18 seconds with only 32 mL of contrast agent. It was not

## Diagnosis

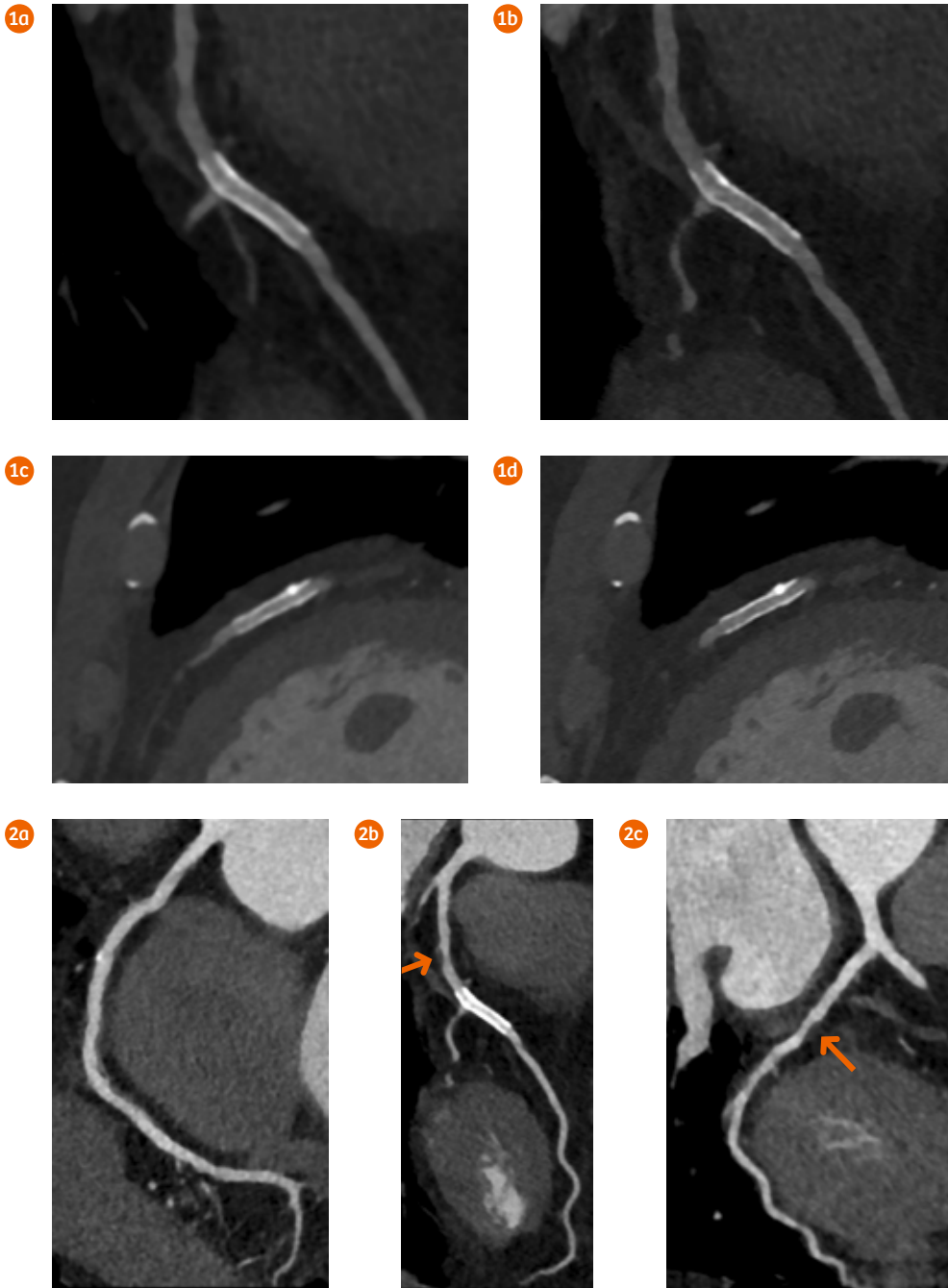
cCTA images showed a patent stent in the middle segment of the left anterior descending artery (LAD) and a moderate stenosis, caused by a non-calcified plaque, proximal to the stent. No signs of an in-stent restenosis or thrombosis were seen. A small calcified plaque and some wall irregularities were shown in the right coronary artery (RCA), as well as a mild stenosis in the proximal circumflex (Cx) caused by a non-calcified plaque.

## Comments

Coronary artery stenting has become the most important nonsurgical treatment for symptomatic coronary artery disease. Conventional coronary angiography has until now been considered the gold standard for assessing stent patency.[1] However, this invasive procedure comes along with

## Examination Protocol

Scanner	SOMATOM Force		
Scan area	Heart	Rotation time	0.25 s
Scan mode	Turbo Flash Spiral	Pitch	3.2
Scan length	129.3 mm	Slice collimation	192 × 0.6 mm
Scan direction	Cranio-caudal	Slice width	0.75/0.5 mm
Scan time	0.18 s	Reconstruction increment	0.5/0.3 mm
Tube voltage	100 kV	Reconstruction kernel	Bv40/Bv44
Effective mAs	500 mAs	Heart rate	57 bpm
Dose modulation	CARE Dose4D™	Contrast	320 mg/mL
CTDI <sub>vol</sub>	4.95 mGy	Volume	32 mL+ saline 40 mL
DLP	84.2 mGy cm	Flow rate	4 mL/s
Effective dose	1.2 mSv	Start delay	100 HU at the aortic arch +5 s



- 1 Curved MPR (Figs. 1a and 1b) and oblique MPR (Figs. 1c and 1d) images demonstrate the difference between stent images reconstructed at 0.75 mm with a standard kernel of Bv40 (Figs. 1a and 1c) and at 0.5 mm with a sharper kernel of Bv44 (Figs. 1b and 1d). The in-stent resolution is significantly improved with thinner slice and sharper kernel reconstruction.
- 2 Curved MPR images show a small calcified plaque and some wall irregularities in the RCA (Fig. 2a), as well as a patent stent in the LAD (Fig. 2b). Non-calcified plaques (arrows) are seen proximal to the stent and in the Cx (Fig. 2c) causing no significant stenosis.

necessary for the patient to hold his breath during scanning. The same image dataset can also be used for assessing the condition of the whole coronary tree.[4] This makes coronary CT angiography an appealing alternative for coronary stent evaluation. ●

**References**

[1] Thayssen P, Jensen LO, Lassen JF, et al. The risk and prognostic impact of definite stent thrombosis or in-stent restenosis after coronary stent implantation. *EuroIntervention* 2012;8(5):591–8.

[2] Jung JI. Multidetector CT imaging of coronary artery stents: is this method ready for use? *Korean Circ J* 2007;37(11):521–9.

[3] Hong C, Chrysant GS, Woodard PK, et al. Coronary artery stent patency assessed with in-stent contrast enhancement measured at multi-detector row CT angiography: initial experience. *Radiology* 2004; 233(1):286–91.

[4] Mahmoud A. Dawoud , Reda A. Alarabawy, et al. Evaluation of coronary stents using multi-detector CT. *The Egyptian Journal of Radiology and Nuclear Medicine* 2016; 47(3):793-801

The outcomes by Siemens' customers described herein are based on results that were achieved in the customer's unique setting. Since there is no "typical" hospital and many variables exist (e.g., hospital size, case mix, level of IT adoption), there can be no guarantee that other customers will achieve the same results.