Transposition of the Great Arteries with Multiple Interventricular Communications and Anomaly of the Coronary Arteries

Valéria de Melo Moreira, MD, Adriano Camargo de Castro Carneiro, MD, Tiago Augusto Magalhães, PhD, MD, Juliana Hiromi Silva Matsumoto Bello, MD, Carlos Eduardo Elias dos Prazeres, MD, Caroline Bastida de Paula, BM and Carlos Eduardo Rochitte, PhD, MD
Department of Cardiovascular CT and MRI of the Heart Hospital (HCor), São Paulo, Brazil

History

A neonate was born with a diagnosis of transposition of the great arteries (TGA) and isolated sub-pulmonary ventricular septal defect (VSD). A post-natal echocardiogram confirmed the diagnosis and additionally revealed an anomaly of the coronary arteries. In view of the cardiac anatomy, spatial arrangement of the great vessels associated with the coronary anomaly, a surgical palliation with pulmonary artery (PA) banding and atrioseptostomy was performed on day 14 after birth. Seven months later, the patient returned for scheduled Senning surgery. Clinical examination revealed an ejection systolic cardiac murmur in the left upper sternal border and cyanosis with blood oxygen saturation of 75% at room air. Senning surgery was performed with ventriculoseptoplasty and removal of PA banding.

In the postoperative period, the patient developed complications, including significant worsening of the respiratory condition and difficulties in extubation. Postoperative echocardiography showed a suspicious cava baffle stenosis. Cardiovascular CT was requested to evaluate intra-atrial baffle abnormalities.

Diagnosis

CT images showed a satisfactory surgical result without significant luminal reduction points in the topography of the pulmonary veins and cava vein tunnels (Fig. 1). An extremely complex interventricular septum with multiple

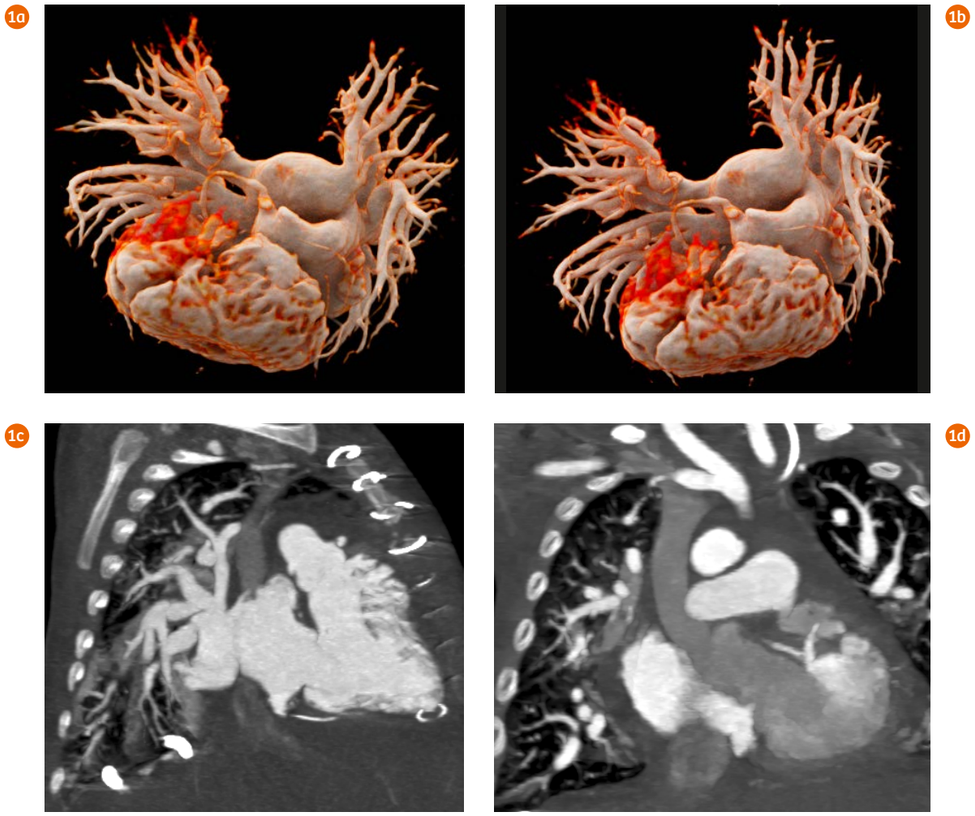

1 Cinematic rendering (Figs. 1a and 1b) and MIP (Figs. 1c and 1d) images show a satisfactory surgical result without significant luminal reduction points in the topography of the pulmonary veins and cava vein tunnels.

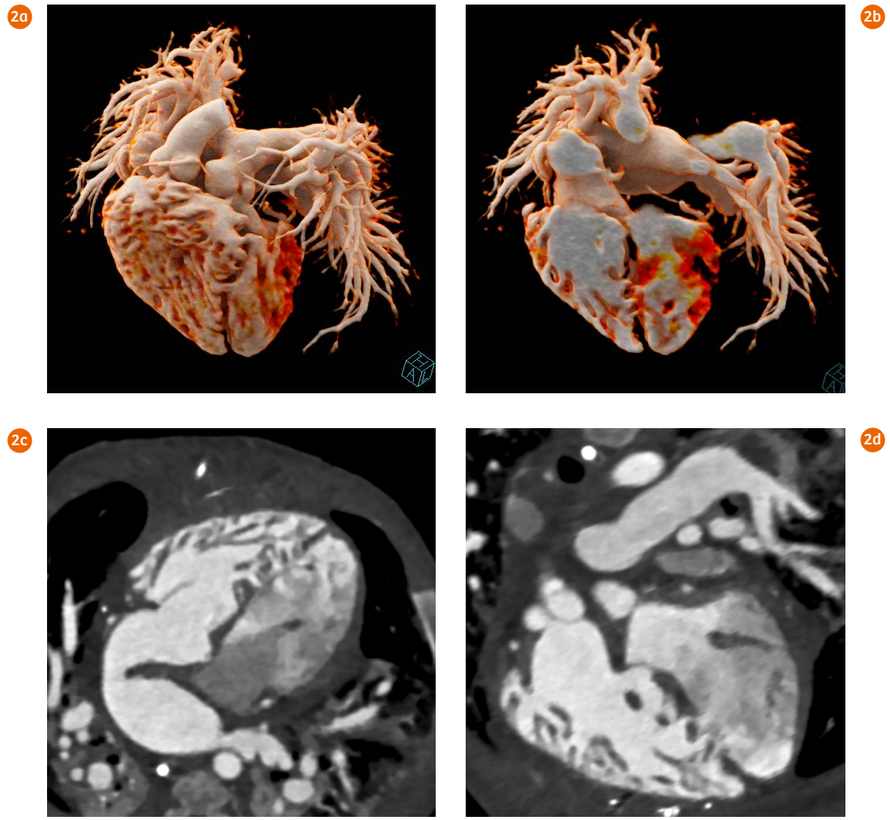

2 Cinematic rendering (Figs. 2a and 2b) and MPR (Figs. 2c and 2d) images show an extremely complex interventricular septum with multiple ventricular septal defects.

3a

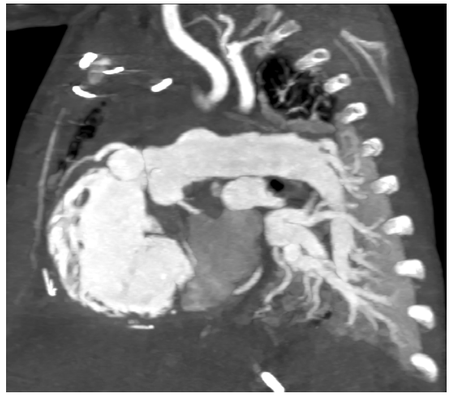

4a

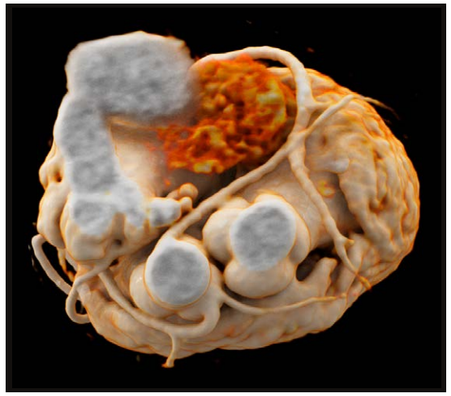

3b

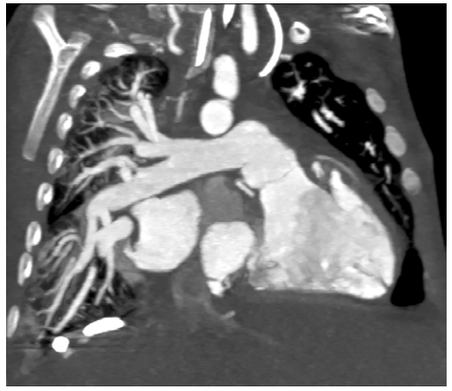

4b

3 MIP images demonstrate a significant dilation of the pulmonary arteries and pulmonary parenchyma congestion pattern.

4 Cinematic rendering (Fig. 4a) and MPR (Fig. 4b) images show the coronary anomaly (Fig. 4c) and a successful VSD patch (Fig. 4b, arrow).

VSDs (Fig. 2) and a severe hemodynamic repercussion were evidenced. The pulmonary arteries were significantly dilated with patterns of pulmonary parenchyma congestion (Fig. 3). The coronary anomaly (Fig. 4a) and a successful patch (Fig. 4b) of a VSD were confirmed.

PA rebanding was performed to reduce the pulmonary hyperflow. The mechanical ventilation was successfully withdrawn and the patient was discharged from the hospital.

Comments

TGA is a congenital cardiac malformation characterized by atrioventricular concordance and ventriculoarterial discordance. The association with other cardiac malformations such as ventricular septal defect and coronary anomalies may occur and defines clinical presentations and surgical management. The Senning procedure is an atrial switch operation diverting the venous drainage. It is an alternative surgical approach when the Jatene arterial switch operation is not feasible.[1-7]

Multiple interventricular communications ("Swiss cheese" septal defects) often become a therapeutic challenge that require precise preoperative imaging for accurate delineation of the location, number, shape and size of the ventricular septal defects and a clear appreciation of understanding the adjacent anatomy. In this case, CT images demonstrated complex muscular ventricular septal defects, which had not previously been diagnosed by echocardiography. This finding was not favorable for treatment strategies such as device closure or a surgical procedure.

Using the advanced technologies such as scanning speed and radiation dose reduction, CT has become a complementary diagnostic tool in challenging pediatric cardiac cases with complex anatomical scenario. In this case, the entire cardiac acquisition was completed in 0.27 seconds at free breathing using Flash mode. A combination of dose reduction techniques, such as CARE Dose4D™ (real-time anatomic exposure control) and SAFIRE (sinogram affirmed iterative reconstruction) were integrated to achieve an effective dose as low as 0.9 mSv.

Examination Protocol

Scanner	SOMATOM Definition Flash		
Scan area	Thorax	**Rotation time**	0.28 s
Scan mode	Flash mode	**Pitch**	3.4
Scan length	122.4 mm	**Slice collimation**	128 × 0.6 mm
Scan direction	Cranio-caudal	**Slice width**	0.6 mm
Scan time	0.27 s	**Reconstruction increment**	0.4 mm
Tube voltage	80 / 80 kV	**Reconstruction kernel**	I26f
Effective mAs	200 mAs	**Heart rate**	78–85 bpm
Dose modulation	CARE Dose4D™	**Contrast**	370 mg/mL
$CTDI_{vol}$	0.91 mGy	**Volume**	12 mL
DLP	15 mGy cm	**Flow rate**	1 mL/s
Effective dose	0.9 mSv	**Start delay**	Bolus tracking, manual start

References

[1] Jatene AD, Fontes VF, Paulista PP, Souza LC, Neger F, Galantier M, et al. Anatomic correction of transposition of the great vessels. J Thorac Cardiovasc Surg. 1976;72(3):364–70.

[2] Hutter PA, Kreb DL, Mantel SF, et al: Twenty-five years' experience with the arterial switch operation. J Thorac Cardiovasc Surg 2002;124:790-797.

[3] Evans WN. The arterial switch operation before Jatene. Pediatr Cardiol. 2009;30:119-124.

[4] Fricke TA, d'Udekem Y, Richardson M, et al. Outcomes of the arterial switch operation for transposition of the great arteries: 25 years of experience. Ann Thorac Surg. 2012;94:139–45.

[5] Anderson BR, Ciarleglio AJ, Hayes DA, Quaegebeur JM, Vincent JA, Bacha EA. Earlier arterial switch operation improves outcomes and reduces costs for neonates with transposition of the great arteries. J Am Coll Cardiol. 2014;63(5):481–7.

[6] Lim HG, Kim WH, Lee JR, Kim YJ. Long-term results of the arterial switch operation for ventriculo-arterial discordance. Eur J Cardiothorac Surg. 2013;43:325–34

[7] Lalezari S, Bruggemans EF, Blom NA, Hazekamp MG. Thirty-year experience with the arterial switch operation. Ann Thorac Surg. 2011;92:973–9.

The outcomes by Siemens' customers described herein are based on results that were achieved in the customer's unique setting. Since there is no "typical" hospital and many variables exist (e.g., hospital size, case mix, level of IT adoption), there can be no guarantee that other customers will achieve the same results.

In clinical practice, the use of SAFIRE may reduce CT patient dose depending on the clinical task, patient size, anatomical location, and clinical practice. A consultation with a radiologist and a physicist should be made to determine the appropriate dose to obtain diagnostic image quality for the particular clinical task.