Effective Exclusion of Myocardial Ischemia with Cardiovascular Magnetic Resonance Imaging

Stephanie Funk, MD, Edyta Blaszczyk, MD, Agnieszka Toepper, MD, Jeanette Schulz-Menger, MD, Working Group Cardiac MRI, Experimental and Clinical Research Center, a cooperation between Charité Medical Faculty Berlin, Max Delbrück Center for Molecular Medicine, and Helios Clinic Berlin-Buch, Department of Cardiology and Nephrology, Berlin, Germany

1

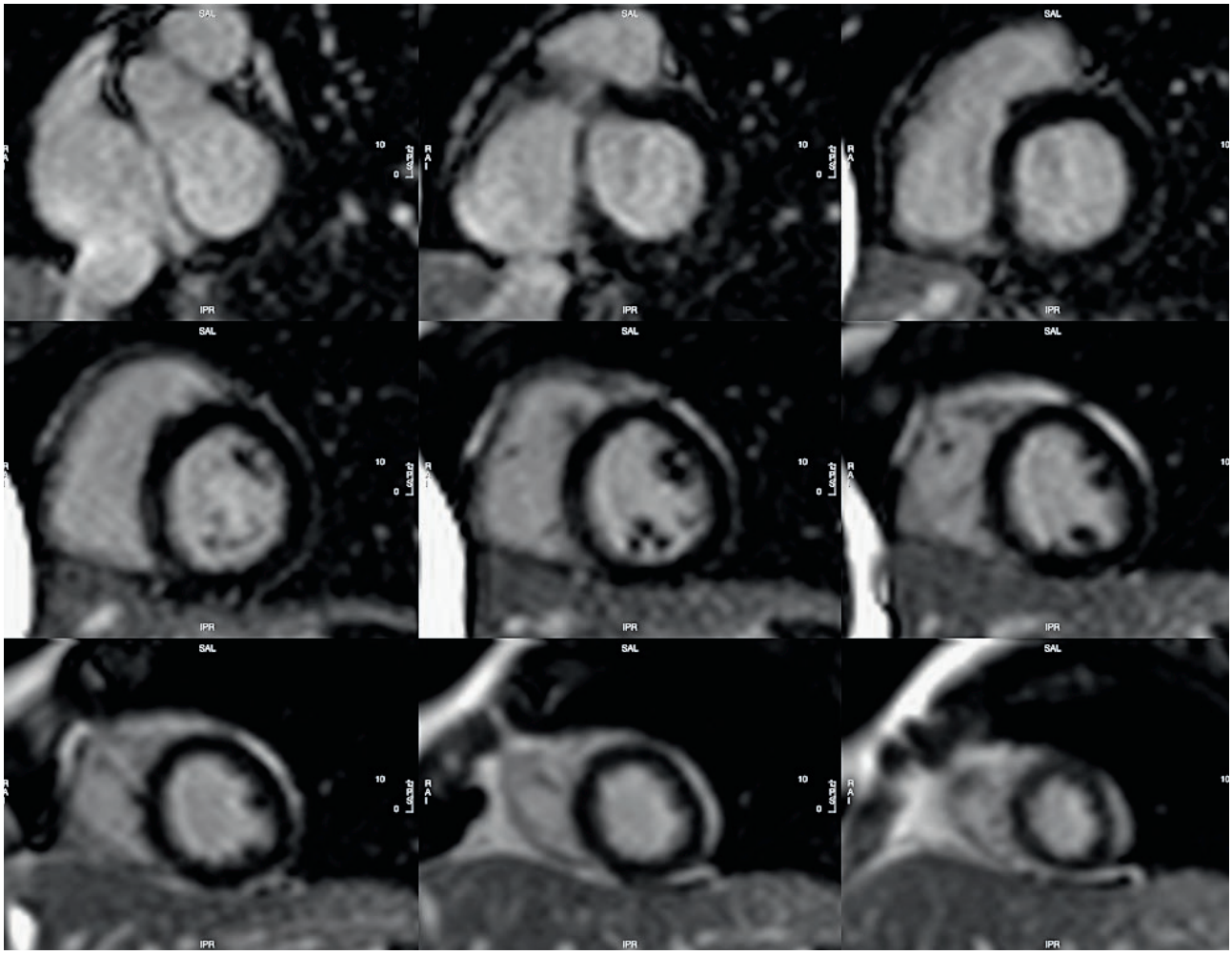

Background

Cardiovascular magnetic resonance (CMR) imaging provides unique information regarding myocardial tissue differentiation as well as a comprehensive examination of basic cardiac function. Today, it is included in as many as 29 guidelines from the European Society of Cardiology. Nevertheless, it is not yet routinely used in all institutions nor is its versatility fully exploited.

One obstacle facing CMR is the perception that it is difficult and lengthy. However, the development of more robust and faster imaging techniques has significantly reduced scan times in recent years. Depending on the indication, cardiac scan times can range from 5 to 45 minutes (see Table 1). Of course, complex or unusual cases, such as congenital heart disease, may take longer.

Medical doctors often mistakenly believe that CMR is unsuitable for very sick patients even though it can provide unique information for further therapy guidance. New technologies such as real-time imaging, Compressed Sensing and motion correction algorithms now make CMR imaging available to patients with arrhythmias and those unable to hold their breath. Currently, even though image quality may be slightly impaired, most diagnostic requests can be covered. Real-time cine imaging is already available in clinical routine. Furthermore, multislice late gadolinium enhancement (LGE) images are now possible without breath-holds. Motion-corrected perfusion imaging allows for stress perfusion with free breathing.

Today cardiovascular MR is included in 29 guidelines from the European Society of Cardiology.

CMR is a recognized technique to assess coronary artery disease (CAD) [1]. What is more, CMR is the only imaging modality that can differentiate myocardial tissue, including the detection of irreversible changes such as necrosis, fibrosis, and fat infiltration, as well as reversible injury such as edema. Quantitative parametric mapping techniques such as MyoMaps technology have added significantly to other contrast-enhanced and non contrast-enhanced imaging techniques to clearly discriminate between tissue types and thereby inform treatment decisions. [2–4]

2

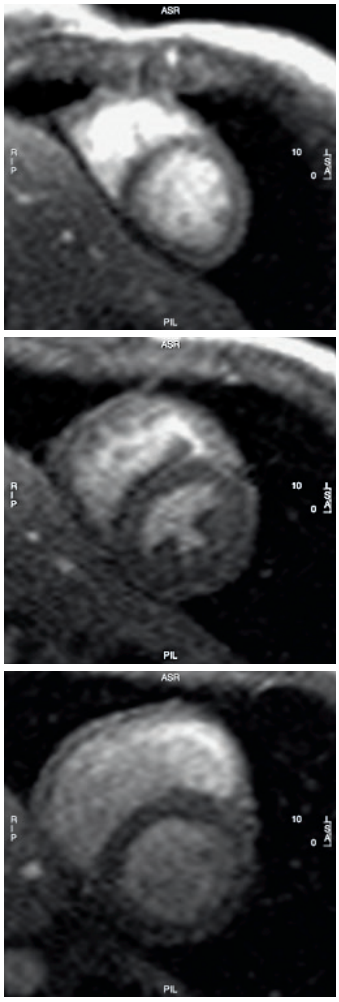

1 The late gadolinium enhancement (LGE) CMR imaging technique without breath-hold showed no fibrosis or scarring.

2 It was possible to rule out myocardial ischemia using stress perfusion imaging without breath-hold in 15 minutes.

A significant advantage of CMR is that it enables the early detection of myocardial injury in preserved ejection fraction, allowing a decision on the course of therapy to be taken sooner. The following case illustrates the potential speed of a CMR examination and its high-quality differentiation of tissue. The scan was performed on a 1.5T MAGNETOM Avanto[fit] at Helios Clinics in Berlin-Buch.

Patient history

A 42-year-old female with shortness of breath and atypical thoracical pain was referred to the MR unit for adenosine stress CMR to exclude significant coronary artery disease.

The patient anatomy did not allow stress echocardiography and ionizing radiation was avoided due to her age.

Cardiovascular MR provides information on function, ischemia and viability in a short scan without ionizing radiation.

Treatment

Due to claustrophobia-related self-premedication with cumulative 20 mg oral Diazepam and persistent anxiety she was not able to follow the breathing instructions. The MRI protocol was shortened to the essential steps as follows: localizer, cardiac function (long axis), adenosine stress, cardiac function (short axis) and LGE in overview technique (multislice, free-breathing) after a single dose of contrast medium. The whole examination with free breathing was completed in 15 minutes (see Table 2).

In the examination we saw no signs of cardiac ischemia fibrosis or scarring (Figs. 1, 2). Therefore, we could rule out coronary artery disease.

Table 1: Average scan times for routine CMR indications*

Indication	Average scan time
Left and right ventricular function	5–10 min
Angiography	10 min
Inflammatory disease	20–30 min
Viability assessment	20–30 min
Adenosine perfusion	15–30 min
Valvular disorders	10–30 min

* Data on file: Helios Clinics Berlin-Buch, Department of Cardiology and Nephrology, Berlin, Germany.

Table 2: Scan protocol to assess myocardial ischemia

Scan	Scan times
Localizer	1 min
Function LAX	3 min
Stress perfusion	6 min
Function SAX	4 min
LGE overview	1 min
Total scan time	**15 min**

Example: 15-minute CMR scan to rule out coronary artery disease

Conclusion

We perform over 3,000 clinical CMR examinations per year, mainly on a 1.5T scanner on in- and out-patients alike. Both groups include patients with arrhythmias including atrial fibrillation and many patients who cannot hold their breath. In nearly all cases, we achieve diagnostic image quality. Preparation of ICU patients is more time-consuming, but we keep scan time short since we focus on the main clinical questions.

At a recent meeting of the Society for Cardiac Magnetic Resonance board members concluded in a position statement that CMR provides more definitive, relevant, and actionable answers than other non-invasive imaging techniques. Moreover, a CMR exam provides comprehensive information and has superior diagnostic and prognostic power, without the need for radiation.

Given the fact that fast and robust CMR imaging techniques are now available, the benefits of CMR can be extended to more patients, including those with cardiac arrhythmias and dyspnea. Standardized protocols and guidance tools such as the Cardiac Dot Engine are equally paving the way for the use of CMR imaging in clinical routine.

References

[1] Kramer CM, Barkhausen J, Flamm SD, Kim RJ, Nagel E, Society for Cardiovascular Magnetic Resonance Board of Trustees Task Force on Standardized P. Standardized cardiovascular magnetic resonance (CMR) protocols 2013 update. Journal of cardiovascular magnetic resonance: official journal of the Society for Cardiovascular Magnetic Resonance. 2013;15:91. doi: 10.1186/1532-429X-15-91. PubMed PMID: 24103764; PubMed Central PMCID: PMC3851953.

[2] Moon JC, Messroghli DR, Kellman P, Piechnik SK, Robson MD, Ugander M, et al. Myocardial T1 mapping and extracellular volume quantification: a Society for Cardiovascular Magnetic Resonance (SCMR) and CMR Working Group of the European Society of Cardiology consensus statement. Journal of Cardiovascular Magnetic Resonance : official journal of the Society for Cardiovascular Magnetic Resonance. 2013;15:92. doi: 10.1186/1532-429X-15-92. PubMed PMID: 24124732; PubMed Central PMCID: PMC3854458.

[3] Bulluck H, Maestrini V, Rosmini S, Abdel-Gadir A, Treibel TA, Castelletti S, et al. Myocardial T1 mapping. Circulation journal: official journal of the Japanese Circulation Society. 2015;79(3): 487-94. doi: 10.1253/circj.CJ-15-0054. PubMed PMID: 25746524.

[4] Wassmuth R, Schulz-Menger J. Cardiovascular magnetic resonance imaging of myocardial inflammation. Expert review of cardiovascular therapy. 2011;9(9):1193-201. doi: 10.1586/erc.11.118. PubMed PMID: 21932962.

Contact
Gaia Banks
gaia.banks@siemens-healthineers.com