

# Traumatic Bone Bruise of the Right Distal Tibial Metaphysis

Paulo Victor Partezani Helito, MD\*; Isabel Curcio Felix Louza, MD\*; Caroline Bastida de Paula, BD\*\* and Marcos Felipe de Paula Corrêa, MD\*

\* Department of Radiology, Hospital Sírio Libanês, São Paulo, Brazil

\*\* Siemens Healthineers, Brazil

## History

A 59-year-old male patient, suffering from consistent pain in the right ankle, presented for checkup. He had fallen onto rocks while walking on the beach. Physical examination revealed local swelling and abrasions. Conventional X-ray showed no signs of fracture in the right foot and ankle. Dual Energy CT (DECT) was performed for further evaluation.

## Diagnosis

DECT images showed a hyperdense area in the anterolateral distal tibial metaphysis suggesting a bone marrow edema. No signs of fracture were seen. Magnetic Resonance Imaging (MRI) performed the next day ruled out ligament injuries and confirmed bone marrow edema in the same area.

## Comments

Bone marrow edema, also called bone bruise, is usually caused by trauma. Although bone bruises are often regarded as benign and self-limiting, the importance of their visualization is highlighted by study findings suggesting that severe bone bruises can be a precursor of early degenerative changes, even in the absence of other substantial soft-tissue trauma.[1] The

pathophysiology of traumatic osseous edema is characterized by micro-fractures of marrow trabeculae with capillary lesions, leading to extravasation of fluid and hemorrhage into marrow spaces. These pathological processes can hardly be visualized in conventional CT since they produce very subtle changes in CT attenuation values and densities. MRI is usually applied to visualize bone bruises as one of the aspects in the evaluation of bone trauma. However, there are patients who have contraindications to MRI or for whom MRI is not available. Since the introduction of Dual Source CT scanners, advanced DECT technologies, such as DE Virtual Noncalcium have been developed. This uses the

attenuation measurements acquired at two different kV settings and calculates a virtual noncalcium image using three-material decomposition method.[2] This allows for an assessment of marrow space and potential visualization of bone bruises. A special filter technique, Selective Photon Shield, enables significant separation of energy spectrum at 80 and 140 kV settings. Other techniques such as CARE Dose4D™ (Real-time anatomic exposure control) and ADMIRE (Advanced modeled iterative reconstruction) are also available to achieve a dose neutral DECT examination. ●

## Examination Protocol

Scanner	SOMATOM Definition Flash
Scan area	Right ankle
Scan mode	Dual Energy
Scan length	241 mm
Scan direction	Cranio-caudal
Scan time	12.6 s
Tube voltage	80 / Sn140 kv
Effective mAs	264 / 135 mAs
Dose modulation	CARE Dose4D™
CTDI <sub>vol</sub>	11.29 mGy
DLP	307 mGy cm
Rotation time	1 s
pitch	1
Slice collimation	32 × 0.6 mm
Slice width	0.6 mm
Reconstruction increment	0.3 mm
Reconstruction kernel	Q30s (ADMIRE 2)

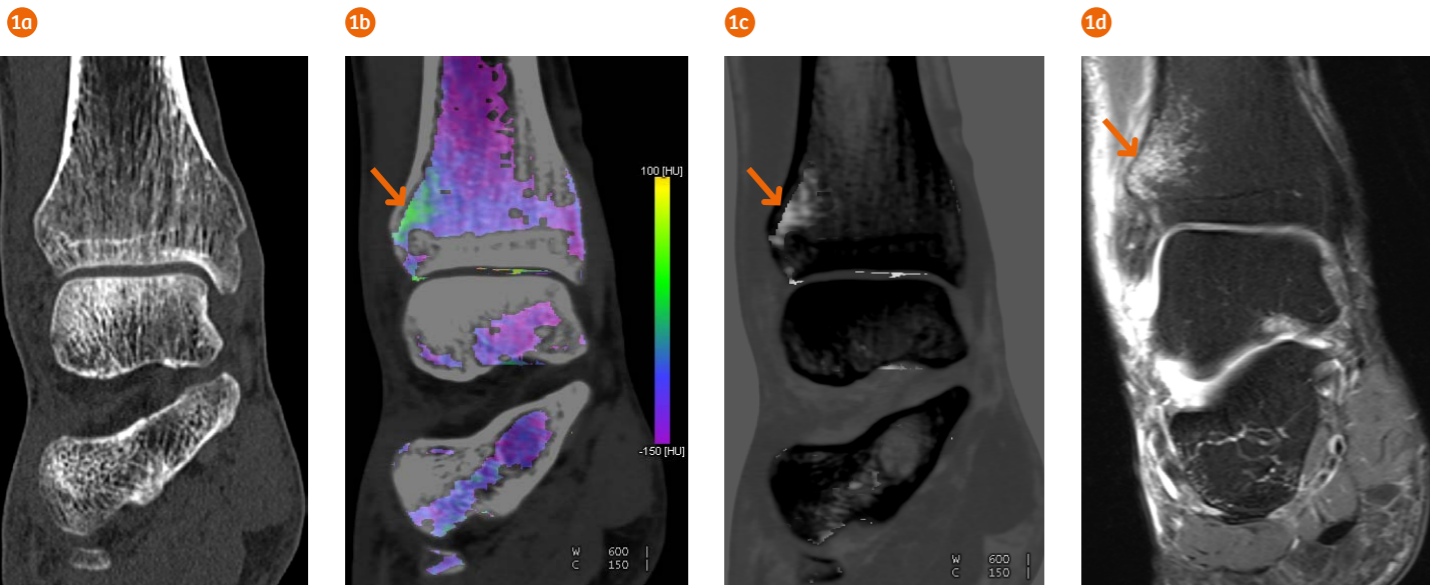
## References

[1] Boks SS, Vroegindewij D, Koes BW, Hunink MG, Bierma-Zeinstra SM. Follow-up of occult bone lesions detected at MR imaging: systematic review. *Radiology* 2006; 238(3):853–862.

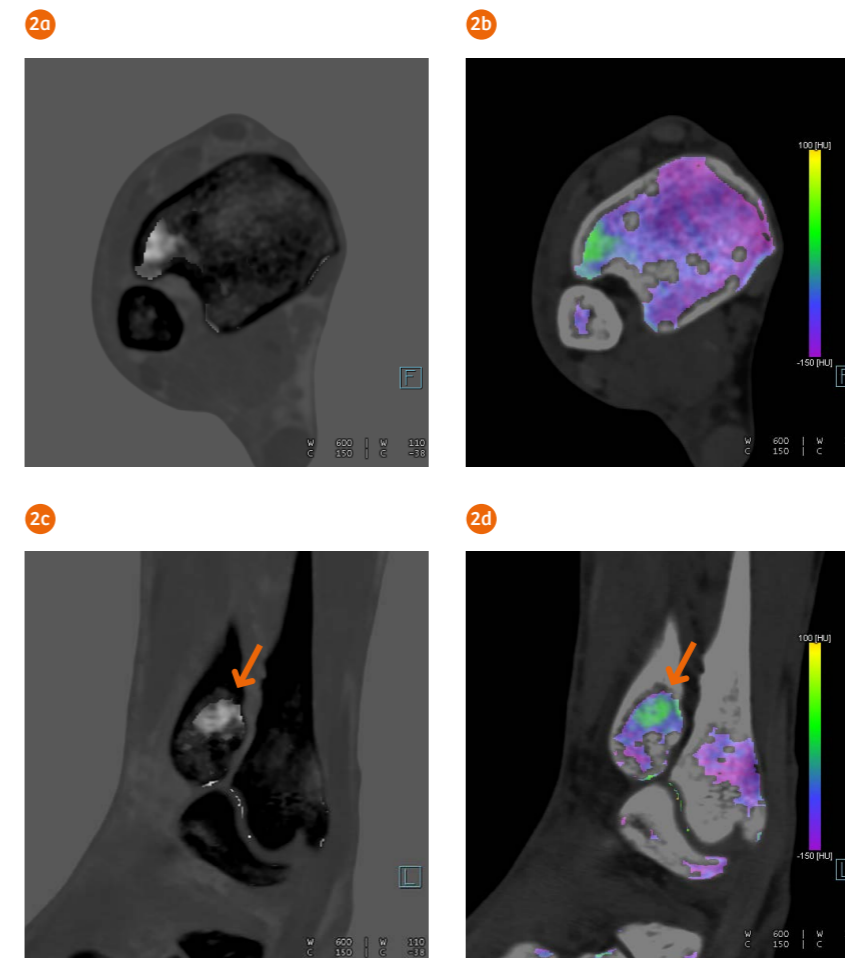
[2] Pache et al. Dual-Energy CT Virtual Noncalcium Technique: Detecting Posttraumatic Bone Marrow Lesions – Feasibility Study. *Radiology* 2010; 256:617–624.

In clinical practice, the use of ADMIRE may reduce CT patient dose depending on the clinical task, patient size, anatomical location, and clinical practice. A consultation with a radiologist and a physicist should be made to determine the appropriate dose to obtain diagnostic image quality for the particular clinical task.

The outcomes by Siemens Healthineers customers described herein are based on results that were achieved in the customer's unique setting. Since there is no "typical" hospital and many variables exist (e.g., hospital size, case mix, level of IT adoption), there can be no guarantee that other customers will achieve the same results.



1 A coronal MPR image (Fig. 1a) shows no signs of bone fracture. DE Virtual Noncalcium images (Figs. 1b and 1c) reveal a hyperdense area in the anterolateral distal tibial metaphysis (arrows) suggesting a bone marrow edema, which was confirmed by MRI (Fig. 1d, arrow).



2 Axial (Figs. 2a and 2b) and sagittal (Figs. 2c and 2d) views of DE Virtual Noncalcium images show a hyperdense area in the anterolateral distal tibial metaphysis (arrows) suggesting a bone marrow edema.