Isolated Common Iliac Artery Aneurysm – Complicated by Peripheral Artery Insufficiency in the Lower Limb?

By Shufang Cheng, MD; JianSong Ji, MD; Xi Zhao*, MD
Department of Radiology, Lishui Central Hospital, The No. 5 Affiliated Hospital of Wenzhou Medical College, Lishui, Zhejiang, P.R. China
*Siemens Healthineers China

History

An 80-year-old male patient, complaining of chest discomfort, shortness of breath and lower limb edema, came to the hospital for a checkup. A Dual Energy (DE) CT angiography (CTA), followed by a dynamic 4D CTA were performed for evaluation.

Diagnosis

CTA images revealed an isolated aneurysm in the right common iliac artery (RCIA). It extended from the aortic bifurcation to the proximal right external iliac artery (REIA), with a maximum diameter of 4.1 cm. Severe stenoses in the proximal left renal artery (LRA) and the left internal iliac artery (LIIA) were seen. Extensive calcified plaques in multiple abdominal and peripheral arteries, causing mild to moderate stenoses, were also visualized. Peripheral artery insufficiency was ruled out by dynamic 4D CTA however severe stenosis in the right posterior tibial artery (RPTA), caused by calcified plaques, was confirmed. Subsequent percutaneous implantation of endovascular stent-grafts was successfully performed in the aortic bifurcation and in the proximal LRA, and the patient's symptoms were significantly improved.

Examination Protocol

Scanner	SOMATOM Force	
Scan area	Runoff	Upper femur to toes
Scan mode	Dual Source DE	Adaptive 4D Spiral
Scan length	1,294 mm	796 mm
Scan direction	Cranio-caudal	Bi-directional
Scan time	3.6 s	21 s
Tube voltage	70 / Sn150 kV	80 kV
Effective mAs	136 / 47 mAs	35 mAs
Dose modulation	CARE Dose4D	CARE Dose4D
$CTDI_{vol}$	2.99 mGy	6.46 mGy
DLP	399.4 mGy cm	493 mGy cm
Rotation time	0.28 s	0.25 s
Pitch	0.6	–
Slice collimation	192 × 0.6 mm	48 × 1.2 mm
Slice width	1.5 mm	1.5 mm
Reconstruction increment	1.0 mm	1.0 mm
Reconstruction kernel	Qr40 (ADMIRE 3)	Br36 (ADMIRE 3)
Contrast	320 mg/mL	320 mg/mL
Volume	90 mL + 40 mL saline	35 mL + 35 mL saline
Flow rate	5 mL/s	3.5 mL/s
Start delay	Bolus tracking with 100 HU at the popliteal artery + 5 s	Same as CTA trigger time

1 A cinematic VRT image shows an overview of the complete scan range.

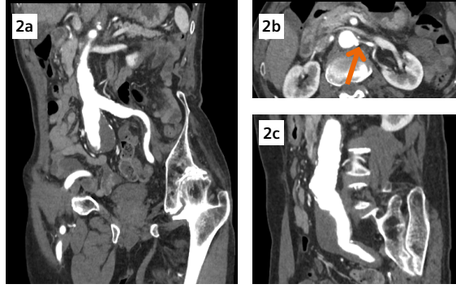

2 MPR images show an aneurysm in the RCIA extending from the aortic bifurcation to the proximal REIA. A severe stenosis of the left renal artery is also seen (Fig. 2b, arrow).

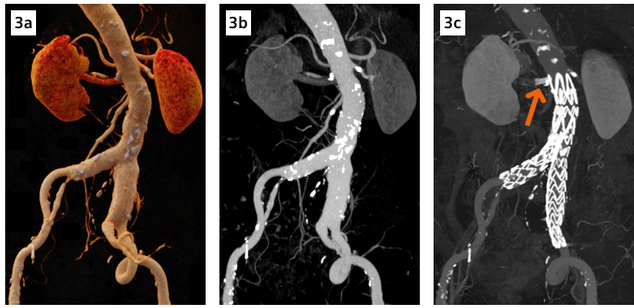

3 Right-posterior views of pre- (Fig. 3a, cVRT; Fig. 3b, MIP) and post (Fig. 3c, MIP) stenting show an ectatic RCIA, severely stenosed LRA and LIIA, as well as stent grafts in the aortic bifurcation and in the proximal LRA (Fig. 3c, arrow).

Comments

Isolated aneurysms in the iliac arteries are uncommon and may lead to peripheral artery insufficiency in the lower limbs. Appropriate candidate selection, for endovascular or surgical therapy, greatly relies on imaging classifications. Runoff CTA is usually performed. And DE allows automatic bone removal, as well as significant enhancement of vascular details using "*syngo*. CT DE Monoenergetic Plus". However, if the peripheral arteries in the lower limbs are not well shown in DE CTA images, such as in this case, a critical question can be raised – does this indicate peripheral artery insufficiency or missing the bolus? Dynamic 4D CTA is performed using Adaptive 4D Spiral scanning to acquire images at multiple time points with defined intervals. This makes wrong bolus timing highly unlikely. Peripheral arteries are clearly demonstrated using the fused temporal maximum intensity projections (tMIP), which improves diagnostic confidence and helps the physicians making an appropriate treatment plan. ●

4 A comparison of inverted MIP images (at the same windowing) derived from mixed image (Fig. 4a), mono+50 keV image (Fig. 4b) and dynamic CTA image (Fig. 4c). The peripheral arteries in the lower limbs are best shown in the dynamic 4D CTA, confirming a severe stenosis in the RPTA (arrow).

The outcomes by Siemens Healthineers customers described herein are based on results that were achieved in the customer's unique setting. Since there is no "typical" hospital and many variables exist (e.g., hospital size, case mix, level of IT adoption), there can be no guarantee that other customers will achieve the same results.

In clinical practice, the use of ADMIRE may reduce CT patient dose depending on the clinical task, patient size, anatomical location, and clinical practice. A consultation with a radiologist and a physicist should be made to determine the appropriate dose to obtain diagnostic image quality for the particular clinical task.