Whitepaper

CERIM:
Delivering comprehensive breast imaging
with 3D breast ultrasound

Located at the heart of the medical district in the city of Buenos Aires, the CERIM was founded in 1972.

It is a pioneer institution dedicated to comprehensive women's health diagnostic imaging.

SIEMENS Healthineers

The facility and staff

A dedicated diagnostic center for women, CERIM is a state-of-the-art facility, equipped with the most advanced cutting edge technologies. It has 7 digital mammography machines, 5 of them with tomosynthesis (DBT- digital breast tomosynthesis), 8 rooms dedicated to traditional hand-held 2D breast ultrasound, 5 3D automated ultrasound systems (ACUSON S2000™ Automated Breast Volume Scanner (ABVS), Siemens Healthineers), 2 rooms dedicated to biopsy with ultrasound guidance, 2 prone biopsy machines with guidance of tomosynthesis (the first in Latin America as per Dr. Lehrer), and a 1.5T MRI. In addition, 4 general ultrasound systems, 3 bone densitometers and a clinical analysis laboratory.

CERIM holds both national and international prestige. In addition to clinical services, the center is also actively engaged in research and regularly publishes in reputed journals such as JAMA, Journal of the National Cancer Institute, Radiology and AJR. It was the only institution outside North America that participated in the ground breaking screening study of mammography and ultrasound in patients with increased risk (ACRIN 6666).

The center is led by Dr. Daniel Lehrer who has extensive training and experience in breast imaging. He studied medicine at the Universidad de Buenos Aires (UBA) and then completed his training in Radiology at Buenos Aires (Sanatorio Guemes).

He also attended breast courses by Dr. Lazlo Tabar and participated in advanced training at Memorial Sloan Kettering Cancer Center, New York, USA. Dr. Lehrer is a recipient of ACRIN Fellowship (2003-2005) and a Certificate of Outstanding Contribution of ACRIN (2006).

Dr. Lehrer is supported by 18 radiologists and 28 technologists in addition to 6 infrastructure personnel and IT support staff. Being a center of excellence in the region, CERIM receives patients from all over the country and sometimes even from the neighboring countries of Uruguay, Paraguay and Bolivia. Annually over 80,000 patients are seen at CERIM for a wide variety of diseases.

With a customer-centric approach to patient care, Dr. Lehrer and his team strive to provide timely and friendly service to all patients. It is no wonder that the patient volume continues to grow year over year.

Team of doctors who regularly use ACUSON S2000 ABVS. Dr. Lehrer sitting left most, in the back row

ACUSON S2000 ABVS ultrasound technologist team

Genesis of implementing 3D automated volume ultrasound program

CERIM was one of the first centers to incorporate digital mammography in Argentina in 2008 and the first to offer tomosynthesis by the end of 2010 (two months before its approval by the FDA). Acquisition of the latest mammography technologies combined with high quality clinical exams generated an increased demand for mammographic studies.

As a result of the first publication of ACRIN 6666 study in 2008*, and consequently growing awareness of the value of ultrasound, there was a sustained increase in the demand for breast ultrasound in conjunction with mammography. The growth of both mammography and ultrasound practices was symmetrical until mid-2012. However, digital mammography and tomosynthesis required a greater amount of medical resources, especially the latter. Tomosysnthesis interpretation demands reading times twice as long as mammography. Though this led to the growth of the imaging guided biopsies, it also caused a delay in ultrasound examination as the organization did not have enough trained doctors able to perform breast ultrasound. In addition, it was not easy to find good breast sonographers and their training took a long time (in Argentina, ultrasounds are performed by doctors).

These dynamics led to a decrease in CERIM's offer of ultrasound in 2013, which caused two problems:

- A drop in the number of mammograms, as they could not meet the combined orders for mammography and ultrasound.
- A delay of more than two months with complaints from the patients and their referring physicians who were forced to wait.

Dr. Lehrer and his team realized something had to be done promptly to solve these problems.

CERIM actively started exploring new options and came to know about automated breast ultrasound in the market. After careful consideration of many products, they finalized the purchase of the ACUSON S2000 ABVS from Siemens Healthineers, first in Argentina. The main reason for selecting the ACUSON S2000 ABVS was its ability to perform 2D and 3D in a single system and a flexible reading software, *syngo*®.Ultrasound Breast Analysis (sUSBA).

* Berg WA, Blume JD, Cormack JB, Mendelson EB, Lehrer D, Böhm-Vélez M, Pisano ED, Jong RA, Evans WP, Morton MJ, Mahoney MC, Larsen LH, Barr RG, Farria DM, Marques HS, Boparai K; ACRIN 6666 Investigators.
Combined screening with ultrasound and mammography vs mammography alone in women at elevated risk of breast cancer.
JAMA. 2008 May 14;299(18):2151-63.

Getting started with automated breast ultrasound

Though it was exciting to get the automated system, the initial implementation of ACUSON S2000 ABVS was not straightforward. It was a disruptive technology which required a complete change to the existing workflow. The application specialist who assisted with the equipment installation did a very good job training the technologists, and within a few days they began performing real patient studies. However, it was not enough by itself for the doctors, who had excellent training and experience primarily in 2D hand-held ultrasound only.

The implementation of 3D volumetric breast imaging led to a big disconnect regarding 2D and 3D and an ensuing dilemma emerged. The staff questioned what the ideal workflow would be:

- **Can they successfully implement 3D volumetric ultrasound in their clinic?**
- **Do they feel comfortable using this new technology confidently, as the doctors were used to 2D hand-held ultrasound?**

They attempted many different strategies to try and resolve this. For example, 3D ultrasound was performed on the same patients who had 2D hand-held ultrasound and vice versa. To increase comfort level with the new technology, 3D ultrasound was performed on patients who were scheduled for ultrasound guided biopsies that same day. Even with all this training and experimentation, the physicians still did not feel confident enough to start reporting patients who had 3D ultrasound only.

Finally, after the visit by Dr. Liana Falcon from Peru, who shared her experiences with the method and gave some critical advice, the team's expectation was reset. The main insight was that in combination to the transverse view, the coronal plane provided an additional comprehensive view to improve the diagnosis. Co-relating different views provided more information and helped enhance the doctors' confidence. Once this understanding was realized, the adoption suddenly became easier among the physicians.

ACUSON S2000 Automated Breast Volume Scanner (ABVS)

Dr. María Kruchowski

"The Coronal plane is the star of the method. It allows easy identification of lesions, architectural distortions, ductal extensions, and lesion multifocality/multicentricity."

"Although the method requires a high level of training in 2D ultrasound, and also has a learning curve, once I learned it, I found it very reliable and allowed me to detect lesions not detected by other methods."

The workflow

The center started this new implementation in July 2014. At the beginning, all the 3D US studies were interpreted immediately as soon as they were completed, while the patient was still in the institution. The reason being, the 2D scanning could be performed on the same day if in fact it became necessary to further investigate a particular area of interest. As the patients' volume grew, the real-time reading model became more difficult. It resulted in long wait times for patients, who were obviously not pleased with the delay. So it was decided that all interpretations, unless it was essential, would be performed in a deferred manner (batch reading). This model implementation brought more efficiency.

A recall was considered if a patient, after getting an ABVS scan, must return for a 2D hand-held ultrasound to complement the study. With ABVS implementation, initially the recall rate was up to 25% but as the physicians became more confident and also adopted the batch reading model, recall rate started to decline to less than 10% and is now close to 5%.

The main use of the ACUSON S2000 ABVS was in the early detection of breast cancer, so the ABVS study was always accompanied by a mammogram performed the same day or shortly before.

Initially this methodology was only available to asymptomatic patients, without previous surgical intervention and with a mammogram BI-RADS©** 1 or 2, and high mammographic density (fibro-glandular tissue ≥ 50%, BI-RADS©** C or D). Later, patients with previous studies BI-RADS©** classification: 3, breast implants and with previous benign surgery history, (who do not have post-operative contact defects for the support of the transducer in the scar) were also included.

In general, diagnostic studies were less frequent and included patients with clinical symptoms, referrals with studies from other institutions, and staging of multi-centric / multi-focal lesions. However, MRI was preferred for staging of multi-centric / multi-focal lesions.

Automated 3D volumetric acquisition using ACUSON S2000 ABVS

How challenges created new opportunities for efficiency

The new method helped volume grow rapidly, especially since the wait time for a 2D hand-held ultrasound was two months. In order to meet the increasing demand, CERIM decided to purchase four more ACUSON S2000 ABVS systems, two in 2015 and two in 2016.

This allowed them to increase their capacity to perform 18% more sonographic studies per day (144 studies per day in 2013 to 170 studies per day in 2017) and 8% more mammographic studies (176 studies per day in 2013 to 190 studies per day in 2017).

While the clinic was running in full swing, approximately 18 months after the successful implementation of the 3D ultrasound program, a new bottleneck arose. The main doctor, who reviewed and reported half of the 3D US studies, was in the sixth month of her twin pregnancy and was prescribed complete bed rest. This created concern for the timely reporting of the cases and maintaining the quality of service CERIM promised to its referring doctors and patients. In light of this situation, the system managers (IT) converted the challenge into an opportunity by implementing a remote automated ultrasound reporting system, which allowed the doctor to continue reading from her home as she neared her delivery date. Subsequently, this form of remote reading was adopted by other professionals, allowing the freedom to read studies from home and / or at a time when CERIM was closed. This was an additional advantage, and unthinkable when the idea was first conceived.

For the institution, automated ultrasound represented the possibility of increasing the quantity of sonographic studies, with timely and more confident reporting. For example, most of the doctors were women with children of school age and it was very difficult to offer 2D hand-held ultrasound exams after 4:00 PM. With automated breast ultrasound, the center could now schedule 3D ultrasound studies at a time when they have scarce or no physician staff available for hand-held ultrasound examinations. This was a significant quality improvement for the center, increasing productivity, service and customer satisfaction. In addition, for the physicians who performed the inter pretation of the studies, the flexibility represented a huge value both professionally and personally.

Remote reading offered great advantages and flexibility. The studies could be reviewed and reported whenever and wherever it best suited the physicians schedule. For example: if needed, a doctor could read from New York while on a pleasure trip.

The time required for the study interpretation was variable. Depending on the difficulty of the case and the professional's experience (direct relationship with the number of studies performed), it was always less than the time required to do the 2D hand-held and then dictate the finding. The 3D automated ultrasound helped patients to get the comprehensive exam done in a short amount of time. It also saved the staff time with less patient anxiety and less questions about the findings.

With the implementation of many advanced technologies including 3D US (ACUSON S2000 ABVS) from Siemens Healthineers, CERIM was able to create a competitive edge and has been serving its referring doctors and patients with world class quality, commitment and pride.

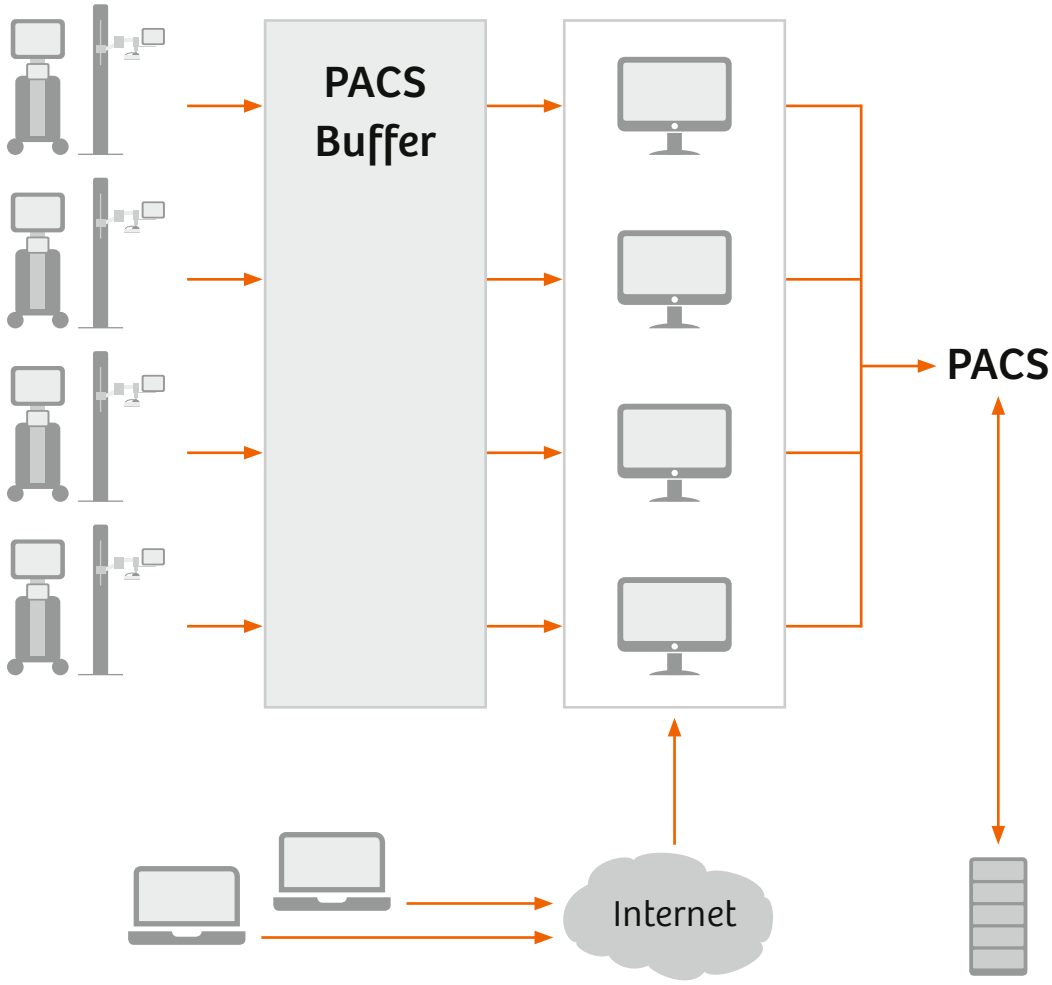

Topography of the remote connection network

Multiple systems were set-up for remote reading through use of a PACS buffer and enabled efficient batch reading remotely. By using this approach, physicians could access the sUSBA workstations from remote locations (home, hotel) with all the tools available, just as if they were doing the reporting within CERIM facility.

Advantages of 3D ultrasound

3D ultrasound is not operator dependent and the presence of the physician is not necessary to acquire the images. 3D imaging allows convenient reading and reporting of the exams.

Also this gives the chance of batch reading which is highly convenient for the professionals because the patient is not watching their movements and they are not feeling the pressure of a full waiting room.

It allows working through remote access (tele-radiology) giving flexible schedules and better utilization of time.

For reporting physicians, batch reading provided increased efficiency as there was no dead time which often happens in hospital settings.

Limitations of 3D ultrasound

There are certainly great advantages for whole breast imaging with the ACUSON 2000 ABVS but still some limitations exist for example; the large ABVS transducer does not perform Doppler or image the axilla. However, other linear 2D hand-held transducers on the same system address these needs.

Though good for most breasts, ABVS is not recommended with large breasts as it may require multiple acquisitions and have drop out artifacts due to lack of contact.

Sometimes, the localization of a lesion that requires biopsy might not be exact. The compression of the breast during the image acquisition and the location of the nipple marker might not be exact depending on the view (coronal, lateral or medial) as it is placed by the operator at the time of the scan.

Case 1 (CE01):

63-year-old female with no family history. She was requested to do mammography and ultrasound because she had heterogeneously dense breasts. A superficial mass was detected in the outer part of the right breast in mammography. Comparison with a previous exam showed increased size.

- **3D-US Right Breast:** A small, irregular, non -parallel, hypoechoic, with posterior shadowing mass was detected at 10:00 o'clock, 7 cm from the nipple. The lesion was well seen in all three planes (AP,LAT, MED). BI-RADS(R)**: 4.
- **2D hand-held** ultrasound confirmed the ABVS finding. Color Doppler showed a vessel at the periphery of the lesion.
- **Conclusion:** Right breast suspicious mass. Ultrasound core biopsy: Invasive ductal carcinoma.

Mammography detected an increase in size in the superficial lesion but was unable to differentiate it from an intramammary lymph node. According to Dr. Lehrer, ABVS showed something which warranted suspicion in characterization and called it suspicious initially.

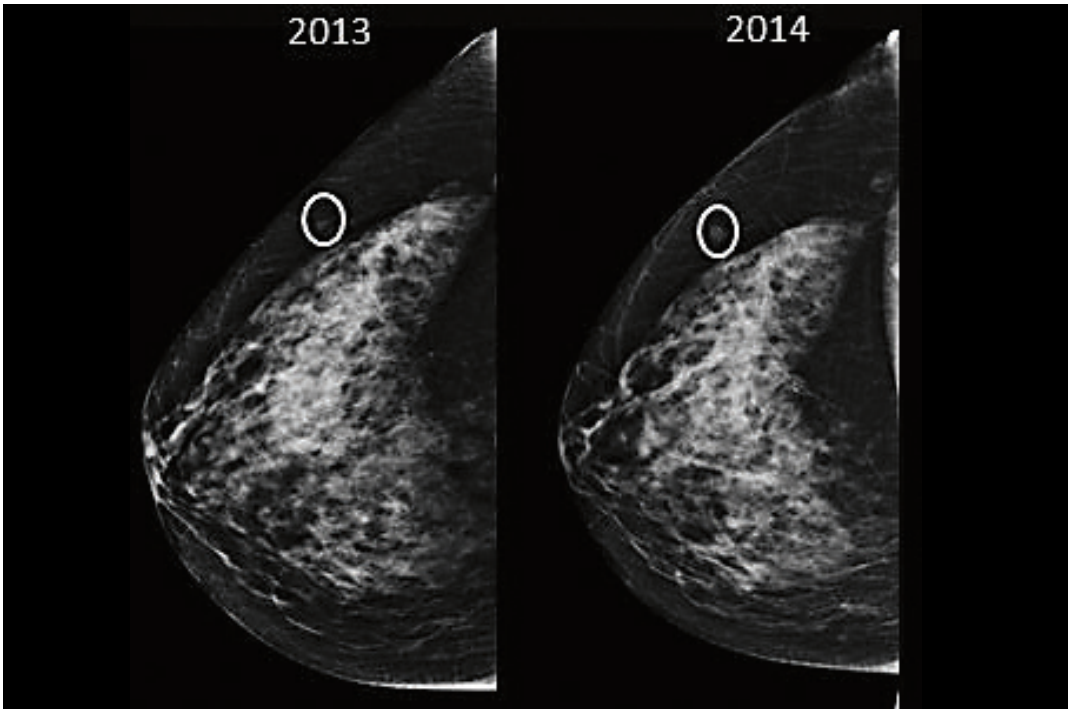

Digital mammography comparison, Right breast CC View

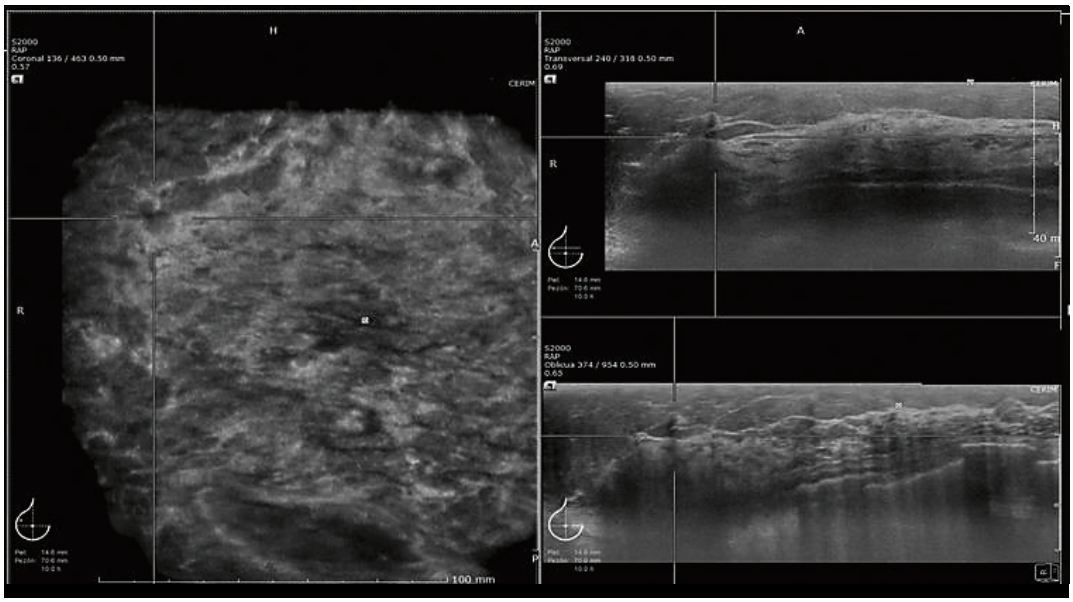

ABVS; Right breast, RAP view showing the irregular mass

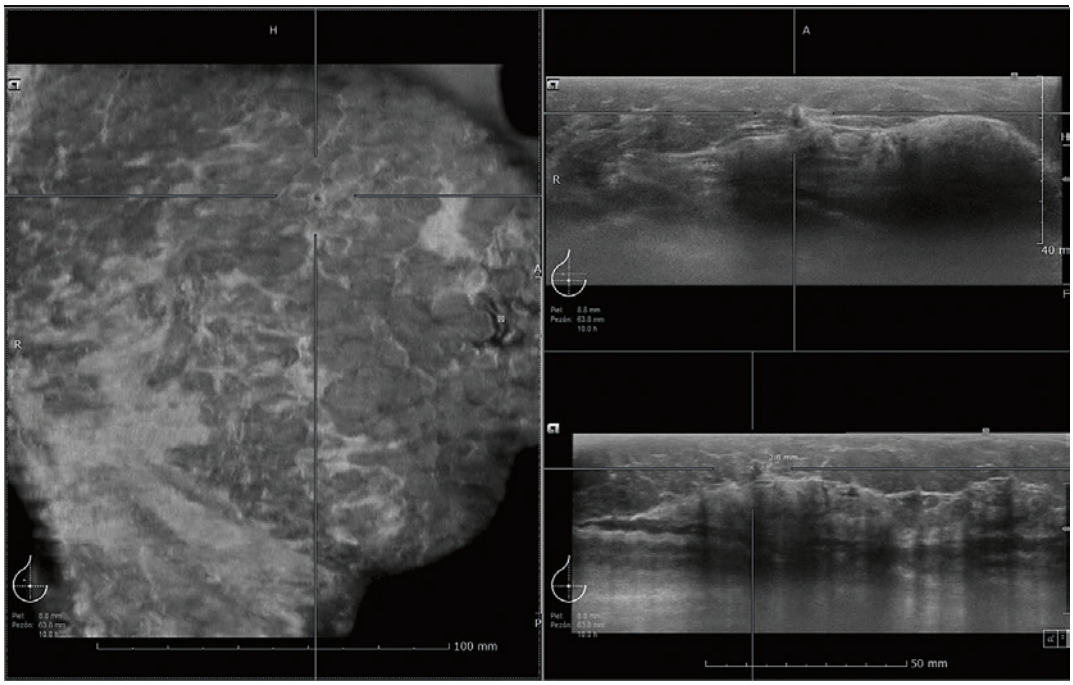

ABVS, Right breast, RLAT view showing the irregular mass

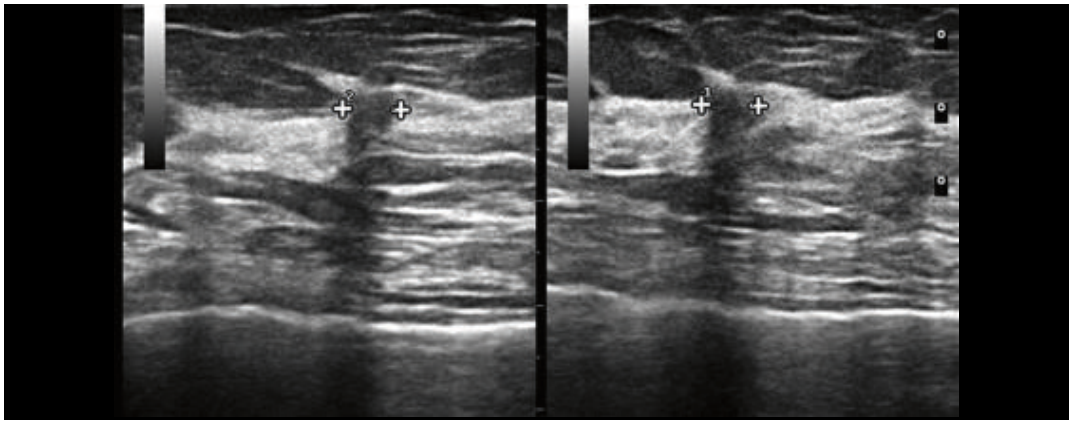

2D Hand-held ultrasound confirmed lesion detected by ABVS

Case 2 (CE03):

65-year-old female; Routine ultrasound following mammography screening; family history (mother with breast cancer) and a previous benign surgery in the right breast.

- **Digital Mammography:** Heterogeneously dense breasts. Group of microcalcifications in the upper part of the left breast at 12:00 o'clock. Magnification views suggested. BI-RADS®** classification: 0.
- **3D-US:** Right breast: Small round hypoechoic mass, with posterior shadowing and indistinct margins at 9:00 o'clock, 5 cm from the nipple. BI-RADS®** classification: 5.
- **2D-US / Mag. Tang. View:** 2D Hand-Held ultrasound confirms the presence of the mass detected with ABVS at 9:00 o' clock ,4 cm from the nipple. A mark was placed in the skin overlying the lesion and a tangential magnification mammogram was obtained that showed a small spiculated mass. BI-RADS®** classification: 5.

Magnification Left Breast: A group of amorphous microcalcifications is confirmed.

Conclusion: Right Breast, Invasive Ductal Carcinoma; Left Breast, DCIS

Note: It is a subtle, small 6 mm malignant lesion.

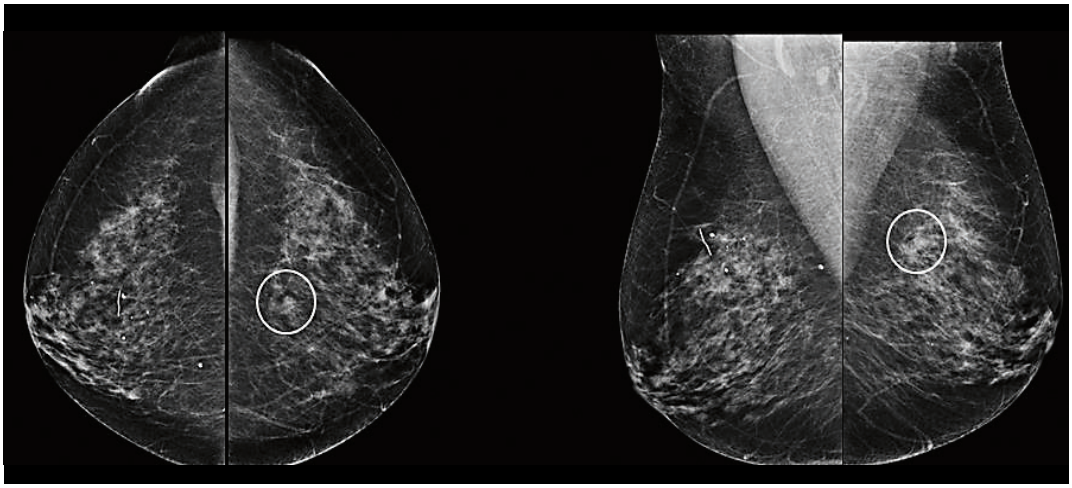

Bilateral Mammogram: Metal marker on previous benign surgery location – Right Breast

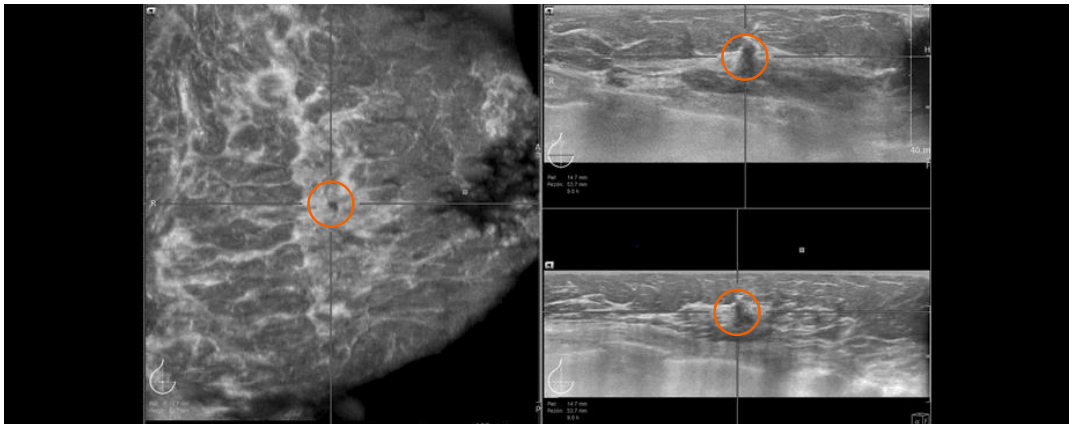

ABVS: Right breast, RLAT view showing a small round mass with indistinct margins

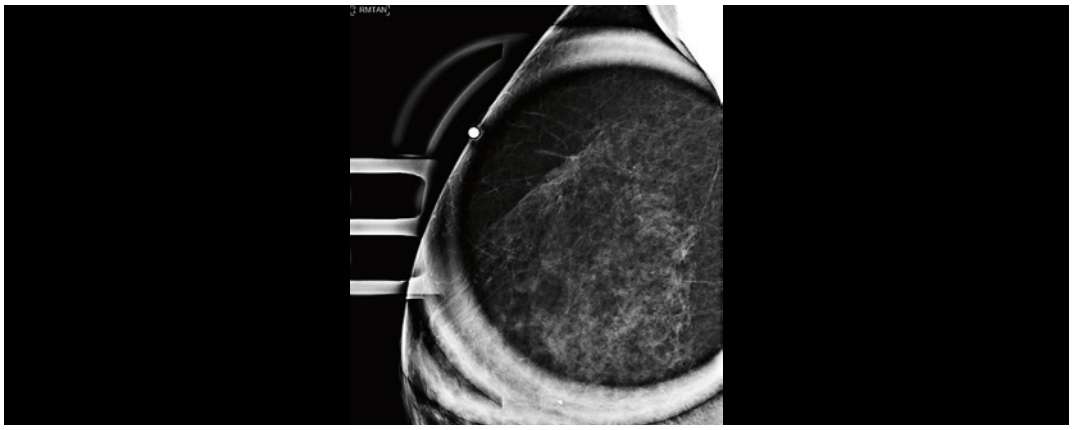

Tangential View – Right breast Post ABVS Invasive Ductal Carcinoma

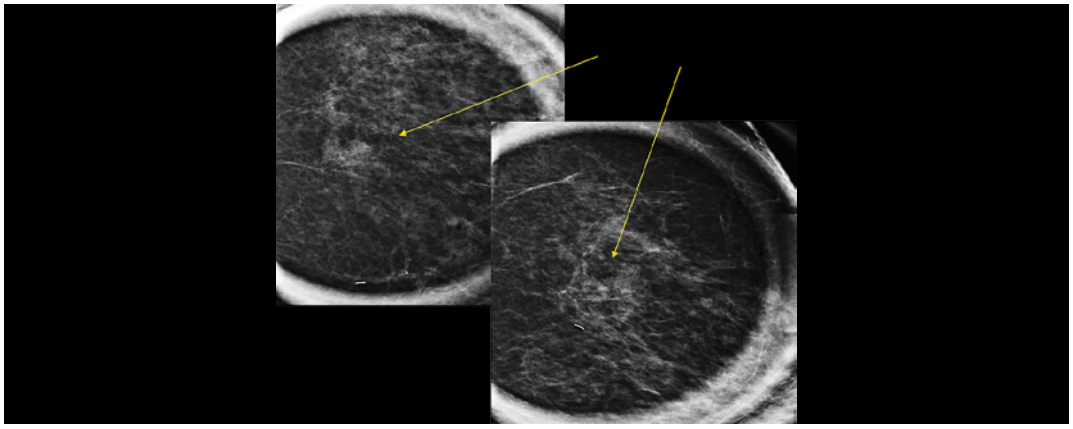

Magnification Views – Left Breast DCIS

Evolution

Early adoption of new technology requires a different mindset, especially in healthcare where changes may occur at a slower pace and stakes are high. Automated breast ultrasound is a disruptive technology which, while offering many advantages, requires changes in the workflow and image interpretation.

Driven by their patient-centric passion, Dr. Lehrer and his team demonstrated successful implementation of ACUSON S2000 ABVS in their clinic.

As with any new technology, the initial experience at CERIM was not straightforward, however, they continued to experiment and toiled with different ideas to integrate. It was an evolution which eventually radically changed their workflow and further enhanced the quality of their service both for patients and physicians.

Disclaimer

The statements by Siemens Healthineers' customers described herein are based on results that were achieved in the customer's unique setting. Since there is no "typical" hospital and many variables exist (e.g., hospital size, case mix, level of IT adoption) there can be no guarantee that other customers will achieve the same results.

The products/features mentioned in this document may not be commercially available in all countries. Due to regulatory reasons their future availability cannot be guaranteed.

Please contact your local Siemens Healthineers organization for further details.

Standalone clinical images may have been cropped to better visualize pathology.

Reference

** BI-RADS® is a registered trademark of the American College of Radiology.

Siemens Healthineers Headquarters
Siemens Healthcare GmbH
Henkestr. 127
91052 Erlangen, Germany
Phone: +49 9131 84-0
siemens-healthineers.com

Legal Manufacturer
Siemens Medical Solutions USA, Inc.
Ultrasound
22010 S.E. 51st Street
Issaquah, WA 98029, USA
Phone: 1-888-826-9702
siemens-healthineers.com/ultrasound

Published by Siemens Medical Solutions USA, Inc. · Order No. A91US-542-1C-4A00 · Printed in Germany · 11669 05182.