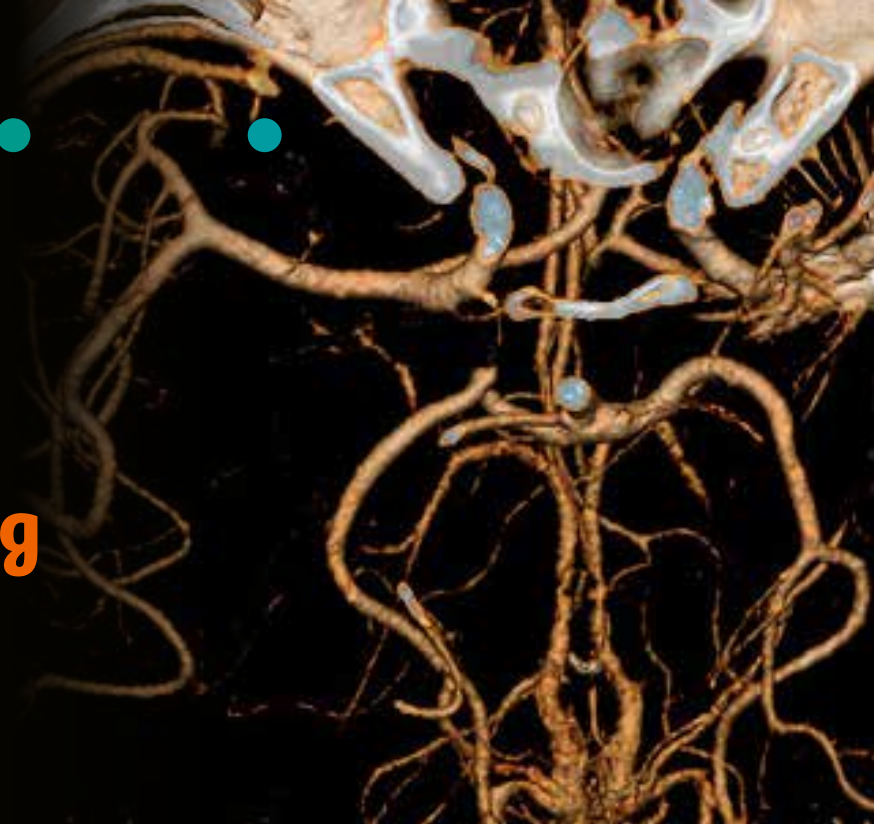

## Study Protocol

# Follow-up after stent-assisted aneurysm coiling

Interventional Neuroradiology

We were able to obtain accurate visualization of the parent vessel and verify occlusion of this aneurysm and patency of the stent.

---

### Courtesy of

Kiffon Keigher, APN,  
Demetrius K. Lopes, MD,  
Rush University Medical Center,  
Chicago, USA

### Supported by

*syngo* DynaCT

### System & Software

Artis zee biplane VC21  
*syngo* X Workplace VB21

---

## Case Description

### Patient history

73-year-old female patient. Left middle cerebral artery (MCA) aneurysm that was treated with stent-assisted coil embolization in 2005. Because of her history of contrast allergies, we decided to complete a *syngo* DynaCT run with IV injection of contrast medium in the angiography suite for the purpose of improved visualization and monitoring the patient post IV injection.

### Diagnosis

In 3D rotational angiography we identified that the left MCA aneurysm was completely occluded, status post stenting and coiling. We were able to obtain accurate visualization of the parent vessel and verify occlusion of this aneurysm and patency of the stent. There was no evidence of in-stent stenosis.

### Treatment

The quality of the study was very good, with no evidence of any other abnormalities in the circle of Willis. She tolerated this imaging study without incident and was discharged home. Our plan will be to follow up with this patient in 12 months with repeated imaging study.

### General comments

At our institution we are using *syngo* DynaCT runs with IV injection routinely for patients with the following concerns: stent patency, in-stent stenosis, residual filling of aneurysms s/p clipping and/or coiling, and vasospasm.

## Follow-up after stent-assisted aneurysm coiling

Acquisition protocol	20sDCT Head 109kV	
<b>Injection protocol</b>		
Catheter position	IV injection antecubital vein (18 G) allergy prep medication	
Contrast medium (CM)	370 mg iodine/mL	
Dilution	No	
Injection volume	80 mL	
Injection rate	4 mL/s	
Duration of injection	20 s	
X-ray delay	14 s	
Power injector used	Yes	
<b>Reconstructions</b>	<b>Primary</b>	<b>Secondary</b>
Name	DynaCT Head Nat Fill HU	DynaCT DSA Dual Head
VOI size	Full	Small
Slice matrix	512 × 512	512 × 512
Kernel type	HU	HU
Image characteristics	Normal	Normal
Reconstruction mode	Nat fill	Nat fill
Viewing preset	DynaCT Head	DynaCT Head

## Clinical Images

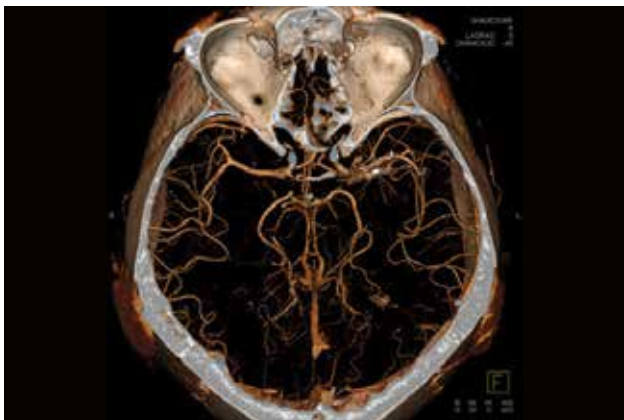


Figure 1: VRT (Volume Rendering Technique) of syngo DynaCT run with IV injection, visualizing the X stent

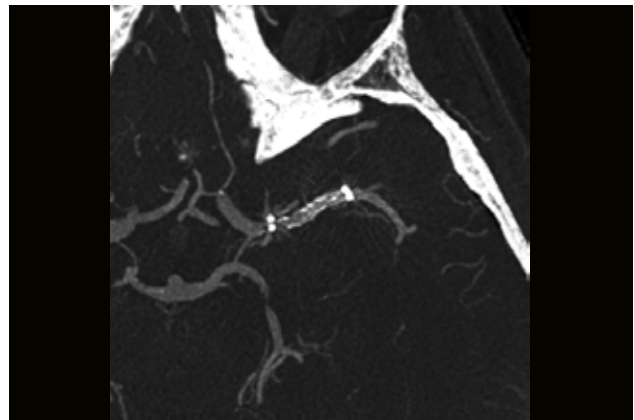


Figure 2: Axial MPR reconstruction outlining full patency of the X stent in the left middle cerebral artery (with secondary reconstruction)

## Clinical Images

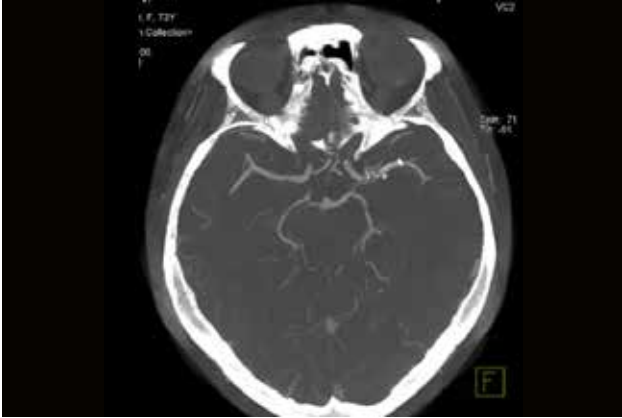

Figure 3: Axial MPR reconstruction showing X stent in the left middle cerebral artery

---

**Siemens Healthineers Headquarters**  
Siemens Healthcare GmbH  
Henkestr. 127  
91052 Erlangen, Germany  
Phone: +49 9131 84-0  
siemens-healthineers.com

*The statements by Siemens' customers presented here are based on results that were achieved in the customer's unique setting. Since there is no "typical" hospital and many variables exist (e.g., hospital size, case mix, level of IT adoption), there can be no guarantee that other customers will achieve the same results.*

*On account of certain regional limitations of sales rights and service availability, we cannot guarantee that all products included in this case are available throughout the Siemens sales organization worldwide.*

*All rights reserved.*