Study Protocol

Transarterial thoracic chemotherapy using *syngo* Dyna3D HighSpeed

Interventional Oncology

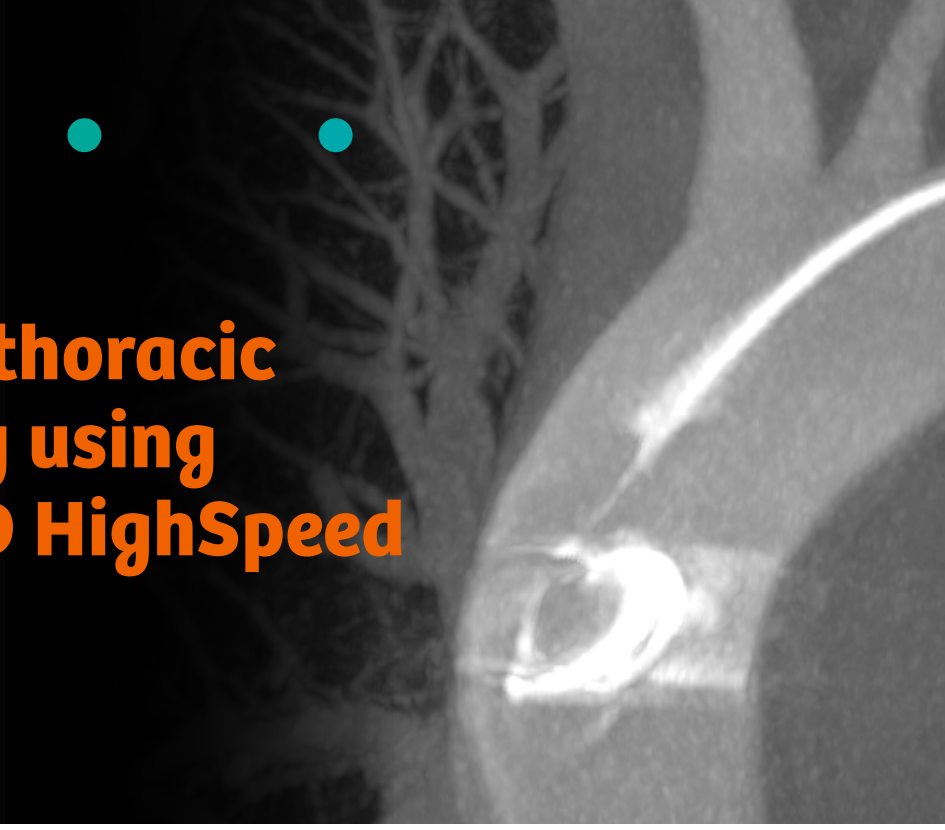

The very short acquisition time of less than 3 s with *syngo* Dyna3D HighSpeed allows acquiring 3D datasets without breathing motion artifacts even in very sick patients.

Courtesy of
Prof. Thomas J. Vogl,
PD Dr. Stefan Zangos,
Department of Radiology,
University of Frankfurt,
Germany

Supported by
syngo Dyna3D HighSpeed

System & Software
Artis zeego VC21
syngo X Workplace VB21
(Prototype software)

Case Description

Patient history
61-year-old female.
Adenocarcinoma of the lung, recurrent tumor after surgery, radiation therapy and systemic chemotherapy. Actual third line therapy protocol.

Diagnosis
No systemic metastases, local intrapulmonary infiltration.

Treatment
Transarterial thoracic chemotherapy with a mix of Mitomycin, Gemcitabine and Cisplatin injected in the ascending aorta performed after using the *syngo* Dyna3D HighSpeed protocol.

General comments
The very short acquisition time of less than 3 s makes it possible to acquire 3D datasets without breathing motion artifacts even in very sick patients.

syngo Dyna3D HighSpeed allowed performing the 3D acquisition with only 25 mL of contrast and helped to save nearly 30 % contrast media compared to a regular 5 s protocol. (A regular 5 s protocol would have required a 7 s injection protocol, resulting in a total volume of 105 mL with 35 mL of contrast).

SIEMENS Healthineers

Transarterial thoracic chemotherapy

Acquisition protocol	3sDR HighSpeed

Injection protocol	
Catheter position	Ascending aorta
Contrast medium (CM)	350 mg iodine/mL
Dilution (CM/Saline):	33 %
Injection volume	75 mL
Injection rate	15 mL/s
Duration of injection	5 s
X-ray delay	2 s
Power injector used	Yes

Reconstructions	Primary
Name	DynaCT Body Nat Fill HU
VOI size	Full
Slice matrix	512 × 512
Kernel type	HU
Image characteristics	Normal
Reconstruction mode	Nat fill
Viewing preset	DynaCT Body

Clinical Images

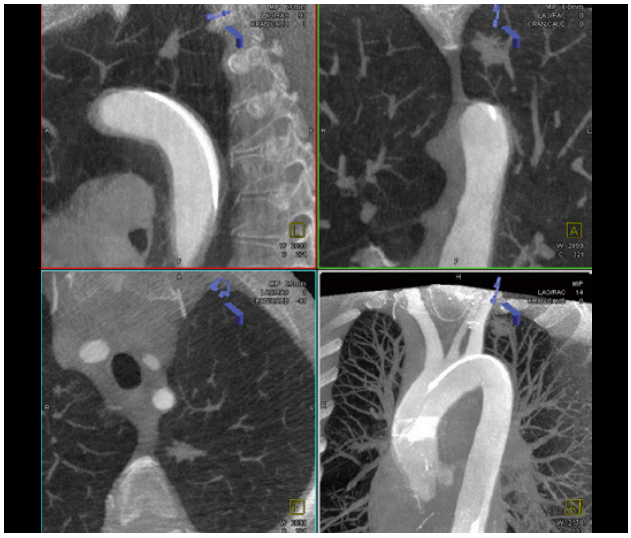

Figure 1: MIP 6 mm
The presented images show very good and sharp delineation of pulmonary arteries and their small branches

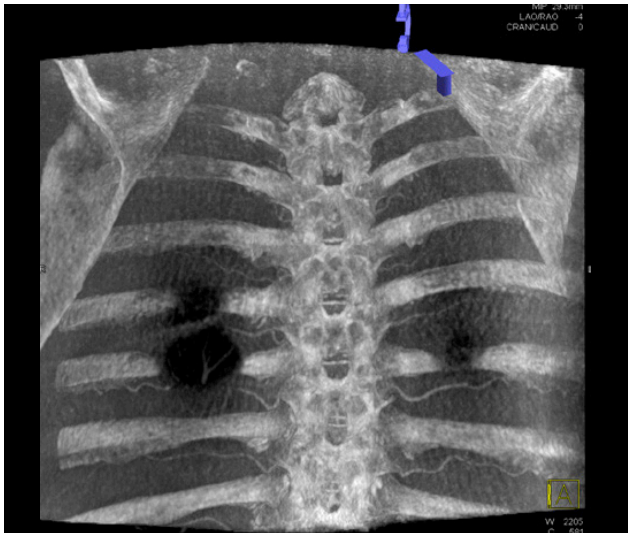

Figure 2: Coronar MIP 29 mm
Visualization of intercostal arteries (white arrow)

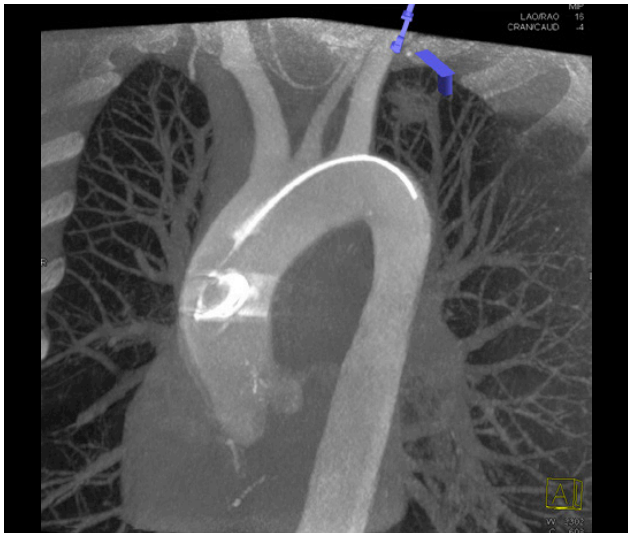

Figure 3: Thick MIP
Visualization of pulmonary arteries with the tumor

Siemens Healthineers Headquarters
Siemens Healthcare GmbH
Henkestr. 127
91052 Erlangen, Germany
Phone: +49 9131 84-0
siemens-healthineers.com

The statements by Siemens' customers presented here are based on results that were achieved in the customer's unique setting. Since there is no "typical" hospital and many variables exist (e.g., hospital size, case mix, level of IT adoption), there can be no guarantee that other customers will achieve the same results.

On account of certain regional limitations of sales rights and service availability, we cannot guarantee that all products included in this case are available throughout the Siemens sales organization worldwide.

Published by Siemens Healthcare GmbH · AT 4672-06 0720 digital · ©Siemens Healthcare GmbH, 2020