Breast MRI on 1.5T MAGNETOM Sola

Sindre Øverstad

Department of Radiology, Radiumhospitalet, Oslo University Hospital, Oslo, Norway

The .exar1 protocol is available for download at:
www.siemens.com/magnetom-world
> Clinical Corner > Protocols > Breast MRI

Introduction

Creating an MRI-protocol always involves a compromise between image resolution, image contrast, signal-to-noise ratio (SNR), and scan time. MRI of the breasts can be a somewhat uncomfortable procedure. Proper use of support cushions and head rest is helpful, but it still needs to be done in prone position. This gives limitations to the total examination time to prevent motion artifacts due to patient discomfort. MAGNETOM Sola unlashes advanced acceleration- and imaging techniques at 1.5T that can be combined to shorten scan time and improve the image quality. Using the combination of the 18-channel Breast coil and the 18-channel Body coil, we have developed a multiparametric breast MRI protocol requiring approximately 15 minutes scan time (Table 1). The protocol is in accordance with current state-of-the art technical requirements for the three main indications: screening, staging, and treatment evaluation of breast cancer [1, 2].

Patient setup and preparation

The patient is positioned on the Breast 18 coil in prone position. We also use the Body 18 coil on the back of the patient in order to increase the signal received from the axilla and sternum. The light weight of the Body 18 coil (1.6 kg / 3.5 lbs. including cable) provides insignificant added discomfort to the patient, and the straps used to fixate the coil are used to give support to the arms.

We aim to position the breasts as close to the center of the coil as possible. To fixate the breasts we use the adjustment lever on both sides of the Body 18 coil. This is done with caution, as we are very aware not to cause discomfort to the patient or alter the anatomy of the breasts.

	# slices	Slice Thickness (mm) / gap	TR	TE	TA (min:sec)	Voxel size (mm)	FOV (mm)	Matrix	Avg.	Coil(s)	iPAT
Tra T2w Dixon	84	2.0 / 0%	3080	81	5:03	0.75 x 0.83 x 2.00* 0.38 x 0.38 x 2.00**	390 x 240	468 x 320	1	Breast 18 + Body 18	GRAPPA: 2 SMS: 3
Tra DWI b0 / b800 ZOOMit^{PRO}	34	4.0 / 25%	6200	63	4:39	1.83 × 1.83 × 4.00* 0.92 × 0.92 × 4.00**	330 x 161.3	180 x 88	b0: 8 b800: 8	Breast 18	GRAPPA: 2
Tra TWIST-VIBE Dixon	80	2.0 / 20%	6.8	TE 1: 2.39 TE 2: 4.77	5:39	0.78 × 0.78 × 2.00	337.5 x 200	432 x 256	1	Breast 18 + Body 18	CAIPI: 4

Table 1: Sequence parameters for breast MRI at 1.5T MAGNETOM Sola.
**Acquired resolution*
***Interpolated resolution*

Protocol

Morphology

2D or 3D

To choose between 2D- and 3D-techniques means a choice between in-plane resolution and multiplanar reconstruction (MPR). Whereas a 3D TSE sequence (SPACE) provides superior MPR using isotropic 1 mm^3 voxels, thin 2D TSE sequences provides superior submillimeter in-plane details. MAGNETOM Sola allows for 2 mm 2D TSE slices without slice spacing (with the use of two concatenations). This enables high image details with surprisingly acceptable MPR. Our radiologists use MRP mostly for comparison with ultrasound and mammography, and prefer the better in-plane details that the 2D images provides. The new simultaneous multislice (SMS) technique enables us to cover 16.8 cm (84 slices) within comparable scan time to 3D SPACE. When SMS is applied to TSE-sequences, it yields an increase in specific absorption rate (SAR). However, we rarely exceed the limiting values operating in Normal Mode. This may be of bigger concern when scanning at 3T.

A trade-off with 2D is slightly inferior morphology of small lymph nodes when oblique oriented to the image plane.

Dixon or not Dixon

The Dixon fat-water separation technique has the advantages of specific fat images (fat-only) and robust and homogenous fat free imaging of water (water-only) in the same sequences. Thus, using Dixon enables not only superior image quality, but also reduced scan time. The fat- only images are superior to T1W for depiction of fat. The T2W water-only images are superior to frequence-selective fat sat for homogeneity and superior to STIR regarding scan time and SNR, and can be performed after the injection of Gadolinium if necessary. Because Dixon unfortunately is unavailable for 3D SPACE, we have chosen the thin interleaved 2D images (Fig. 1). For depicting blood and proteinous liquid at T1W we use the pre-contrast phase from the dynamic sequence (VIBE-Dixon) (Fig. 3A).

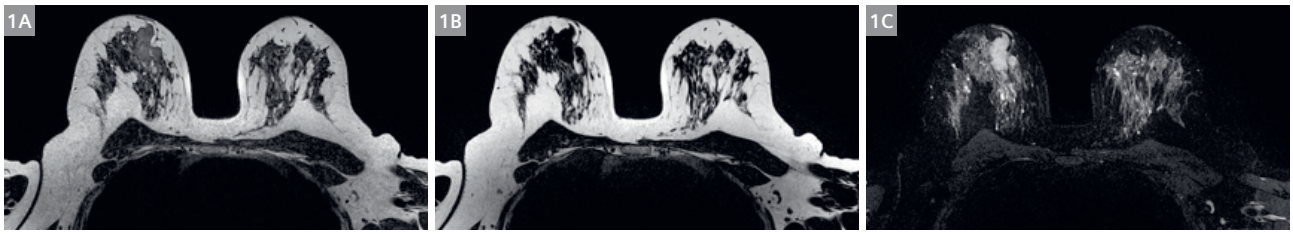

1 Transversal T2W Dixon in-phase **(1A)**, fat-only **(1B)**, and water-only **(1C)** showing a tumor in the upper medial quadrant of the right breast.

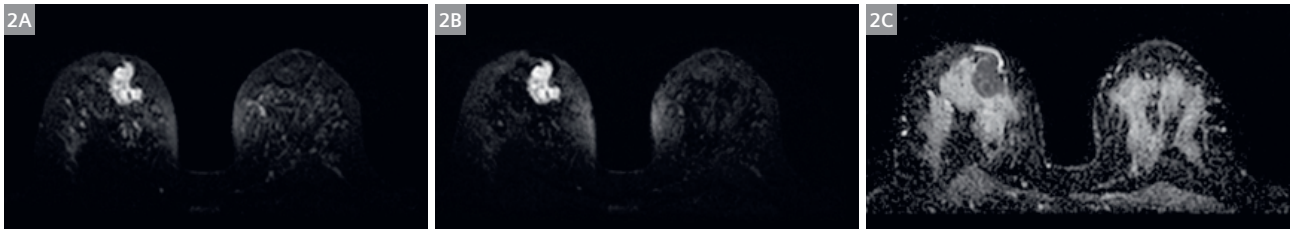

2 Transversal DWI using b800 **(2A)**, calculated b-value 1400 **(2B)**, and ADC map **(2C)** showing restricted diffusion in a tumor in the upper medial quadrant of the right breast.

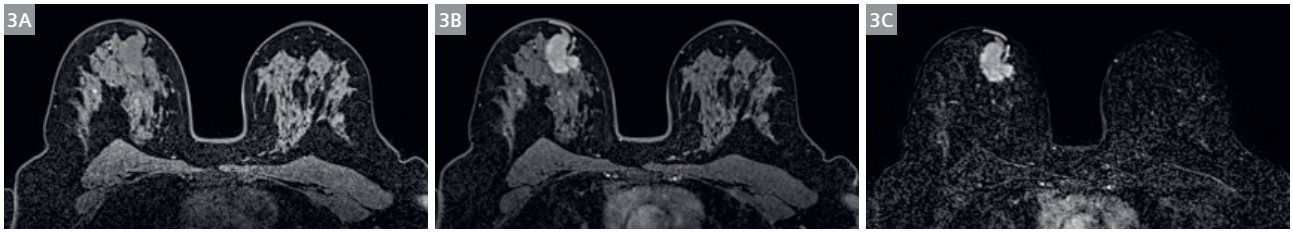

3 Transversal T1W TWIST-VIBE Dixon pre-contrast **(3A)** and first contrast phase (52 sec) **(3B)** of the breasts. Our radiologists also use the subtraction images **(3C)** routinely.

Diffusion-weighted images (DWI)

What kind of EPI?
MAGNETOM Sola offers three kinds of diffusion-weighted imaging: standard, segmented (RESOLVE), and zoomed 2D RF excitation (ZOOMit^{PRO}). We have found the ZOOMit^{PRO} sequence to be superior. This technique includes both breasts in one FOV with good fat saturation. Given equal resolution, ZOOMit^{PRO} also appears sharper. The fat saturation is not better with any of the other DWI techniques, except STIR-EPI. However, STIR is too time- and SNR-consuming for regular use. The fat suppression sometimes fails at the transition between the breast and the thoracic wall, but this area rarely contains glandular tissue. We have found that scanning each breast individually with a reduced FOV only result in an increase of scan time with no added benefit of artifact reduction. If necessary, changing to sagittal image plane and careful placing of the B_0 shim box may improve the fat saturation in a particular area.

According to a new consensus on DWI of the breasts from EUSOBI we acquire the DWI with a resolution $\leq 2 \times 2$ mm^2 in-plane and a slice thickness of 4 mm [3]. In addition, we interpolate the in-plane resolution to 0.92×0.92 mm^2. The recommended b-values are b0 and b800, and in addition we calculate a heavily DW image set of b1400. ZOOMit^{PRO} provides a nice contrast between tumor, glandular tissue, and fatty background. There is usually some remaining signal from glandular tissue at b800, but the calculated b1400 images produce a homogenous low signal background, increasing the conspicuity of tumor.

The ZOOMit^{PRO} also manages 3 mm slice thickness, but then the SNR is starting to be critical. In our experience, the quality of the ADC map is heavily dependent on the SNR. Thus, we prefer 4 mm slice thickness. We also equal the signal averaging at b0 and b800 to further improve the SNR of the ADC-map (Fig. 2).

Contact

Sindre Øverstad, BSc, RT(R) (MR) (CT)
Radiographer
Oslo universitetssykehus HF
Radiumhospitalet
Ullernchausseen 70
0379 Oslo
Norway
Tel. +47 93659267
sindre.overstad@gmail.com

Dynamic Contrast Enhanced (DCE) imaging

State-of-the-art DCE imaging in the breast emphasizes morphology over kinetics and typically uses a temporal resolution of 60–90 seconds in order to provide very high spatial resolution [2]. We have chosen the time resolved TWIST-VIBE Dixon sequence that enables very high spatial resolution producing detailed morphology even on MPR, reasonable time resolution, and high contrast to background. The use of the Dixon technique offers superior fat removal. Subtraction images are calculated in-line.
In this way the radiologists have the advantage of both interpreting the contrast enhancing abnormalities surrounded by the non-enhancing tissue (native water-only Dixon images) and differentiate enhancing structures from proteinous liquid and blood (subtraction images). Our images are done with a temporal resolution of just over 52 seconds, and the voxel size acquired is $0.78 \times 0.78 \times 2.00$ mm^3 (Fig. 3).

Ultrafast breast imaging is arising. Malign lesions enhance earlier and faster than benign lesions [2]. MAGNETOM Sola offers another acceleration technique, GRASP-VIBE, which enables ultrafast time resolution of ≤ 10 seconds and good spatial resolution. GRASP-VIBE utilizes motion insensitive radial *k*-space sampling and compressed sensing. However, even at comparable spatial resolution, the GRASP-VIBE is more blurred than the TWIST VIBE-Dixon and the image contrast is lower, possibly do to inferior fat suppression. Our breast imaging specialized radiologists prefer to use the TWIST-VIBE Dixon in clinical routine.

Acknowledgments

Thanks to radiographers Evy Storengen Nøstvold and Edmund Reitan and radiologist Knut Håkon Hole for invaluable help with developing the protocol and preparing the manuscript. Thanks to the breast imaging specialized radiologists Marit Muri Holmen and Siri Helene Bertelsen Brandal for clinical on-site considerations through the process of developing and testing of our breast imaging protocol.

References

1 Mann, R. M. et al. Breast MRI: EUSOBI recommendations for woman's information. European Radiology 25, 3669-3678 (2015).
2 Mann, R. M., Cho, N. & May, L. Breast MRI: State of the Art. Radiology 2019, 292;520-536 (2019).
3 Baltzer, P. et al. Diffusion-weighted imaging of the breast – a consensus and mission statement from EUSOBI International Breast Diffusion-Weighted Imaging working group. European Radiology 30, 1436-1450 (2019).