Clinical Case Studies

Customer experiences from the region

SIEMENS Healthineers

Disclaimer

The outcomes by Siemens Healthineers' customers described herein are based on results that were achieved in the customer's unique setting. Since there is no "typical" hospital and many variables exist (e.g. Hospital size, case mix, level of IT adoption), there can be no guarantee that other customers will achieve the same results.

Ultrasound

Molecular Imaging

Digital Health Solutions

Angiography

Mammography

Education

Magnetic Resonance Imaging

Computed Tomography

Clinical Education

New Technologies help in Rare Ultrasound Case Studies

King Faisal Specialist Hospital & Research Centre, Riyadh, Saudi Arabia
Abdulaziz Hussein Al Shawa, Senior Sonographer

Budd-Chiari syndrome

Abstract

Budd-Chiari syndrome (BCS) is associated with occlusion of hepatic venous outflow by thrombosis or structural compression at the level of the main hepatic vein or the extrahepatic segment of the inferior vena cava. Initial management of BCS is usually medical (non-operative/non-interventional), with the most common intervention for BCS not responsive to medical management being trans jugular intrahepatic portosystemic shunt (TIPSSS).

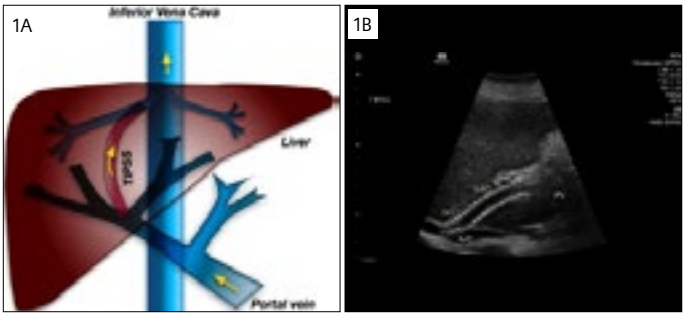

1 **Fig. 1A, 1B** - Stent after trans jugular intrahepatic portosystemic shunt (TIPSSS) procedure.

Case presentation

Patient History: A 41-year-old female presents with known case of Budd Chiari syndrome. She has had a history of intermittent abdominal pain and diarrhea for the past year, Trans jugular intrahepatic portosystemic shunt (TIPPS), done since 2019, Status Post trans jugular intrahepatic portosystemic shunt (TIPPS) to evaluate patency.

Investigations: Abdominal ultrasonographic evaluation of the liver including hepatic Doppler And TIPPS was performed.

The sonographic evaluation after TIPSS focuses on shunt patency and flow characteristics. Each stent is thoroughly assessed at its proximal (hepatic vein) end, midportion, and distal (portal vein) segment. Stents are well visualized within the liver parenchyma.

Fig. 2A - Transverse section on liver showing diffuse hepatic steatosis.

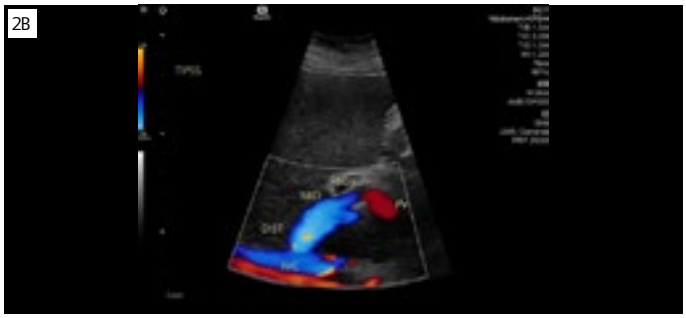

Fig. 2B - Hepatofugal flow in portal vein branches after trans jugular intrahepatic portosystemic shunt (TIPSSS) procedure.

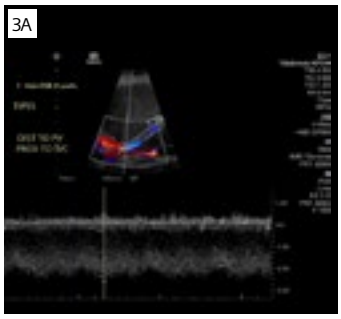

Fig. 3A - Duplex sonogram shows high-velocity flow (nearly 258 cm/sec) with mild changes with respiration. High flow velocity noted distal to portal vein and proximal to IVC.

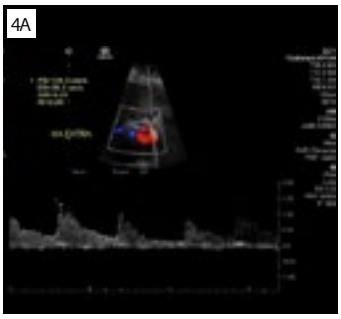

Fig. 4A -Velocity increase in hepatic artery after trans jugular intrahepatic portosystemic shunt (TIPSS).

Case 2

Internal Iliac Artery Aneurysm

Internal iliac artery aneurysms are rare and are not commonly imaged with ultrasound because most patients reporting acute symptoms are imaged primarily with computed tomography. In the case reported here, the patient presented first to the ultrasound department from the emergency department. As described in the following, sonography showed findings consistent with an iliac artery aneurysm, which prompted further emergent imaging.

Case presentation

Patient History: 3-year-old patient with bilateral iliac artery aneurysms, Kawasaki disease to check the size of aneurysms.

Investigations: The patient was referred to the ultrasound department for an aorto-iliac examination to evaluate for possible recurrence internal iliac arteries. The examination was performed on a ACUSON Sequoia ultrasound system using a 5 MHz curvilinear transducer and 10 MHZ linear Transducer. Sonography showed a normal distal aorta and bilateral internal iliac artery aneurysm with moderate size intraluminal echogenicity in keeping with partially thrombosed bilateral internal iliac artery aneurysm.

Right internal iliac aneurysm measures 4.3*3.6 cm with neck measurement of 0.6cm (Fig. 2A) and the left internal iliac artery aneurysm shows 2.7*3.3 cm with neck measurement of 0.3 cm (Fig. 2B).

Abdominal aorta and internal iliac arteries are patent throughout with normal peak systolic velocity and waveform.

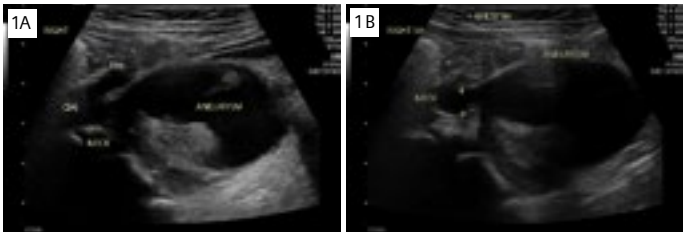

1 **Fig. 1B -** Transverse view of the right iliac region of the pelvis, caliper indicating neck measurement of complex mass/aneurysm.

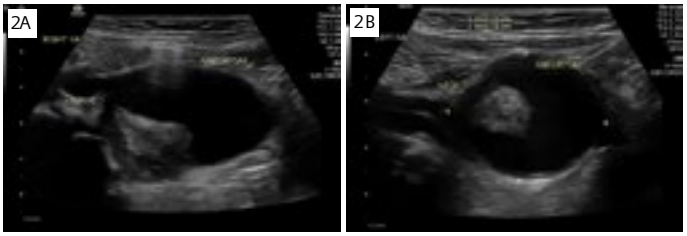

2 **Fig. 2A, 2B -** Transverse view of the Right and left iliac region.

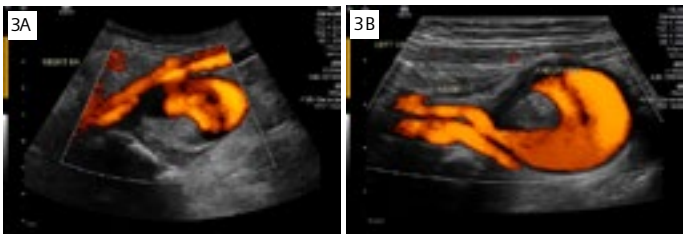

3 **Fig. 3A, 3B -** Transverse view of the right and left iliac region.

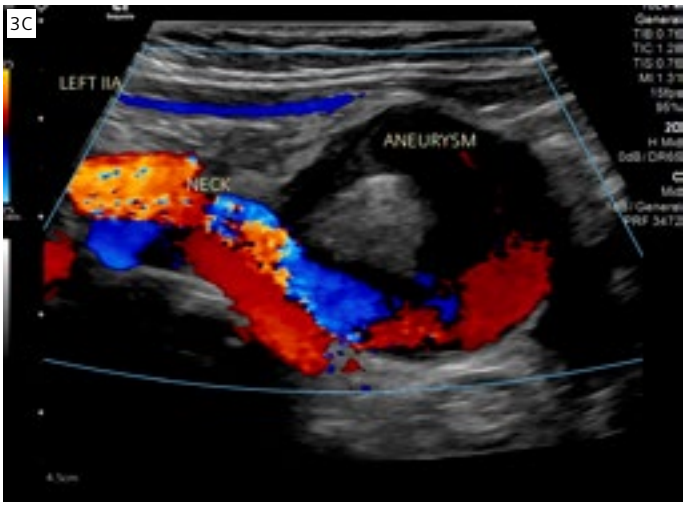

3 **Fig. 3C -** Color flow imaging of left internal iliac artery aneurysms.

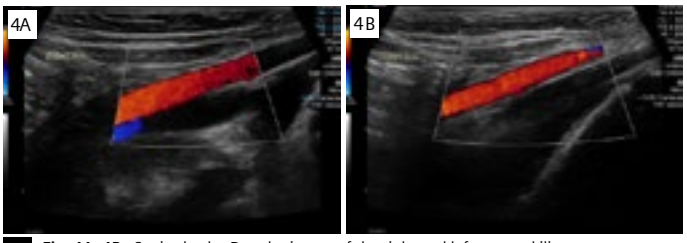

4 **Fig. 4A, 4B -** Sagittal color Doppler image of the right and left external iliac artery respectively.

Internal iliac artery aneurysms are uncommon, and they are often found only when they have become large with a high attendant risk for rupture and significant resulting mortality. Early detection of these aneurysms is important for appropriate management. Sonography is the screening modality of choice in asymptomatic patients with multiple risk factors. The relatively high incidence of coexisting iliac artery aneurysms with abdominal aortic aneurysms makes sonographic investigation of the iliac artery system essential in the assessment and treatment of high-risk patients. This case demonstrates the appearance of an internal iliac artery aneurysm in a patient difficult to evaluate on physical examination because of large body habitus with acute rupture.

ACUSON Sequoia Auto flash artifact suppression technologies

The implications of patient and transducer motion in ultrasound, are significant. Up to 40% of abdominal ultrasound scans are repeat scans. Of those, 14% require additional follow-up exams, which may cost up to 8 billion dollars in additional tests. Image quality is a foremost concern, since even modest amounts of motion may be sufficient to reduce clinical confidence, resulting in longer scan times, increased keystrokes reach, and repeat scans. All of which can impact departmental efficiency as well as patient and referring physician satisfaction.

Auto Flash Artifact Suppression eliminates the continual need to adjust sensitivity settings by automatically maintaining the best color sensitivity when little motion is detected. As motion increases, the degree of suppression automatically increases proportionally to provide an artifact-free image. Auto Flash Artifact Suppression is a Siemens Healthineers proprietary, technology that detects and prevents artifacts associated with transducer and patient motion and enhances color imaging sensitivity when no motion is detected. It is integrated into the platform architecture of the ACUSON Sequoia system and, as such, can support higher image quality and greater diagnostic certainty without adding additional steps to the clinician's workflow. Auto Flash Artifact Suppression enables the use of very low filter settings without showing motion artifacts in color Doppler.

InFocus Coherent Image Formation and Auto TEQ

InFocus coherent image formation focuses the image at all depths and exploits high beamformer output capacity, which increases image uniformity compared to prior systems. More information is harvested from the usual transmit sequence, using massive overlapping multi-beam groups rather than individual or close parallel beam lines as in conventional systems. This secondary beamforming enabled with InFocus, physics-based delay, phase, and amplitude corrections can be made across transmit events to significantly sharpen the image and improve spatial resolution beyond what is typical for a given transducer frequency.

Workflow automation with Doppler AutoTEQ reduces user interaction and improves exam consistency.

Abdulaziz Hussein Al Shawa,
Senior Sonographer,
King Faisal Specialist Hospital & Research Centre,
Riyadh, Saudi Arabia

Sinus Venosus Artial Septal Defect

Al-Nas Hospital, Cairo, Egypt
Dr. Hani Mahmoud-Elsayed MD, FESC, FASE, Director of Echocardiography Lab

Case presentation

Patient History: A 35-year-old male presented with progressive course of shortness of breath. Trans-Thoracic echocardiography (TEE) was done and revealed RT side dilation with suspicion of intracardiac shunt.

Investigations: 4D ultrasound Trans-Thoracic echocardiography (TEE) was done using Real Time Volume Color Flow imaging and Esie valve technologies with Siemens Healthineers ACUSON SC2000.

Findings:

- Stretched patent foramen ovale (PFO) with left to right shunt
- Sizable sinus venosus, atrial septal defect (ASD) with left to right shunt
- Partial anomalous pulmonary venous drainage of right upper pulmonary vein into superior vena cava
- Normal size of aortic root with normal origin of coronaries

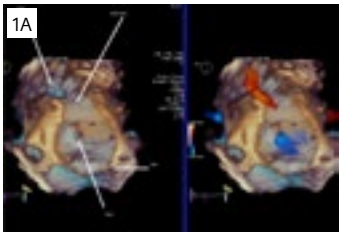

Fig. 1A - Inter atrial septum with Patent Foramen Ovale (PFO) and the superiorly situated Atrial Septum Defect Sinus Venosus Defect (ASD SVD) with the color flow.

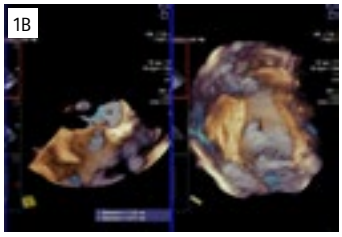

Fig. 1B - Same Projection with superior angulation evaluating the size of the defect with direct measurement on the 4 D volume, (LVOT)Left Ventricular Outflow Tract. (AO) Aorta (MV) Mitral Valve.

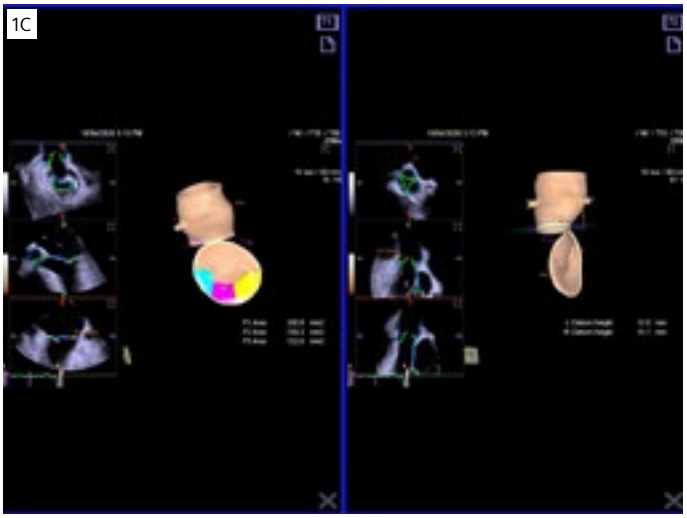

Fig. 1C - Mitral valve, Aortic valve and Ascending Ao models with measurements by SC2000 the Esie Valve application.

A unique feature of the SC2000 echocardiography system is high-resolution real-time color flow volume imaging with Artificial Intelligence operated cropping tools to help the clinician to visualize and assess structural abnormalities of the heart. The SC2000 4D imaging is characterized by high color flow volume rate without stitching. Thus, it is real time imaging.

This improves the ability of the operator to reach accurate diagnosis and assessment of the cardiac defect (Fig. 1A and Fig. 1B).

The Esie Valve application in the 4D TEE of the SC2000 can create static and dynamic mitral valve, aortic valve and ascending AO Models by the advanced artificial intelligence which enables the system to build up the model of the cardiac structure out of the recognized cardiac structure landmarks. The model is created online in few seconds with measurements of all the components of the modelled structures (Fig. 1C).

Dr. Hani Mahmoud-Elsayed MD, FESC, FASE
Director of Echocardiography Lab
Al-Nas Hospital,
Cairo, Egypt

Cancer Prostate Patient presenting with Early Biochemical Recurrence detected by 18F-PSMA-PET/CT

Misr Radiology Center, Cairo, Egypt
Dr. Yehia Omar, Director of Theranostics Unit

History

69-year-old male patient with a history of radical prostatectomy for cancer prostate from a year ago.

He is presenting now with re-elevation of PSA level reaching 0.7ng/ml.

Exam Technique:

- Patients weight: 80 Kg
- Injected Dose: 333MBq
- Time per frame: 80 sec
- Reconstruction protocol: UltraHD (PSF+TOF)
- Scanner: Biograph Horizon

18F-PSMA-PET/CT exam revealed:

- Local operative bed small (7mm) enhancing PSMA-avid nodule, denoting local recurrence.

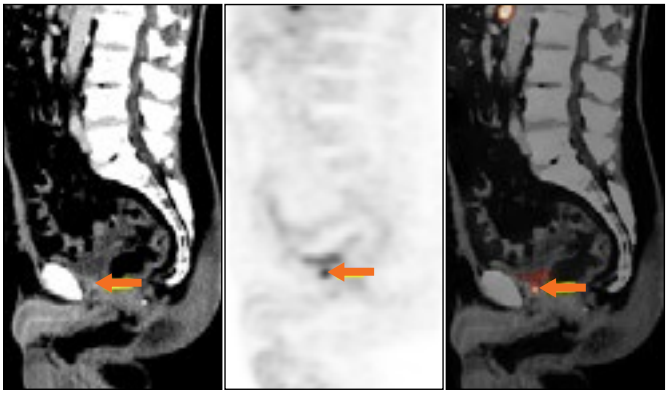

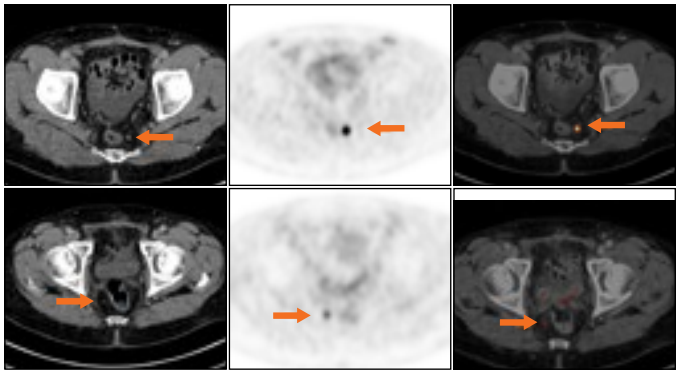

- Three sub centimetric PSMA-avid lymph nodes at peri-rectal and right obturator regions. The largest lymph node was 6 mm and the smallest lymph node measured 3.5mm.

Take home message:

- PSMA-PET/CT imaging revolutionized prostate cancer imaging with the ability to detect tiny lesions as in this case, that could not be detected by any other modality.

Dr. Yehia Omar
Director of Theranostics Unit
Misr Radiology Center,
Cairo, Egypt

Theranostics by Nuclear Medicine Technology is a new hope for Prostate Cancer Patients

King Hussein Cancer Center, Amman, Jordan
Dr. Akram Al-Ibraheem FEBNM, DCBNMC, FANMB
Dr. Ula Al-Rasheed

History

A 72-year-old male patient with a metastatic castration resistant prostate cancer (mCRPC) to bone. The patient presented with disease progression after hormonal treatment, chemotherapy and radiotherapy. He was referred to the nuclear medicine department at KHCC for potential targeted radionuclide therapy by Lutetium-177 PSMA (PRLT).

Ga68 PSMA PET/CT and F18 FDG-PET/CT were ordered for the patient to confirm his eligibility for this innovative treatment. Patient would be eligible for PRLT if his PET scan demonstrates high and sufficient expression of PSMA exceeding that of FDG expression.

Interpretation of Images

Baseline Ga68 PSMA PET/CT scan showed high expression of PSMA in the widespread skeletal metastases (Fig. 1A) that was significantly exceeding the level of FDG metabolic activity.

In addition, no metastatic deposits were identified as only FDG avid without sufficient PSMA expression throughout the whole-body PET scans. Therefore, patient was regarded as a candidate for PRLT.

Patient received two doses of PRLT (spaced 8 weeks each) and post therapy Lu-177 SPECT/CT scans showed adequate localization of the therapeutic Lu-177 PSMA radiotracer in the targeted metastatic lesions (Fig. 2).

Follow up Ga68 PSMA PET/CT scan was done after the two doses of PRLT and showed dramatic regression (almost resolution) in the PSMA expression of the widespread bone metastases. These findings were associated with significant decline in the PSA value from 179 to 1.8, as well as significant improvement in the patient's quality of life indicating excellent response to this targeted treatment.

Comments

Progressive metastatic castration-resistant prostate cancer is a highly lethal disorder and new effective therapeutic agents that improve patient outcomes are urgently needed.

Lutetium-177 [^{177}Lu]-PSMA-617, a radiolabeled small molecule, binds with high affinity to prostate- specific membrane antigen (PSMA) enabling beta particle therapy targeted to metastatic castration-resistant prostate cancer.

We aimed to investigate the safety, efficacy, and effect on quality of life of [^{177}Lu]-PSMA-617 in men with metastatic castration-resistant prostate cancer who progressed after standard treatments.

Cancer is expected to be classified by molecular phenotyping in the early future, while the organ site would be a secondary classification. Molecular phenotyping will be determined by molecular pathology and molecular imaging such as PET/CT, SPECT/CT, MRI and Optical imaging using cancer type specific probes.

Molecular imaging is a great asset for personalized medicine by in vivo characterization and early diagnosis, linking a target identification with treatment, risk assessment, therapy selection and monitoring treatment. Theranostics (Molecular endo-radiotherapy) based on molecular phenotyping is a new hope in treatment of cancer. Prostate cancer is successful current applications of theranostics. PRLT is highly effective for the treatment of mCRPC, even in advanced cases with favorable overall survival compared to available treatments. Excellent partial response with significant prolonged overall survival and symptoms control are currently achievable as we have seen in the discussed case here.

1 **Fig 1A**: Baseline Ga68 PSMA (MIP image) and **Fig 1B:** Baseline F18 FDG (MIP image) showed high expression of PSMA in the widespread skeletal metastases that was significantly exceeding the level of FDG metabolic activity. In addition, no metastatic deposits were identified as only FDG avid without sufficient PSMA expression throughout the whole-body PET scans. These images were obtained by the Biograph mCT Flow 64 PET/CT and processed on the *syngo*.via advanced visualization system with MM Oncology (Siemens Healthineers).

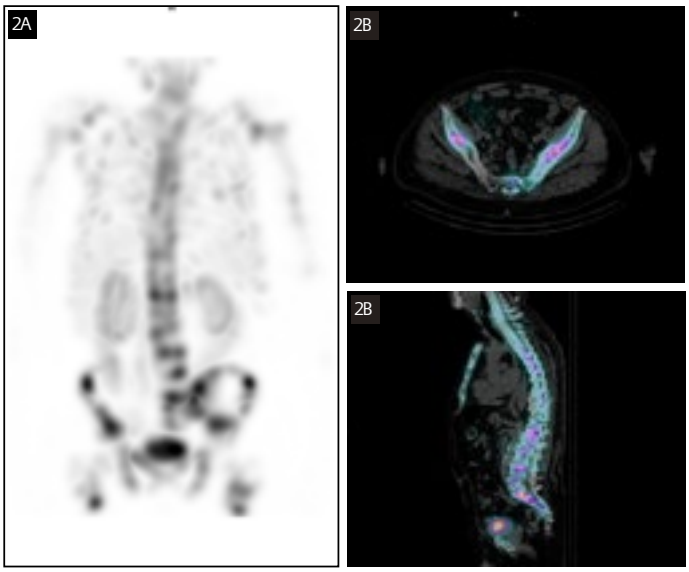

2 **Fig 2A**: 24 hours post-Lutetium-177 PSMA therapy SPECT/CT scan, A: MIP image, **Fig 2B**: axial view, C: sagittal view. These images were obtained by **Symbia Inteva Bold** 16 SPECT/CT and processed on *Syngo*.via advanced visualization system with MM Oncology (Siemens Healthineers).

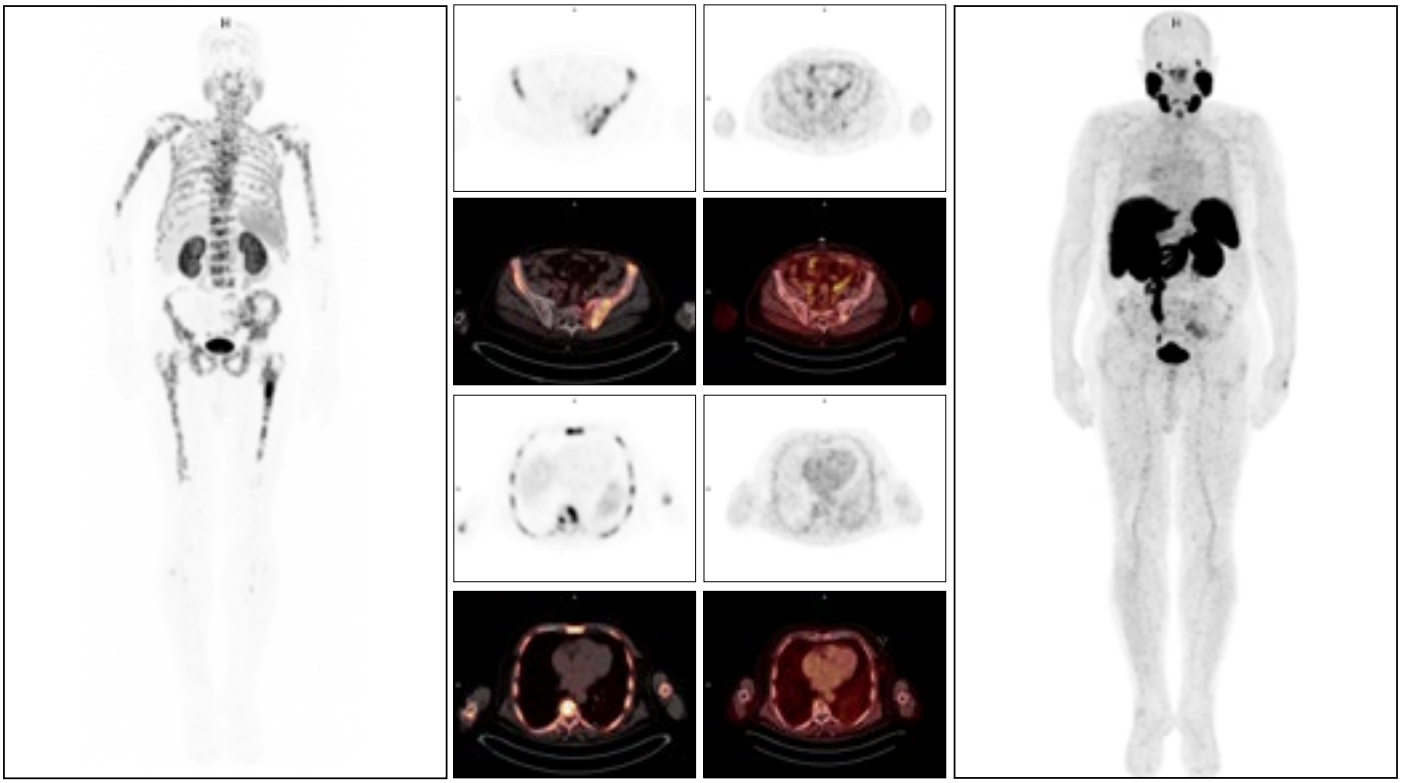

3 **Fig 3A**: Pre-therapeutic (left side) & post-therapeutic (right side) Ga68 PSMA scans showing excellent response to PRLT treatment and resolution of the widespread bone metastases. These images were obtained by the **Biograph mCT** Flow 64 PET/CT and processed on the *Syngo*.via advanced visualization system with MM Oncology (Siemens Healthineers).



Dr. Akram Al-Ibraheem,
King Hussein Cancer Center,
Amman, Jordan

Multimodality Imaging in the Cath Lab for Guidance During CTO Treatment

Arab Medical Center, Amman, Jordan
Amr Alkarmi, BSc, MD, MRCP, CCST, Consultant Interventional Cardiologist
Chief Tech. Ashraf al-holy, Manager Cath Lab Department

Abstract

Technical difficulties to find true lumen of the occluded vessel exists in CTO PCI cases. Lately, technology has enabled doctors to use the images of CT coronary angiogram in the cath lab to guide complex coronary intervention. Simultaneously, efforts to limit the volume of contrast media usage and Xray exposure time across the Cat Lab continues.

The following cases shall demonstrate how CTO guidance plays an important tool in enhancing the evaluation, planning, and treatment of a CTO vessel. Also, with CT coronary angiogram and coronary angiogram images fusion in a less complex case led to minimizing potential complication, less contrast media usage, and reduced Xray exposure time.

Case One

A 55-year-old, heavy smoker with mildly elevated cholesterol (total cholesterol 221, LDL 194) and positive family history presented to cardiac centre complaining of chest pain on exertion. His exercise tolerance is reduced to less than 500 meters on exertion. No history of diabetes or hypertension.

Coronary angiogram later showed severe subtotal occlusion in a moderate size ramus branch and total long chronic total occlusion in the RCA extending from proximal segment to the distal segment of the vessel at the level of PDA/PLV bifurcation. LM, LAD and circumflex arteries were normal.

Treatment:

PCI to ramus branch was through right radial access (RRA). The decision was to attempt RCA CTO, a second 6F femoral access to attempt RCA anterogradely and the RRA access to assess the distal vessel.

Coronary Angiography of RCA pre-PCI

Procedure was long and complicated with RCA multiple dissections and sub intimal tracking. The procedure was abandoned at that stage due to the high usage of contrast.

Patient was assessed in the clinic 3 weeks post procedure and he reported improvement but not complete resolution of symptoms. Patient was still complaining of chest with limited exercise tolerance. Clinical decision was to redo PCI to RCA.

Before performing the PCI, further assessment with CT coronary angiogram for better planning of the CTO procedure was done utilizing ***syngo* CTO Guidance** clinical software application.

Wire attempts to engage CTO track.

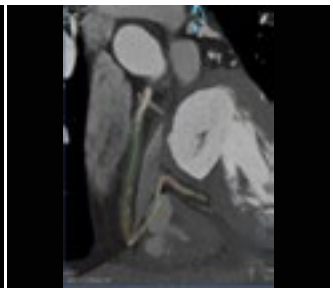

CT coronary angiogram 3D roadmap with similar projection.

PCI was attempted using right femoral artery for anterograde and left femoral artery for retrograde/ collaterals assessment with live 3d road map from CT coronary angiogram fused images to assess the occluded track of the RCA during PCI.

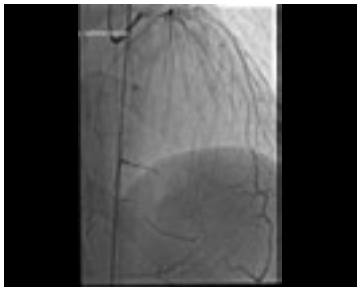

Distal wire position confirmation.

CT coronary angiogram 3D roadmap with similar projection displayed on angiography system workstation.

Final PCI results with patent right coronary artery (RCA).

Procedure was successful in a relatively short time (total procedure time 60 minutes, screening time 36 minutes) and low contrast media usage (130 milliliter). No complications reported post procedure.

Case Two

A 50-year old man presented with atypical chest pain. Risk factors for coronary artery disease include smoking 1 pack a day for 35 years and mild hypertension.

He reported reduced exercise tolerance in the last two months due to breathlessness.

Physical examination reported as normal with exception of blood pressure readings 145/85.ECG and echocardiogram were normal.

As he was atypically symptomatic, CT coronary angiogram was done, which reported mildly calcified vessels (calcium

score 58); normal LM, circumflex and right coronary artery. LAD showed significant lesion in the middle segment involving a middle size diagonal branch.

Patient was symptomatic with secondary prevention and anti-angina medications.

Coronary angiogram was performed which confirmed the findings.

Planning for PCI:

As CT angiogram images were available, the images were merged into Siemens Healthineers **Artis Q** *syngo* CTO Guidance software which automatically adds centerlines to the segmented coronary arteries from CT angiogram with color coding showing how orthogonal C-arm to the vessel segments and enabled us to overlay these segmented arteries on live fluoroscopy using 3D dynamic Roadmap throughout the procedure for guidance. This led to detect lesion anatomical landmarks with reduced contrast usage and less radiation. The approximate vessel size, length of the lesion and side branch assessment was done through the software.

Conclusion on using Siemens Healthineers *syngo* CTO Guidance software across the cath lab:

- It helps to understand the morphology of the lesion, the length of the lesion, calcifications, and tortuosity.
- Facilitates the best projection for lesions.
- Selects the right projection for better visualization of the target lesion without radiation.
- Radiation exposure is suspected to be reduced by 30-40%.
- Potentially less complications with higher success rate.
- Reduction in the X-Ray dose during the procedure.

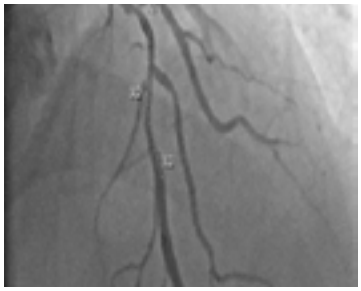

PA cranial image from cath lab.

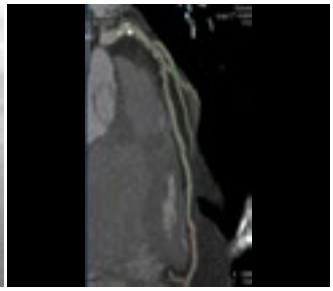

PA cranial image from CT fused through software.

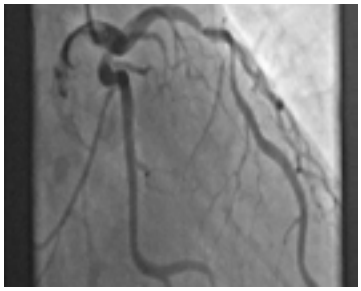

RAO cranial image from cath lab software.

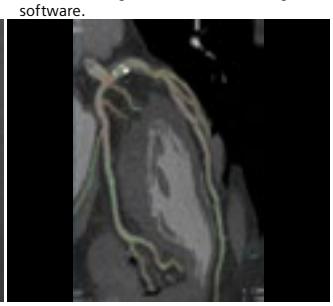

RAO cranial image from CT fused through.

Final PA cranial image from cath lab.

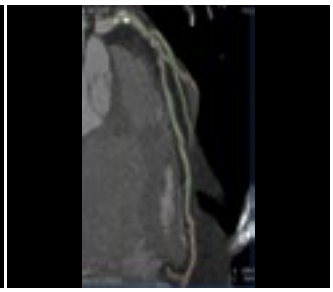

Initial PA cranial CT image on CT fused through software.

Amr Alkarmi,BSc, MD, MRCP, CCST,
Consultant Interventional Cardiologist
Arab Medical Center,
Amman, Jordan

Chief Tech. Ashraf al-holy,
Manager Cath Lab Department,
Arab Medical Center,
Amman, Jordan

Invasive Ductal Carcinoma (IDC) Clinical Management - Role Of Titanium Contrast Enhanced Mammography with 50° wide-angle

Assiut University Hospitals, Assiut University, Assiut, Egypt
Prof. Dr. Mostafa Hashem, Head of Radiology Dept. Women's Health Unit
Prof. Dr. Iman Abou El Hamd, Prof. Dr. Nagham Nabil, Prof. Dr. Gehan Sayed

Introduction

Mammary carcinoma is the most common malignant tumor in women, and it is the leading cause of mortality, with an incidence of >1,000,000 cases occurring worldwide annually. Invasive ductal carcinoma (IDC), also known as infiltrating ductal carcinoma, is the most common type of mammary carcinoma; 80% of all mammary carcinoma are invasive ductal carcinomas.

Invasive indicates that the cancer has invaded or spread to the surrounding breast tissues and ductal carcinoma refers to the cancer growing in a milk duct that has invaded the fibrous or fatty tissue of the breast outside of the duct.

New technologies that influence our mammography imaging practice

When performing Contrast Enhanced Dual Energy Mammography on a standard mammography system, the high-energy (HE) and low-energy (LE) images must be acquired successively, With the introduction of the MAMMOMAT Revelation, Siemens Healthineers has implemented its Titanium Contrast-Enhanced Mammography (TiCEM) CEDEM application. TiCEM aims at improving diagnostic accuracy in the detection and characterization of breast tumors, by incorporating functional information.

The clinical workflow for a TiCEM examination starts with the injection of the iodinated contrast agent by means of a power injector. At the time of injection, the breast is not (yet) compressed, to allow for normal tissue perfusion and unhindered inflow of the contrast agent into the breast. The dosage of the contrast agent is typically weight-dependent and varies between institutions. After a waiting time of approximately 2 minutes, the woman is positioned at the MAMMOMAT Revelation and the breast is compressed. Then, a low-energy (LE) and a high-energy (HE) image are acquired successively and an Insight CEM image, a recombined image of that view is calculated. These steps are then repeated for each additional view, without the need to perform a new contrast agent injection. The time window for performing multiple views with a single contrast agent injection lasts up to 10 minutes, although the views should be acquired without any unnecessary delays. The order in which the views are acquired seems to be of little clinical significance and does not appear to affect image quality. Care should be taken when handling the contrast agent to avoid contamination of the detector or the skin with pure contrast agent, as this might mimic calcifications or result in artifacts.

In breast care, Tomosynthesis technology – also known as three-dimensional (3D) mammography revolutionizes diagnostic mammography. Tomosynthesis technology is slated to soon take over full field digital mammography (FFDM) by means of improved diagnostics, better image quality, reduced recall rates, workflow etc. Tomosynthesis technology creates an impact in almost every aspect of breast imaging from diagnostic breast cancer screening to interventions. It helps us to reduce the recall rate and false positive rates, irrespective of a women's age or breast density.

TiCEM with 50° wide-angle HD helps to change clinical management from surgery to therapy in IDC

Clinical findings

The patient is a 55-year-old female patient with a known history of carcinoma. The mediolateral oblique (MLO) standard mammographic views delineate the IDC from the previous examination. The initial plan was to do a conservative surgery. Further imaging with CEDEM prospective assessment revealed multiple non-palpable small nodules and enhancement in high energy contrast imaging. Late enhancement images outlined the axillary masses with adjacent lymph nodes. IDC was confirmed by the biopsy and other advanced imaging techniques which led to the decision of other clinical management in place of the surgical plan.

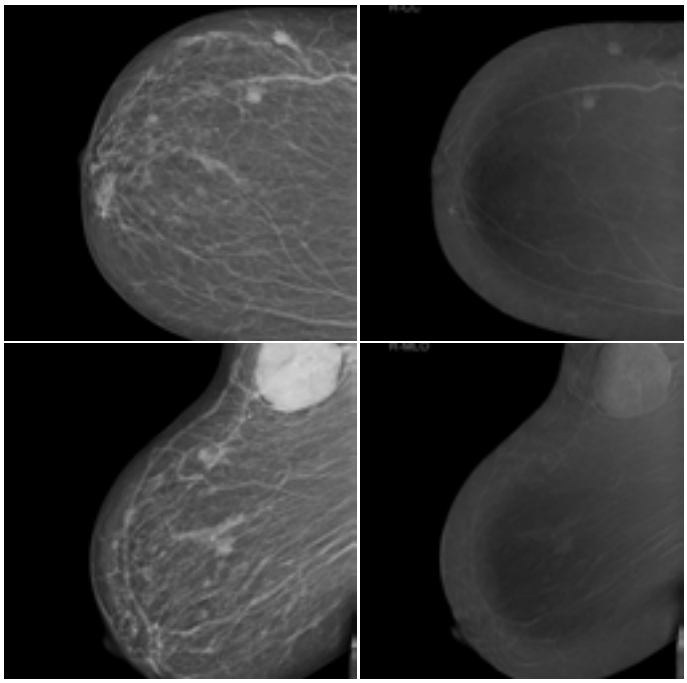

Conclusion

Siemens Healthineers pioneered the 50° wide-angle HD Breast Tomosynthesis, reaching the highest depth resolution on the market (3.5 times higher depth resolution compared to narrow angle systems) and Titanium Contrast Enhanced Mammography (TiCEM) with its unique HE spectrum and an optimized titanium filter, which reduces X-ray tube load to enable seamless examinations. TiCEM delivers additional diagnostic information for more confident decision-making and helps to detect or rule out lesions. Being an integrated functionality of the Siemens Healthineers MAMMOMAT Revelation, TiCEM can help reduce scheduling conflicts and workload on other modalities making it a cost-effective alternative to breast MRI. Finally, guidelines are needed to achieve international standards in acquisition techniques and image interpretation.

Reference

1. Perry N, Broeders MJM, de Wolf C, Törnberg S, Holland R, von Karsa L (2008) European guidelines for quality assurance in breast cancer screening and diagnosis. Fourth edition — summary document. Annals of oncology, official journal of the European Society for Medical Oncology / ESMO 19(4):614–22. 2. 2.
2. Skaane P, Bandos AI, Gullien R, Eben EB, Ekseth U, Haakenaasen U et al. (2013) Comparison of digital mammography alone and digital mammography plus tomosynthesis in a population-based screening program. Radiology 267(1):47–56.
3. Friedewald SM, Rafferty EA, Rose SL, Durand MA, Plecha DM, Greenberg JS et al. (2014) Breast cancer screening using tomosynthesis in combination with digital mammography. JAMA 311(24):2499–507.
4. Lång K, Andersson I, Rosso A, Tingberg A, Timberg P, Zackrisson S (2016) Performance of one-view breast tomosynthesis as a stand-alone breast cancer screening modality: results from the Malmo Breast Tomosynthesis Screening Trial, a population-based study. European radiology 26(1):184–90.
5. Bae KT (2010) Intravenous contrast medium administration and scan timing at CT: considerations and approaches. Radiology 256(1):32–61.
6. Strijkers GJ, Mulder WJM, van Tilborg GAF, Nicolay K (2007) MRI contrast agents: current status and future perspectives. Anti-cancer agents in medicinal chemistry 7(3):291–305.
7. Calliada F, Campani R, Bottinelli O, Bozzini A, Sommaruga MG (1998) Ultrasound contrast agents: basic principles. European journal of radiology 27 Suppl 2: S157-60
8. Tofts PS, Brix G, Buckley DL, Evelhoch JL, Henderson E, Knopp MV et al. (1999) Estimating kinetic parameters from dynamic contrast-enhanced T (1)-weighted MRI of a diffusable tracer: standardized quantities and symbols. Journal of magnetic resonance imaging JMRI 10(3):223–32.
9. Parker GJM, Buckley DL (2005) Tracer Kinetic Modelling for T1-Weighted DCE-MRI. In: Jackson A, Buckley DL, Parker GJM (eds) Dynamic ContrastEnhanced Magnetic Resonance Imaging in Oncology. Springer-Verlag Berlin Heidelberg. Berlin Heidelberg, pp 81–92.

Prof. Dr. Iman Abou El Hamd
Prof. Dr. Nagham Nabil
Prof. Dr. Gehan Sayed

Prof. Dr. Mostafa Hashem
Head of Radiology Dept., Women's Health Unit,
Assiut University Hospitals, Assiut University,
Assiut, Egypt

PEPconnect & PEPconnections

Your smarter connection to knowledge in digitalizing healthcare

Standardization of care is high on the agenda of clinical institutions. It is viewed to help achieve excellent clinical results, increase safety, and reduce costs. Have you ever considered education as one lever to realize this goal?

The know-how and skill level of staff members affects their performance. Continuous education and training can enhance their confidence as well as consistency.

PEPconnect is our personalized online education experience designed for healthcare professionals that's customized to their role and learning behavior – designed to increase their competency, efficiency, and productivity.

PEPconnections[1] is a PEPconnect premium subscription, which supports your clinical institution's performance growth with integrated workforce education management and administration features.

PEPconnect

Personalized education experience for the individual

PEPconnections

Customized workforce education management for the institution

[1] *Subscription required. Availability of subscription depends on country.*

SIEMENS Healthineers

Holistically manage your staff's education

PEPconnect

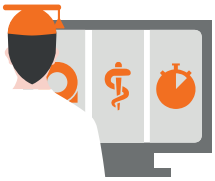

My Education Space
Discover the broad portfolio of technical, clinical and operational education

My Plan
Create your individual learning plan with self-selected learning activities based on your role and interests



My Activity Feed
View and access your personalized activity feed

My Groups
Engage in social learning and connect with others

My Transcript
Record the completion and certificates of your learning activities



Virtual Wallet
Purchase points to spend on additional subscriptions,virtual education options, or Continuing Education Credits (CECs)[2]

PEPconnections

Workforce Management & Administration
Assign, track, and manage the education of entire groups

Group Learning Plans
Customize your workforce education and create learning plans specific to your staffs' roles and needs

Virtual Library
Add your own or third party content for group access or assignment in Group Learning Plans

Dashboard & Reporting
Access reports and dashboards on group and individual employee activity progress

PEPconnect and PEPconnections
your complete virtual education experience

[2] *Additional content subscriptions available for PEPconnections users based on country availability. Subscription can be acquired via virtual wallet points placed in contract, available in specific countries.*

The products/features and/or service offerings (here mentioned) are not commercially available in all countries and/or for all modalities. If the services are not marketed in countries due to regulatory or other reasons, the service offering cannot be guaranteed. Please contact your local Siemens Healthineers organization for further details.

Multimodal MRI for Presurgical Language Mapping in Arabic

Collaboration between Cleveland Clinic Abu Dhabi and New York University Abu Dhabi
Osama Abdullah, Liina Pylkkanen and Florian Roser on behalf of the caregiver teams at Cleveland Clinic Abu Dhabi and New York University Abu Dhabi

A critical component of many brain surgeries is mapping the cortical regions that are essential for language in order to maximally preserve these regions during surgery. However, pre-surgical language mapping tests are not available for many of the world's languages, including Arabic as spoken in the UAE. Consequently, Arabic-speaking patients may be tested in a language that is not their native language or not tested at all. This can compromise the ability to localize core language areas, which may consequently lead to language deficits after surgery, especially in patients with tumors or epileptic foci near language cortex.

This work takes advantage of the advanced multi-modal neuroimaging and language expertise at New York University Abu Dhabi (NYUAD) to address both the need for basic neurobiological research on Arabic and the need for an Arabic language pre-surgical mapping protocol. The NYUAD team is collaborating with Cleveland Clinic Abu Dhabi (CCAD) to develop an Arabic mapping protocol based on a well-established protocol in English (Black et al., 2017, Am J Neuroradiol).

An effective language mapping protocol must cover all stages of language processing. In broad terms, for comprehension, this involves the perception of speech sounds or orthography, the mapping of word forms onto word meanings and the construction of complex syntactic and semantic representations. Production, in contrast, involves the construction of a message to be conveyed, mapping of that message to a syntactic structure, identification of the relevant lexical material, activation of the sound representations of those words, and finally motor planning of articulation.

In conclusion, utilizing advanced multi-modal MRI techniques including advanced structural segmentations, Arabic language mapping with fMRI, and diffusion tractography provide valuable tools for presurgical mapping of specialized cortical areas of language, which reduces intraoperative time to identify language centers in Arabic-speaking patients. On the other hand, the use of intraoperative direct electrical stimulation helps in validating the "correlative" data provided by fMRI-based language mapping, which can be helpful in the cases of tumor resections in fully anesthetized patients.

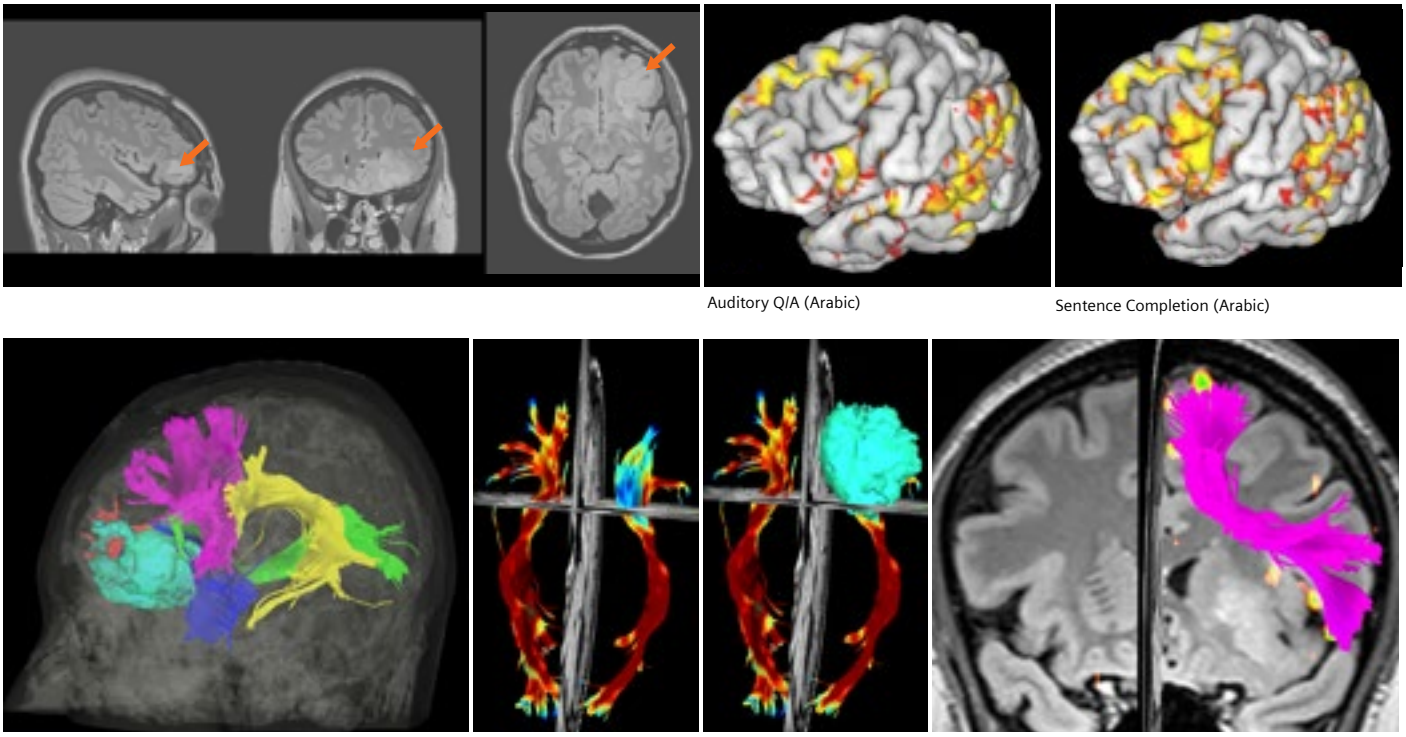

1 **Fig 1**: T2-FLAIR images of a patient with low grade glioma in the orbitofrontal area (white arrows). This patient performed 7 functional (fMRI) tasks in Arabic, only 2 tasks are shown (auditory questions, and a visual sentence completion task). The hot colors denote activations in the main language areas such as the pars triangularis/orbitalis, the posterior superior temporal gyrus, and dorsal and ventral premotor cortexes. Fiber tractography was also used to map the structural connectome and identify the white matter bundles that are critical for language. Shown in Fig. 1 fiber tractography overlaid on the tumor model (light blue), the arcuate fasciculus (yellow), the inferior fronto-occipital fasciculus (green), and the frontal aslant tract (purple).

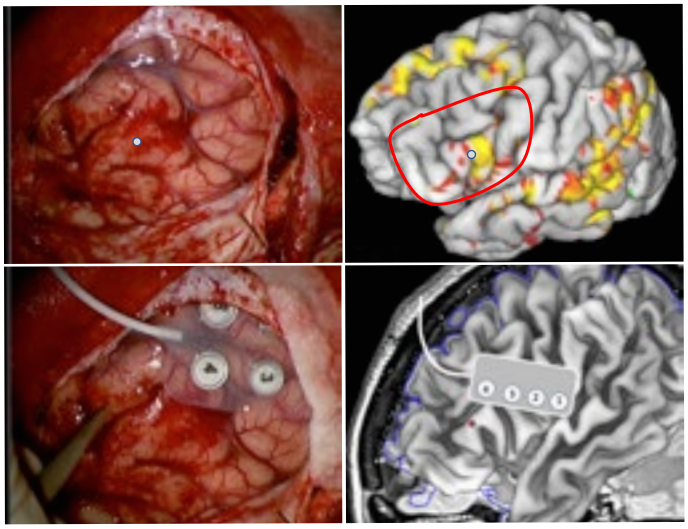

2 **Fig 2**: This patient went for an awake tumor resection surgery. The craniotomy location and corresponding contours (red trace) on the brain surface. Intraoperative electrical stimulation was performed to identify the eloquent language areas in close proximity to the tumor. Initially, a monopolar electrode was used to deliver electrical current intraoperatively during awake language tasks which caused speech arrest in the same locations that were identified from the Arabic fMRI (white and red dots on the pars triangularis area). During resection, continuous monopolar stimulation was used in the depth of the tumor to recognize subcortical connectivity of different language areas.

Caregiver team at CCAD

The Neuroscience of Language Lab at NYU

Osama Abdullah
New York University Abu Dhabi and
Cleveland Clinic Abu Dhabi

Cardiac CT Imaging of Irregular Heart Rhythms – Case Discussion with Dual Source CT Techniques

Ferdowsi Hospital, Tehran, Iran
Abbas Arjmand Shabestari, Associate Professor of Radiology, Shahid Beheshti University of Medical Sciences
Navid Sarmast Alizadeh, M.Sc. of Medical Imaging, Senior CT Clinical Specialist
Hossein Ali Sokhandan, Phd, Radiology Manager

Introduction

When imaging the heart, arrhythmia (any disturbance of the normal rhythmic beating of the heart or myocardial contraction) might be a nightmare for the acquisition of clinically optimal images. Over the past years, the resultant motion artifacts in those patients with arrhythmia produced sub-optimal imaging. Nevertheless, given the recent advancements in CT technologies, these challenges could be overcome using advanced CT scanner technical capabilities such as Native Temporal Resolution. Temporal resolution - the time required to capture every single image, can be considered as the speed of a camera taking a snapshot from a moving object. The 'native spatial resolution' which can be achieved by the scanner without using special modes such as multi-segment reconstruction or motion correction software techniques play a major role in imaging such patient groups.

New technologies that affect cardiac CT imaging practice in arrhythmic patients

Native Temporal Resolution

Sub-second Scanning - Rotation Speed

In CT imaging, the high image acquisition speed leads to decreased motion artifact and reduced radiation exposure. One of the key features of the scanners is the fast gantry rotation, implying better temporal resolution to reduce motion artifact and patient's radiation dose. High temporal resolution and selection of the least moving phase of the cardiac cycle for image reconstruction are essential for obtaining coronary CT angiographic images that are free from cardiac motion artefacts with our SOMATOM Force CT Scanner with sub-second rotation time of 250 mSec, one may achieve in plane temporal resolution of up to 66 ms (and down to 33 mSec using 2-segment reconstruction), which can be regarded as one independent of the heart rate.

All patients were scanned on a SOMATOM Force Dual Source CT scanner with the adaptive prospective CorAdSeq mode. Prospective ECG-triggered sequence (CorAdSeq) protocol in the DSCT helps to obtain high quality images and leads to a desirable diagnostic performance. Furthermore, it results in a reduced radiation dose. Adaptive sequence axial mode will omit or repeat scan when ectopic beat is detected, further editing the ECG Phase reconstruction, using either relative (%) or absolute (mSec) time parameters of R-R interval on concurrently obtained ECG data. Automatic exposure control system-based tube current modulation (CARE Dose4D, Care kV and flex padding, and ADMIRE) are applied to further reduce the patient's radiation dose. CARE Dose4D automatically adjusts the mA and CARE kV automatically selects the optimal kV for the patient's body size. The aim of applying CARE kV is to optimize contrast-to-noise ratio (CNR) and dose.

Artificial Intelligence in Cardiac Imaging

Artificial Intelligence (AI) - based arrythmia correction – FAST Cardio Algorithms (Fully assisted scanner technologies) continually monitor the patient's heartbeat and suggest the right protocol according to the heart rate. During the scan, the arrhythmia detection and scan rejection algorithms can hold the scan upon encountering an arrhythmia and restart the scan when the arrhythmia ends, allowing the precise capture of the desired cardiac cycle phase. FAST Planning adapts the scan range to your patient's anatomy automatically, reducing over scanning and increasing consistency. FAST 3D Align: adapts the reconstruction range to your patient's anatomy without any manual interference.

Study discussion – Clinical proof 1

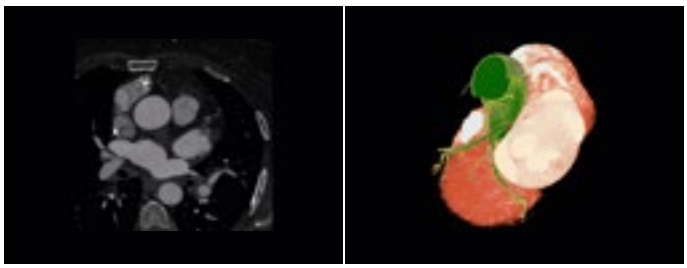

Case presentation

84-year-old female patient with a permanent cardiac pacemaker. Heart rate variation range during scan:102 bpm,113 bpm, 88 bpm, 80 bpm,110 bpm,132 bpm and 120 bpm. Image quality score: 5 out of 5 points.

The coronary CT angiogram was performed with the SOMATOM Force 70 kV auto mA CARE Dose4D protocol and post processed using *syngo*.via.

Coronary Artery Disease Assessment Conclusion: CAD-RADS 4-A/S

Non-Stented Coronary Artery Stenosis: Severe

Stenosis Stent: Minimal

In-stent restenosis Coronary Artery Stenosis Distal to Stent: None

kV - 70, ref mAs 400 , Total DLP: 388mGy*cm

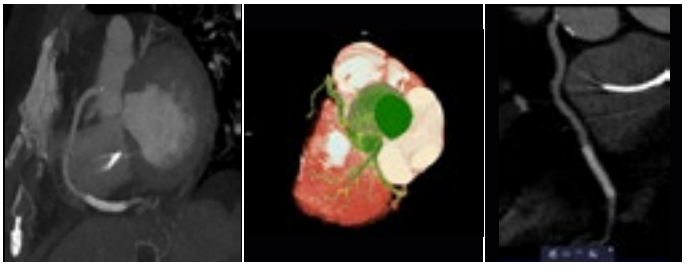

Study discussion – Clinical proof 2

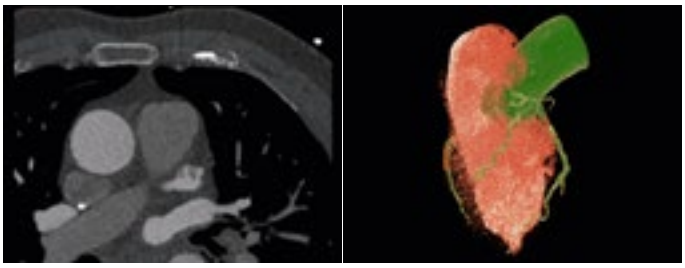

Case presentation

78-year-old male patient. Heart rate variation range during scan: 57 bpm, 92 bpm, 49 bpm, 56 bpm, and 95 bpm
Image quality score: 5 out of 5 points
The coronary CT angiogram was performed with the SOMATOM Force 70 kV auto mA CARE Dose4D protocol and post processed using *syngo*.via.

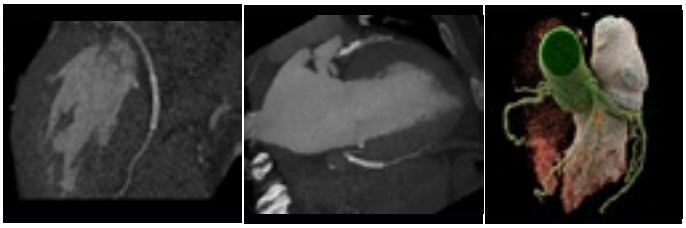

Coronary Artery Disease Assessment Conclusion: CAD-RADS 4A/S

Non-stented Coronary Artery Stenosis: Up to severe

Stenosis of LAD artery Stents: Patent 2nd diagonal artery stent and Patent PDA stent

kV - 70, ref mAs 400 , Total DLP: 388mGy*cm

Study discussion – Clinical proof 3

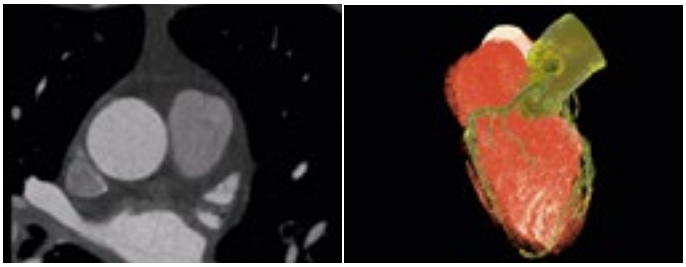

Case presentation

74-year-old male patient. Heart rate variation range during scan: 76 bpm to 80 bpm
Image quality score: 5 out of 5 points

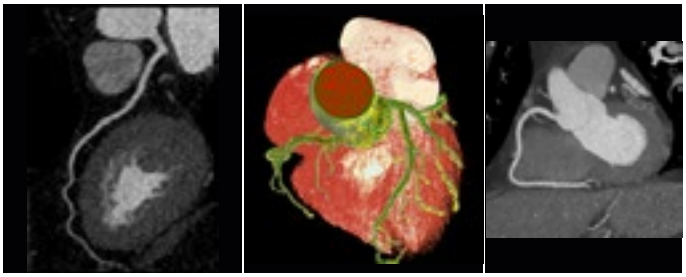

The coronary CT angiogram was performed with the SOMATOM Force 70 kV auto mA CARE Dose4D protocol and post processed using *syngo.via*.

Coronary Artery Disease Assessment Conclusion: CAD-RADS 0

Coronary Stenosis: None

Interpretation: Absent CAD

kV - 70, ref mAs 400 , Total DLP: 388mGy*cm

Discussion

Husmann et al[5] performed a detailed analysis of the motion of each of the main coronary arteries throughout the cardiac cycle and determined how it varied with patient's heart rate. At a heart rate of 60 bpm, the velocity of the right coronary artery varied from 10 mm per second to 65 mm per second over the cardiac cycle.

A high native temporal resolution in conjunction with ECG-synchronization to reconstruct the images in an optimal phase of the cardiac cycle is essential for the sharp depiction of the coronary arteries with minimum blurring from cardiac motion. This requirement is particularly of paramount importance in patients with high and variable heart rates.

A good intrinsic temporal resolution, together with selection of the optimal cardiac phase, is currently regarded as the most robust method for eliminating coronary artery motion artefacts in arrhythmic patients.

Reference

1. Hameed TA, Teague SD, Vembar M. LOW radiation dose ECG-gated chest CT angiographyon a 256 slice multidetector CT scanner. Int J Cardiovasc Imaging. 2009;25:267–278.
2. Hein PA, Romano VC, Lembcke A. Initial experience with a chest pain protocol using 320 slice volume MDCT. Eur Radiol. 2009;19:1148–1155. [PubMed]
3. Gallagher MJ, Raff GL. Use of mutislice CT for the evaluation of emergency room patients with chest pain: the so-called triple rule-out. Catheter Cardiovasc interv. 2008;71:92–99. [PubMed]
4. Haidary A, Bis K, Vrachliotis T, Kosuri R, Balasubramaniam M. Enhancement performance of a 64-slice triple rule-out protocol vs 16-slice and 10-slice multidetector Ctangiography protocols for evaluation of aortic and pulmonary vasculature. J Comput Assist Tomogr. 2007;31:917–923. [PubMed]
5. European Study Group. European guidelines on quality criteria for computed tomography: EUR16262.
6. Lee CH, Goo JM, Ye HJ, Ye SJ, Park CM, Chun EJ, Im JG. Radiation dose modulation techniques in the multidetector CT era: from basics to practice. Radiographics. 2008;28:1451–1459. [PubMed]
7. Bischoff B, Meinel FG, Del Prete A, Reiser MF, Becker HC. High-pitch coronary CT angiography in dual-source CT during free breathing vs breath holding in patients with low heart rates. Eur J Radiol. 2013;82:2217–2221. [PubMed]
8. Beister M, Kolditz D, Kalender WA. Iterative reconstruction methods in X-ray CT. Phys Med 2012;28(2):94–108. 2. Gordic S, Morsbach F, Schmidt B, et al. Ultralow-dose chest computed tomography for pulmonary nodule detection: first performance evaluation of single energy scanning with spectral shaping. Invest Radiol 2014;49(7):465–473.
   3. Goodenough DJ, Weaver KE. Factors related to low contrast resolution in CT scanners. Comput Radiol 1984;8(5):297–308
9. Arrhythmia: a disturbance of the normal cardiac rhythm (faster, slower or irregular) (British Heart Foundation, 2012).
10. A meta-analysis has shown that the high intrinsic temporal resolution of the Siemens Healthineers Dual Source CT scanner makes it suitable for ruling out CAD in patients with atrial fibrillation (Sun G et al, 2013)

Abbas Arjmand Shabestari
Associate Professor of Radiology,
Shahid Beheshti University of Medical Sciences,
Ferdowsi Hospital, Tehran, Iran

Navid Sarmast Alizadeh
M.Sc. of Medical Imaging, Senior CT Clinical Specialist
Ferdowsi Hospital

Siemens Healthineers Academy

Shaping medical education and training programs for healthcare professionals.

Click or Scan the QR Code to explore our course offerings

To keep medical professionals better informed of the continuously changing environment of medical science, Siemens Healthineers launched the Siemens Healthineers Academy offering educational training in a wide range of disciplines.

Our goal is to provide education and training resources that can help address on-going clinical challenges and skills needed for future pursuits. Our training programs are designed to assist healthcare professionals in ensuring improved patient care to the highest, international standards. Siemens Healthineers Academy leads the way in healthcare education, offering CPD/CME accredited courses for Radiologists, clinicians, technologists and biomedical engineers, together with global and local hospitals and academic institutions. Healthcare professionals can benefit from the professional knowledge of experienced physicians and technologists, education specialists and clinical partners.

For more information, contact:

Maxine Haechler
maxine.muir@siemens-healthineers.com
healthineers.academy.ae@siemens-healthineers.com

SIEMENS Healthineers

Editorial Board

Middle East Regional Office
Siemens Healthcare LLC
Building 40,
Dubai Healthcare City
United Arab Emirates
Tel: +971 4 366 0700